

Effect of Aqueous Extract of Moringa Oleifera Seed on Haematological Parameters and the Spleen in Male Albino Rats

Dike Ebere Charles¹, and Luteino Lorna Hamman²

Department of Human Anatomy, College of Medical Sciences, University of Maiduguri, Nigeria

Abstract: *The effects of oral administration of the aqueous extract of Moringa oleifera seed at 400, 800 and 1600 mg/kg was investigated in 25 male Wistar rats after 28 days of treatment and 2 weeks withdrawal of group four after the 28 days. Treatment with the extract did not significantly ($P > 0.05$) alter the levels of haemoglobin, red blood cell, packed cell volume, mean corpuscular volume and mean corpuscular haemoglobin concentration. The extract however induced significant decrease ($P < 0.05$) in the concentrations of platelets and total white blood at 1600 mg/kg. Moringa oleifera seed extract induced histological lesion on the spleen of the rats treated with 800mg/kg and 1600mg/kg and the withdrawal group showed recovery in both platelet, WBC and in histopathology of spleen. The data from this experiment may be a guideline for establishing the appropriate dose range of Moringa oleifera seed extract on further development of safety herbal products.*

Keywords: *Moringa oleifera seed, rats, hematological, spleen.*

I. Introduction

Herbal medicine is still the mainstay in the developing countries for primary health care. This is primarily because of the general belief that herbal drugs are without any side effects, besides being cheap and locally available (Achinewu and Aniena, 1995). The use of plants for healing purposes predates human history and forms the origin of modern medicine. Focus on plant research has increased in recent times all over the world and results have shown an immense potential of some plants in various traditional water purification system (Amaglah and Benang, 2009).

Plants have played a significant role in maintaining human health and improving the quality of human life for thousands of years and have served humans well as valuable components of medicines, seasonings, beverages, cosmetics and dyes (Agaie, 2004). Herbal medicine is based on the premise that plants contain natural substances that can promote health and alleviate illness (Newman et al., 2000). Recent years have witnessed a renewed interest in plants as pharmaceuticals in the Western world. It has been estimated that 80% of the people living in developing countries are almost completely dependent on traditional medical practice for their primary health care needs and higher plants are known to be main sources of drug therapy in traditional medicine. Since about 80% of the world's population reside in developing countries, about 64% of the world's population (3.84 billion people) utilize plants as drugs. Despite all these, the use of herbal medicine should be taken with care because of raw materials present in these plants. This interest is channeled into the discovery of new biologically-active molecules by the Pharmaceutical industry and into the adoption of crude extracts of plants for self-medication by the general public. One such plant, Moringa oleifera, (Family: Moringaceae) is a multipurpose tree, used as vegetable, spice, a source of cooking and cosmetic oil and as a medicinal plant (Fuglie, 1999; Fahey, 2005). Moringa oleifera is one of the leading names recently in plants and drug research. A large number of reports on the nutritional qualities of Moringa oleifera now exist in both the scientific and the popular literature. Moringa oleifera is a highly valued plant, distributed in many countries of the tropics and subtropics, commonly known as Drumstick tree, indigenous to Northwest India. In Nigeria, it is locally known as; Gawara, Konamarada, Kini maka (Fulani); Zogall, Zogalle-gandi, Bagaruwar (Hausa); Ikwe oyibo (Igbo); Ewe ile, Ewe igbale (Yoruba), gargeddi (Igala) and allam (Kanuri). It is a perennial softwood tree with timber of low quality, but which for centuries has been advocated for traditional medicinal and industrial uses. Moringa tree can grow well in the humid tropic or hot dry land; it can survive in harsh climatic condition including destitute soil without being much affected by drought (Morton, 1991). Moringa oleifera is the best known of the thirteen species in the genus Moringa of family Moringaceae. These are Moringa oleifera, M. arborea, M. borziana, M. concanensis, M. drouhardii, M. hildebrandtii, M. longituba, M. ovalifolia, M. peregrine, M. pygmaea, M. rivae, M. ruspoliana and M. stenopetala (Mahmood et al., 2010).

Most of the parts of the plant possess antimicrobial activity (Bhavasara et al., 1965; Caceres et al., 1992). They are well known for their pharmacological actions. Nearly every part of this plant, including root, bark, gum, leaf, fruit (pods), flowers, seed, and seed oil have been used for various ailments in the indigenous medicine (Odebisi and Sofowora, 1999).

Different parts of this plant contain a profile of important minerals, and are a good source of protein, vitamins, β -carotene, amino acids and various phenolics. The Moringa plant provides a rich and rare

combination of zeatin, quercetin, β - sitosterol, caffeoylquinic acid and kaempferol. In addition to its compelling water purifying powers and high nutritional value, *Moringa oleifera* is very important for its medicinal value. Various parts of this plant such as the leaves, roots, seed, bark, fruit, flowers and immature pods act as cardiac and circulatory stimulants, possess antitumor, antipyretic, antiepileptic, antiinflammatory, antiulcer, antispasmodic, diuretic, antihypertensive, cholesterol lowering, antioxidant, antidiabetic, hepatoprotective, antibacterial and antifungal activities, and are being employed for the treatment of different ailments in the indigenous system of medicine, particularly in South Asian (Guevara et al., 1999).

Moringa oleifera seeds are large and circular-shaped, and grow inside the lengthy pods. *Moringa oleifera* seed pods can reach well over a foot in length and each pod can provide over a dozen of large seeds. The seeds have two sets of thin flaps extending from the main kernel of the seeds. These flaps serve as wings to carry the seed away from the mother tree, and with the help of the wind, they move across the ground until they find a resting place to germinate. Unlike the fast-growing leaves of the *Moringa oleifera* tree, the seed pods do not grow back in a few months; it produces seed pods on an annual basis, much like other similar species in the plant kingdom.

Moringa oleifera tree gives off incredible volume of seed pods during their reproduction months. An average-sized *Moringa oleifera* tree can produce hundreds or even thousands of seed pods every year (Bennett et al., 2003)

Several biological activities have been reported in the plant *Moringa Oleifera* including biological coagulation in drinking water by its seed (Jahn, 1988; Oluduro and Aderiye, 2009). However, there remains considerable concern over the toxic effect of *Moringa oleifera* seed extract in treated drinking water on villagers since the report of Olayemi and Alabi (1994), suggesting apathy to continue use of the plant for water purification purposes.

II. Materials And Methods

2.0 Materials

The following materials were used during the course of the study; rat cages, drinkers, triple beam balance, distilled water, Hawksly microcapillary tube, dissecting sets, hand gloves, light microscope, measuring cylinder, haemocytometer, calorimeter, microhaematocrit centrifuge, syringe, orogastric tube, razor blade, pins, dissecting board, specimen bottle, glass slides, pipette, hot plate, Hawksly heamatocrit reader, Moulinex domestic food blender, cover slips, EDTA sample bottle, oven, paraffin, haematoxylin and eosin.

2.1 Plant collection and authentication

Dried seeds of *Moringa oleifera* were obtained from Biu local government area of Borno State Nigeria. The plant (seeds) was authenticated by Professor S. S. Sanusi, a plant Taxonomist in the Department of Biological Sciences, University of Maiduguri.

2.2 Preparation of plant extract

The seed wings and coat from selected good quality *Moringa oleifera* seeds were removed and the kernel collected. The seeds were dried under room temperature (25⁰C) in the department of Human Anatomy for five days. The seeds were then blended to fine powder using coffee mill attachment of Moulinex domestic food blender. Before blending, the seed weighed 967.6g and after blending, it weighed 659.2g. This quantity (659.2g) was soaked in 4 liters of distilled water at ambient temperature for three days and filtered; the bulked filtrate was evaporated using hot air oven at 63⁰C for a period of 24 hours. The powder obtained was stored at room temperature until when needed. The aqueous solution was then prepared by dissolving the finely pulverized powder of *Moringa oleifera* seed in distilled water in the ratio of 10g to 50ml and stirred for two minutes before intubation. The stock solution was prepared fresh for use as and when needed, since deterioration sets in if stored for more than two days at room temperature. 280g of the extract was utilized during the experiment.

2.3 Experimental animals

This study was carried out in the animal house unit of research laboratory of the Department of Human Anatomy University of Maiduguri between April and May 2013. A total of twenty five (25) male albino rats weighing between 120g to 210g were obtained from National Research Institute Vom, Plateau State. Following acclimatization period of two weeks, the rats were individually identified by colour tattoo and weighed. The rats were kept in plastic cage at room temperature with twelve hours nigh/dark cycle. They had access to their feed and a hygienic environment maintained to prevent infection. The rats were weighed using a triple beam balance at commencement of the experiments and weekly throughout the duration of the experiment.

2.4 Experimental design

A total of twenty-five (25) male albino rats were weighed and randomly divided into five groups of five rats per group (I–V). Group I serves as control and were administered distil water and feeds only. Group II–V was used as the experimental groups and were administered orally calculated doses of seed extract of Moringa oleifera seed daily. Group II (low dose), group III (medium dose), group VI (high dose) and group V (recovery group) were administered 400mg/kg, 800mg/kg, 1600mg/kg and 1600mg/kg of the seed extract respectively in addition to feeds and distil water for a period of twenty eight days. The withdrawal group (Group V) was sacrificed after fourteen days feeding with discontinued administration of the extract. The oro-gastric method of intubation was adapted for the administration of plant extract and was done in the morning hours before feeding the animals. The rats were intubated daily throughout the period of experiment (28 days).

2.5 Animal sacrifice and sample collection

Animals in group I – IV were sacrificed 24 hours after the last doses were administered to them. The recovery group (Group V) was sacrificed after fourteen days when extract administration was discontinued but water and feeding continued. The rats were, at the time of sacrifice, weighed and then anaesthetized by placing them in a closed jar containing cotton wool sucked with chloroform and sacrifice by cervical dislocation and blood was collected from jugular vein into EDTA sample bottle and the content thoroughly mixed by gentle rolling of the bottle for haematological analysis. The abdominal cavity was opened through a midline abdominal incision and the spleen was immediately removed, weighed and placed in fixative (10% formalin) and processed for histological study (Appendix). The blood parameters that were analyzed include; red blood cell (RBC) count, packed cell volume (PCV), haemoglobin (Hb) concentration, white blood cell (WBC) count, platelet count, red cell indices (mean corpuscular volume (MCV), mean corpuscular haemoglobin (MCH) and mean corpuscular haemoglobin concentration (MCHC).

2.6 Statistical analysis

Data collected were expressed as mean \pm S.D and analyzed using the instat software programme. One way analysis of variance (ANOVA) with Dunnette test was used to determine the level of significance of confidence of 95% (p value < 0.05 was considered significant). This was used to determine inter group differences. Comparison between treatment and control groups were made by Bonferroni test. Differences between groups were considered significant at $p < 0.05$.

III. Result

3.1 Physical Observation

The rats were observed to be weak immediately after intubation. The spleen was seen to have similar appearance, the shape and color in both the treatment rat and control rats are the same. The color of the spleen in both the treatment rat and control was pinkish.

3.2 Effect on Body Weight

Aqueous extract of Moringa oleifera seed had no effect on body weight gain (table 1) because all the animals both in control and administered groups including recovery group showed a significant increase in body weight ($p < 0.005$).

Table 1: Effects of aqueous extract of Moringa oleifera seed on the weight of male albino rats.

Parameters Groupings	Number of rats	Initial body weight (g)	Final body weight (g)	Mean difference (g)	Percentage differences (%)
Control	5	130.84 \pm 5.70	180.60 \pm 14.381*	49.76	15.97
400mg/kg	5	140.90 \pm 11.44	182.32 \pm 10.18*	42.32	13.13
800mg/kg	5	144.6 \pm 14.2	192.80 \pm 7.26*	48.20	14.29
1600mg/kg	5	144.74 \pm 13.11	191.30 \pm 8.42*	46.56	13.86
1600mg/kg (recovery)	5	139.00 \pm 8.97	205.80 \pm 2.17*	66.8	19.37

The values are expressed as mean \pm S.D, * $p < 0.005$ as compared between initial body weight and final body weight.

3.3 Haematological result

Table 2. Effects of aqueous extract of Moringa oleifera seed on haematological parameters of male albino rats.

PARAMETERS	CONTROL	GROUP I	GROUP II	GROUP III	RECOVERY
		400mg/kg	800mg/kg	1600mg/kg	1600mg/kg
	n=5	n=5	n=5	n=5	n=5
PCV (%)	43.8±2.49	40.60±2.30	42.00±1.00	42.00±0.71	42.60±1.14
Hb (g/dl)	15.60±0.55	15.06±0.26	14.68±0.71	14.80±0.45	15.10±0.37
RBC (x10 ⁶ /mm ³)	7.188±0.27	6.94±0.19	6.58±0.38	6.62±0.13	6.82±0.55
MCV (fL/red cell)	61.07±5.23	58.67±2.91	63.04±2.54	63.47±1.84	60.76±2.79
MCH (pg/red cell)	21.57±0.41	21.93±1.21	21.61±1.87	22.21±1.22	21.23±0.24
MCHC (g/dl red cell)	35.74±3.02	35.35±2.44	34.72±1.65	35.09±0.65	35.46±1.93
WBC (x10 ³ /mm ³)	8.41±0.47	8.23±0.20	7.98±0.031	7.78±0.48*	8.22±0.24
Platelet (x10 ³ /mm ³)	988.98±6.44	983.35±6.02	981.37±19.03	980.75±13.07*	987.28±6.12

The values are expressed as mean ±S.D, * p<0.005 as compared with control, n stands for number of rats. There was no significance difference (p>0.05) in red blood cell (RBC) count, haemoglobin (Hb) concentration, pack cell volume (PCV), mean corpuscular volume (MCV), mean corpuscular haemoglobin (MCH) and mean corpuscular haemoglobin concentration (MCHC) in the experimental rats when compare to the control group. Also there was no significance difference in white blood cell (WBC) count and platelet concentration in group II (400mg/kg), group III (800mg/kg) and group V (recovery) but there was significance difference (P<0.05) in WBC count and platelet concentration in group IV (1600mg/kg).

3.4 Histological effect

The administration of the extract showed degenerative changes in the substance of the spleen, section of spleen obtained from control and those administered with 400mg/kg (fig. 1 and 2) showed normal histology features of lymphoid nodules (white pulp) embedded in the matrix (red pulp). Sections of the rats spleen treated with 800mgkg⁻¹ and 1600mgkg⁻¹ aqueous extract of Moringa oleifera, showed mild and moderate expansion of white pulp (fig.3 and 4) respectively.

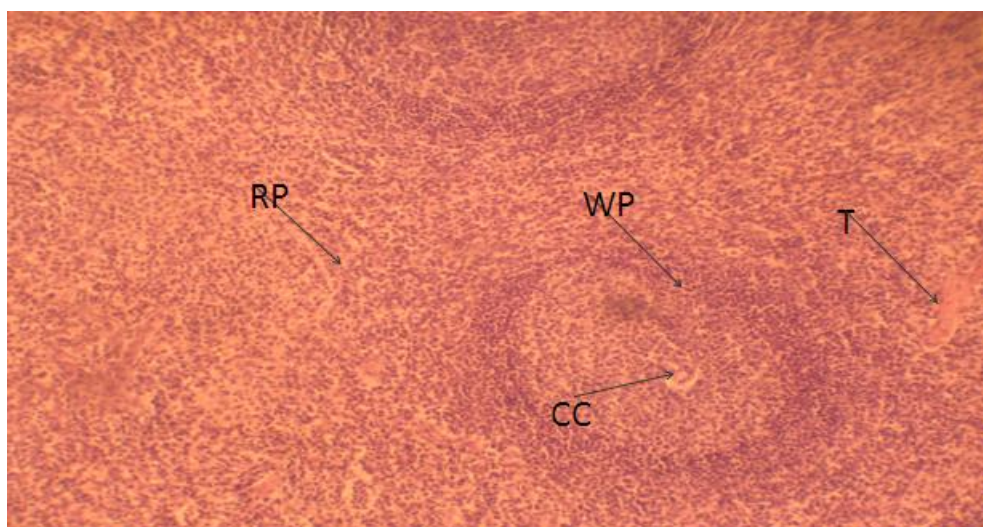


Fig 1. Photomicrograph of group I (control) rat spleen showing, red pulp (RP), white pulp (WP), central capillary channel (CC), trabecula (T) H & E stains x100.

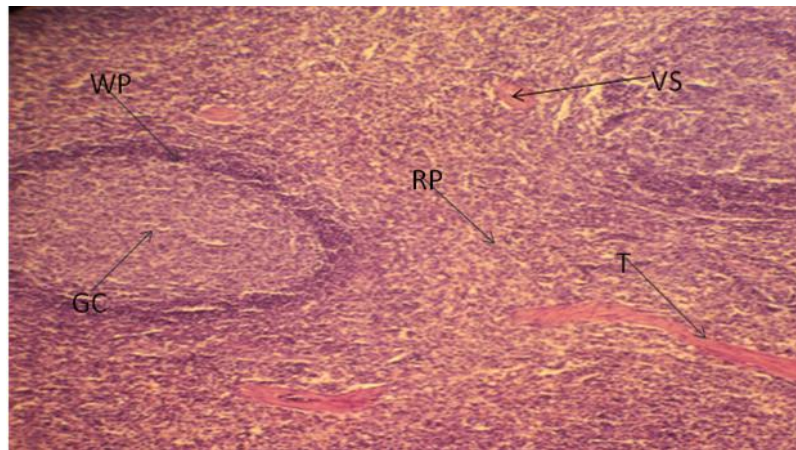


Fig. 2 Photomicrograph of rat spleen treated with 400mg/kg of aqueous extract of *Moringa oleifera* seed showing, red pulp (RP), white pulp (WP), trabeculae (T), germinal center and venous sinus (Vs) H & E stains x100

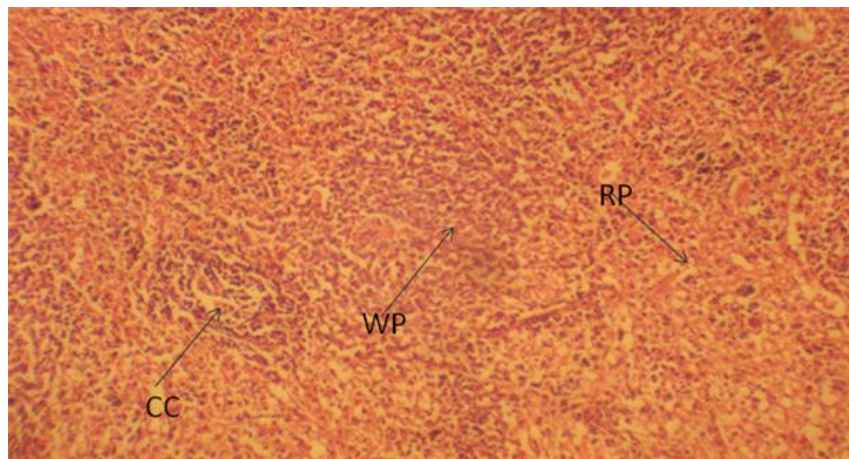


Fig. 3 Photomicrograph of rat spleen treated with 800mg/kg of aqueous extract of *Moringa oleifera* seed showing, red pulp (RP), central capillary channel and mild expansion of white pulp (WP) H & E stains x100.

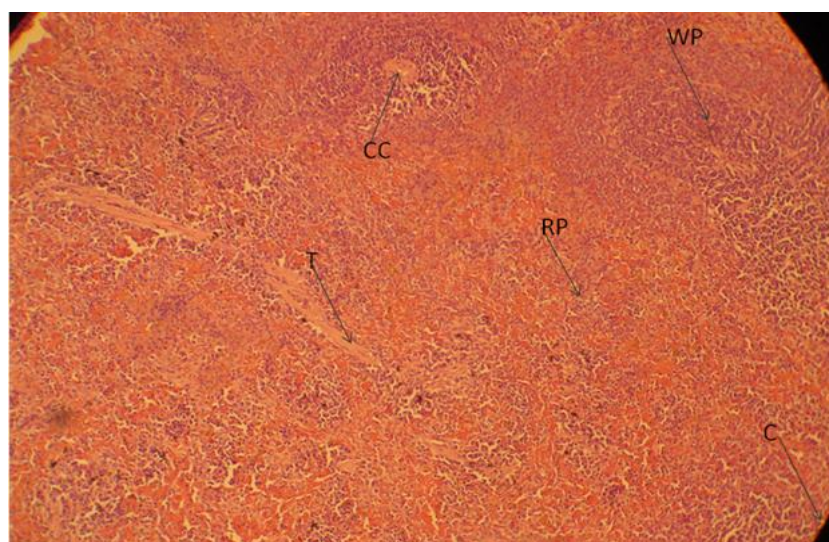


Fig. 4 Photomicrograph of rat spleen treated with 1600mg/kg of aqueous extract of *Moringa oleifera* seed showing, red pulp (RP), trabecula (T), central capillary channel (CC), capsule (C) and moderate expansion of white pulp (WP) H & E stains x100.

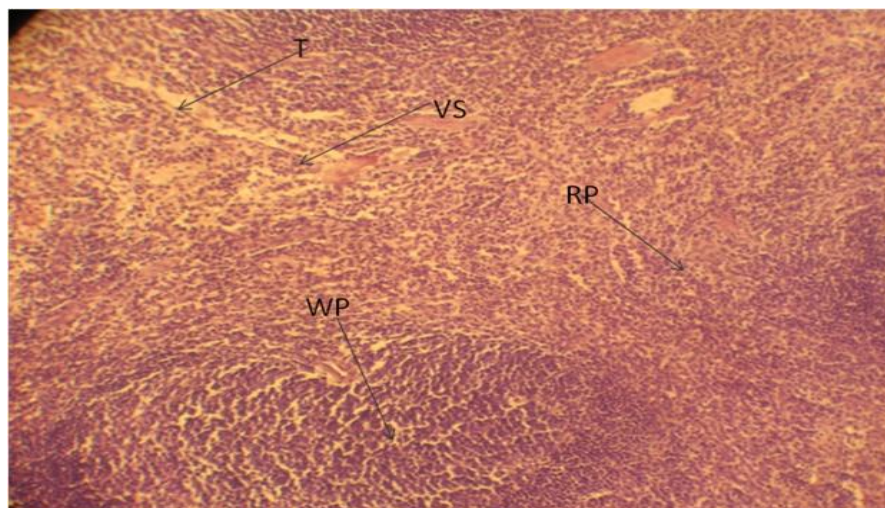


Fig. 5 Photomicrograph of rat spleen treated with 1600mg/kg of aqueous extract of *Moringa oleifera* and left to recover within 2 weeks showing, red pulp (RP), trabecula, venous sinus and white pulp (WP) H & E stains x100

IV. Discussion

Toxicity studies are usually undertaken to define the toxicity and effect of extract, assess the susceptible species, identify target organs, provide data for risk assessment in case of acute exposure to the chemical or drug, provide information for the design and selection of dose levels for prolonged studies (Wallace,2001).The toxicity of plants are mostly dependent on the plant organs which may be as a result of some factors such as the storage form of the organ and seasonal variation considering the phytochemicals (Jaouad,et al., 2004).

The oral administration of *Moringa oleifera* seed extract did not induce toxic changes in the RBC, Hb, PCV, MCV, MCH and MCHC of rats (table 2). The absence of significant changes on these indices suggest that the extract does not possess toxic substances that can cause an anemic condition in rats. This observation is in agreement with the report of Ajibade, et al., (2012) who also did not observe any toxic effect of *Moringa oleifera* seed extract in Wistar rats on these indices which contradict the report of Songpol, et al., which stated that *Moringa oleifera* seed extract has a significant decrease in RBC at high dose of 1000mg/kg. The significant decrease in the total WBCs at dose at 1600 mg/kg observed in this study contradicts the report of Swenson and Reece (1993), who reported that toxic plants do not produce a direct effect on WBC and its functional indices. This decrease in WBC can impair inflammatory process. The recovery group does not show any significant decrease, this implies that the reduction in WBC is not chronic and can return to normal after withdrawal of extract. This decrease in total WBCs counts might have resulted from the suppression of leucopoiesis in the bone marrow. The reductions observed in the platelet count may impair the repair of minute breaks in capillaries and other small vessels. Therefore, continued administration of the extract at high doses may result in widespread hemorrhages but can be avoided by withdrawal of extract as observed in the recovery. The mild and moderate expansion observed in those administered with 800mg/kg and 1600mg/kg can cause reduction in haemolytic function of the spleen.

V. Conclusion And Recommendation

The results of the present study suggest that aqueous extract of *Moringa oleifera* seed if consumed in high quantity affect the normal histological appearance of the spleen and has significant decrease in WBC count and platelet concentration. Therefore, it is advisable to people consuming *Moringa oleifera* seed to take it at low quantity.

References

- [1]. Achinewu, S. C. and Aniena M. I. (1995). Studies of spices of food value in the South Eastern states of Nigeria: *Journal of African medicinal plants*; 18:135-139.
- [2]. Agaie, B., (2004). The role of phytochemicals in optimal health. *Journal of the National Academy for Child Development*, 11(1): 27-29.
- [3]. Ajibade, T.O., Olayemi, F. and Arowolo, R.O.A. (2012).The haematological and biochemical effects of methanol extract of the seeds of *Moringa oleifera* in rats. *J Med Plant Res.* 6(4): 615-621.
- [4]. Amaglah, F.K. and Benannng, A. (2009). Effectiveness of *Moringa oleifera* seed as coagulant for water purification. *Afr. J. Agric. Res.* 4(1):119-123.

- [5]. Anhwange, B.A., Ajibola V.O. and Oniye, S.J. (2004). Chemical studies of the seeds of *Moringa oleifera* (Lam) and *Detarium microcarpum* (Guill and Sperr). *J. Biol. Sci.*, 4: 711-715.
- [6]. Anwar, F. and Bhangar, M.I. (2003). Analytical characterization of *Moringa oleifera* seed oil grown in temperate regions of Pakistan. *J Agric Food Chem* 51: 6558–6563.
- [7]. Anwar, F., Latif, S., Ashraf, M. and Gilani, A.W. (2007). *Moringa oleifera*: A food plant with multiple Medicinal Uses. *Phyther. Res* 21:17-25.
- [8]. Bennett, R.N., Mellon, F.A., Foidl, N., Pratt, J.H., Dupont, M.S., Perkins, L. and Kroon, P.A. (2003). Profiling glucosinolates and Phenolics in Vegetative and Reproductive tissues of the multi-purpose trees *Moringa oleifera* L. (Horseradish tree) and *Moringa stenpetala* L. *J. Agric. Food Chem.*, 51: 3546-3553.
- [9]. Bhavasar, G.C., Guru, L.V., Chadha, A.K. (1965). Antibacterial activity of some indigenous medicinal plants. *Medicine and Surgery*; 5:11–14.
- [10]. Caceres A., Saravia, A., Rizzo, S., Zabala, L., Leon, E.D. and Nave, F. (1992). Pharmacologic properties of *Moringa oleifera*, screening for antispasmodic, anti-inflammatory and diuretic activity. *J. of Ethnopharmacology*; 36(3):233-237.
- [11]. Chaurasia's B.D. (2010). Spleen, Pancreas and Liver in B. D. Chaurasia's Human Anatomy Regional and Applied Dissection and Clinical Volume 2, 5th edn CBS Publishers & Distributors New Delhi Pp. 301-305.
- [12]. Dahot, M.U. (1988). Vitamin contents of flowers and seeds of *Moringa oleifera*. *Pak J Biochem* 21: 1–24.
- [13]. Faiz, S., Siddiqui, B.S., Saleem, R., Aftab, K., Shaheen, F. and Gilani, A.H. (1998). Hypotensive constituents from the pods of *Moringa oleifera*. *Planta Med* 64: 225–228.
- [14]. Fahey, J.W. (2005). *Moringa oleifera*: A Review of the Medical Evidence for Its Nutritional, Therapeutic, and Prophylactic Properties. Part 1 <http://www.tfljournal.org/article.php/20051201124931586> accessed on 06/04/2012
- [15]. Fuglie, L.J. (1999). *The Miracle Tree: Moringa oleifera: Natural Nutrition for the Tropics*. Church World Service, Dakar. Pp 62, The Miracle Tree: The Multiple Attributes of Moringa, Pp 172. http://www.echotech.org/bookstore/advanced_search_result.php?keywords=Miracle+Tree. Accessed 09/04/2012.
- [16]. Gassenschmidt, U., Jany, K.D., Tauscher, B. and Niebergall, H. (1995) Isolation and characterization of a flocculating protein from *Moringa oleifera* Lam. *Biochimica Biophysica Acta* 1243: 477-481
- [17]. Goyal, B.R., Agrawal, B.B., Goyal, R.K. and Mehta A.A (2007). Phyto-pharmacology of *Moringa oleifera* Lam.6 An overview. *Nat Prod Radiance* 6(4): 347-353.
- [18]. Guevara, A.P., Vargas, C., Sakurai, H., Fujiwara, Y., Hashimoto, K., Maoka, T., Kozuka, M., Ito, Y., Tokuda, H. and Nishino, H. (1999). An antitumour promoter from *Moringa oleifera* Lam. *Mutat. Res.*, 440: 181-188.
- [19]. Gyton, A.C & Hall, J.E. (2006). Blood cells, immunity and Blood clotting in *Textbook Of Medical Physiology* 11th edn Elsevier Saunders Pennsylvania, pp. 419-428.
- [20]. Harold, E. (2006). Abdomen & Pelvis in *Clinical Anatomy Applied Anatomy For Students And Junior doctors* 11th edn Blackwell Publishing Ltd U.K Pp 104-105.
- [21]. Jahn, S.A.A. (1988). Monitored water coagulation with *Moringa oleifera* seeds in village household. *Journal of Analytical Science* 1: 40-41.
- [22]. Junqueira, L. C. and Carneiro J. (2005). *Lymphoid Organs In Basic Histology text & atlas* 11th edn McGraw-Hill companies U.S.A Pp 274-279.
- [23]. Kalogo, Y., Rosillon, F., Hammes, F. and Verstraete. W. (2000). Effect of aqueous extract of *Moringa oleifera* seeds on the hydrolytic microbial species diversity of a UASB reactor treating domestic wastewater. *Lett Appl Microbiol* 31: 259–264.
- [24]. Mahmood, K.T., Mugal, T. and Haq, I.U. (2010). *Moringa oleifera*: A natural gift-A review. *J. Phar. Sci. Res.*, 2: 775-781.
- [25]. Moore, K. L., Dally, A. F. and Agur, A. M. R. (2010). Abdomen in *Clinically Oriented Anatomy* 6th edn, Lippincott & Wilkins Publishers U.S.A Pp 263-264.
- [26]. Morton, J.F. (1991). The horseradish tree, *Moringa pterygosperma* (Moringaceae)- A boon to arid lands *Econ. Bot.* 45:318-333.
- [27]. Nath, D., Sethi, N., Singh, R.K. and Jain, A.K. (1992). Commonly used Indian abortifacient plants with special reference to their teratogenic effects in Rats. *J. Ethnopharmacol.*, 36: 147-154.
- [28]. Ndabigengesere, A., Narasiah, K.S, Talbot, B.E. (1995). Active agents and mechanism of coagulation of turbid waters using *Moringa oleifera*. *Water Res.*, 29(2): 703-710.
- [29]. Newman, D.J., Cragg, G.M. and Snader, K.M., (2000). The Influence of Natural Products upon Drug Discovery. *Natural Product Report*, 17: 215-234
- [30]. Odebiyi, A., Sofowora, E.A. (1999). Phytochemical screenings of Nigerian medicinal plants part 11. *Lyodia* 44:234-246. Peter, J. Houghton (1995). Discovery of new biological molecules. *The Journal of Alternative and Complementary Medicine*, 1(2): 131 143.
- [31]. Olsen, A. (1987). Low technology water purification by bentonite clay and *Moringa oleifera* seeds flocculation as performed in Sudanese village: Effects of *Schistosoma mansoni* cercariae. *Water Res.*, 21: 81-92.
- [32]. Oluduro, A.O. and Aderiye, B.I. (2009). Effect of *Moringa oleifera* seed extract on vital organs and tissue enzymes activities of male albino rats. *African J Microbiol Res.* 3(9): 537-540.
- [33]. Prakash, A.O., Tewari, P.K, Shukla, S., Mathur, R. and Tewati, K.K. (1987). Postcoital antifertility effect of some medicinal plants in rats. *Ind. Drug* 25:40-44.
- [34]. Rizzo, D.C. (2010). The Blood in *Fundamentals Of Anatomy Physiology* 3rd edn Delmar, Cengage Learning U.S.A. Pp. 299-307.
- [35]. Saladin, K. S., (2010). *Circulatory System in Anatomy and Physiology the unity of form and function* 5th edn. McGraw-Hill New York pp. 684-691.
- [36]. Sembulingam, K. and Sembulingam, P. (2010). *Blood and Body Fluid in Essentials Of Medical Physiology* 5th edn Jaypee Brothers Medical Publishers New Delhi, Pp. 56-125.
- [37]. Shukla, S., Mathur, R. and Prakash, A.O. (1988). Antifertility profile of the aqueous extract of *Moringa oleifera* roots. *J. Ethnopharmacol.* 22:51-62.
- [38]. Shukla S, Mathur R, Prakash AO (1989) Histoarchitecture of the genital tract of ovariectomized rats treated with an aqueous extract of *Moringa oleifera* roots. *J Ethnopharmacol* 25: 249-261.
- [39]. Siddhuraju, P. and Becker, K. (2003). Antioxidant properties of various solvent extracts of total phenolic constituents from three different agro-climatic origins of drumstick tree (*Moringa oleifera* Lam.). *J Agric Food Chem* 15: 2144–2155.
- [40]. Standing, S., Neil, R.B., Collins, P., Alan, C., Gatzoulis, M. A., Healy, C. J., DAavid, J., Mahadevan, V. C., Newell, R.L.M. and Wigley, C.B. (2008). Spleen and blood in Gray's Anatomy, the anatomical Basis of clinical practice 40th edn Churchill livingstone Elsevier Spain Pp. 67-75, 1191-1195.
- [41]. Stuart, I.F. (2006). *Heart and Circulation In Human physiology* 8th edn McGraw-Hill Companies New York Pp. 367-372.
- [42]. Swenson, M.J. and Reece, O.W. (1993). *Blood in Duke's Physiology of Domestic Animals*. 1st edn, Comstock Publishing Associates U.S.A, Pp. 312-315.