

## A Case Report of Bilateral iris, lens and chorioretinal Coloboma

Nanda.L<sup>1</sup>, Sanjana.S.M.<sup>2</sup>, V.K. (Brig) Srivastava<sup>3</sup>, Rakesh Uthappa.N<sup>4</sup>

<sup>1</sup>Department of Ophthalmology, Rajarajeswari Medical College & Hospital/ RGUHS Bengaluru, India

<sup>2</sup>Department of Ophthalmology, Rajarajeswari Medical College & Hospital/ RGUHS Bengaluru, India

<sup>3</sup>Department of Ophthalmology, Rajarajeswari Medical College & Hospital/ RGUHS Bengaluru, India

<sup>4</sup>Department of Ophthalmology, Rajarajeswari Medical College & Hospital/ RGUHS Bengaluru, India

**Abstract:** Colobomas can arise anywhere along the line of fusion of the embryonic fissure, which extends posteriorly from the optic disc to the inferior pupillary frill of iris anteriorly. Inadequate closure of the superior end causes optic disc coloboma while more widespread failure to close causes retinochoroidal coloboma. We present a rare case report of bilateral lens (which is very rare), iris, and retinochoroidal coloboma, in a 30 yrs old patient who came with a history of diminution of vision in both eyes. The visual field of each eye displayed an absolute scotoma corresponding to the size and location of the coloboma. The patient was given best possible refractive correction in left eye and was advised regular follow up because complications may occur at any time.

**Keywords:** Chorioretinal coloboma; lens coloboma; iris coloboma; optic disc.

### I. Introduction

Ocular coloboma results from incomplete closure of the embryonic fissure of the neuroectodermal optic cup around 5–8 weeks of gestation.<sup>[1]</sup> Closure starts at the equator and continues anteriorly and posteriorly. Any insult during this period results in defects of varying size and location. A coloboma may extend from the iris margin to the optic disc and involve one or more defects along the fusional lines.

A coloboma affecting the posterior segment of the eye can be unilateral or bilateral. It is bilateral in about 60% of cases.<sup>[2]</sup> If the foetal fissure fails to close posteriorly, then a coloboma affecting the retinal pigment epithelium (RPE), neurosensory retina, or choroid may occur. The defect is essentially a bare sclera with the overlying RPE, retina, or choroid missing. In some cases, although the retina is present, it is hypoplastic and gliotic.<sup>[3]</sup> Coloboma typically occurs in the inferonasal quadrant, and may extend to the optic nerve. Chorioretinal coloboma is usually asymptomatic despite significant upper visual field defects. A lens coloboma is usually a unilateral rarely bilateral commonly seen in lens periphery, which occurs as a result of a localized absence of zonules and it may be associated with colobomas of iris, ciliary body or choroid or associated with ectopia lentis, spherophakia or localized lens opacities. It may occur because of persistence of mesodermal vascular capsules remnants which prevents the development of zonules in that area.

Chorioretinal coloboma have numerous associated systemic conditions involving the cardiovascular, central nervous, musculoskeletal, gastrointestinal, genitourinary and nasopharyngeal systems.<sup>[4]</sup> One such syndrome is CHARGE Syndrome [coloboma, heart disease, choanal atresia, retarded growth, genital hypoplasia, ear anomalies with or without deafness]. Papillorenal syndrome is an autosomal dominant condition in which renal & urinary tract abnormalities are associated with chorioretinal coloboma, congenital optic pits and morning glory disc anomaly. A mutation of PAX 2 gene has been associated in 50% of such patients. It has been associated with retinal detachment, foveal hypoplasia & pigmented macular atrophy.

### II. Case report

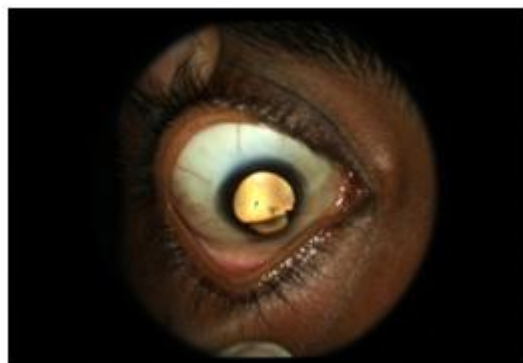A 30 Year old male patient presented with complaints of diminution of vision in both eyes from 3 yrs. His visual acuity in the right eye was counting finger 3meters unaided with no pinhole improvement and 6/12 unaided improving to 6/12 with pin hole in the left eye.

Slit lamp examination revealed iris coloboma in the inferonasal quadrant and lens coloboma in the inferior part of the lens in both eyes. [pic nos.1and2]

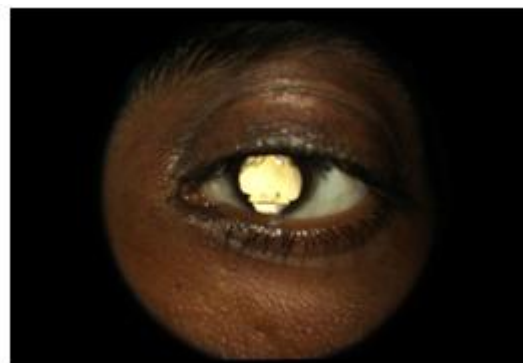On fundus examination right eye optic disc was slightly pale with blurred margins and surrounding gliosis. There was a choroidal coloboma in the inferonasal quadrant with pigmentary degenerative changes extending to the macula [pic.no.3]. Left Eye optic disc was normal and there was a choroidal coloboma. [pic.no.4]

Intraocular pressure & axial lengths were within normal limits in both eyes.

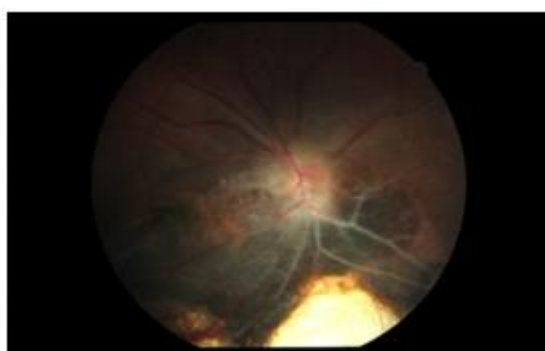
Visual fields in both eyes showed absolute scotoma corresponding to the site and location of the coloboma



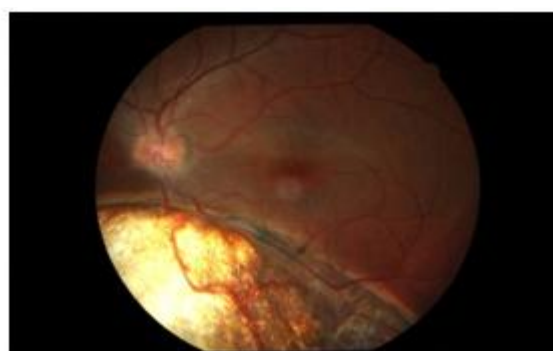
Right eye [pic. No.1]



Left eye [pic. No.2]



Right eye fundus [pic. No. 3]



Left eye fundus [pic.no.4]

### III. Discussion

Chorioretinal colobomas are congenital.<sup>[5]</sup> They can be sporadic or inherited. Bilateral chorioretinal coloboma is usually inherited in an autosomal dominant fashion with variable penetrance,<sup>[6]</sup> but some cases of recessive inheritance have been reported,<sup>[7]</sup> especially if the individual is the offspring of a consanguineous marriage as noted in a southern Indian population.<sup>[8]</sup> There is evidence of mutation in the PAX6 gene.<sup>[9]</sup> In a patient with chorioretinal coloboma, Asai-Coakwell et al.<sup>[10]</sup> identified a chromosome 8q21.2–q22.1 segmental deletion.

Chorioretinal colobomas are usually asymptomatic, although relatively large they are located in the mid-periphery away from the macula or the optic disc. However complications are not uncommon and they often cause diminished visual acuity or distorted vision especially when they extend to the macula or optic disc.<sup>[5]</sup> The most common complications are retinal detachment, which occur in 8.1–43% of cases<sup>[5, 11, 12, 13, 14, 15, 16]</sup> for which surgical treatment has variable success,<sup>[16, 17]</sup> and choroidal neovascularization<sup>[15, 18, 19, 20]</sup> This latter complication often involves the optic nerve head.<sup>[21, 22, 23, 24, 25]</sup> The risk of a complication can develop at any age throughout life. Of the few cases of chorioretinal colobomas in which choroidal neovascularization occurred that have been reported in the literature, two were aged 1 year old<sup>[25]</sup> four were in their 20s<sup>5, 15, 20, 25</sup> and two were aged 65 and 70 years old, respectively.<sup>[22]</sup>

### References

- [1]. [1] Duvall J, Miller SL, Cheatle E, Tso MO. Histopathologic study of ocular changes in a syndrome of multiple congenital anomalies. *Am J Ophthalmol.* 1987; 103:701-5.

#### Medline

- [2]. Pavan-Langston D. *Manual of Ocular Diagnosis and Therapy.* Boston: Little, Brown and Co; 1996. p. 350  
[3]. Yanoff M, Fine BS. *Ocular Pathology: A Text and Atlas.* Philadelphia: Harper and Row; 1982. p. 402–4  
[4]. En: Alexander A., editors. *Primary Care of the Posterior Segment.* Norwalk: Appleton & Lange; 1994. 512 p  
[5]. Gupta V, Gupta A, Dogra MR. Subretinal neovascularization associated with retinochoroidal coloboma. *Indian J Ophthalmol.* 1997; 45:116-7.

#### Medline

- [6]. Yanoff M, Duker JS. *Ophthalmology.* St. Louis: Mosby/Elsevier; 2009. p. 957  
[7]. Easty DL, Sparrow JM. *Oxford Textbook of Ophthalmology.* Oxford: Oxford Medical Publications; 1999. p. 1051  
[8]. Hornby SJ, Dandona L, Jones RB, Stewart H, Gilbert CE. The familial contribution to non-syndromic ocular coloboma in south India. *Br J Ophthalmol.* 2003; 87:336-40.

#### Medline

- [9]. Azuma N, Yamaguchi Y, Handa H, et al. Mutations of the PAX6 gene detected in patients with a variety of optic-nerve malformations. *Am J Hum Genet.* 2003; 72:1565-70.

**Medline**

[10]. Asai-Coakwell M, French CR, Berry KM, et al. GDF6, a novel locus for a spectrum of ocular developmental anomalies. *Am J Hum Genet.* 2007; 80:306-15.

**Medline**

[11]. Daufenbach DR, Ruttum MS, Pulido JS, Keech RV. Chorioretinal colobomas in a pediatric population. *Ophthalmology.* 1998; 105:1455-8.

**Medline**

[12]. Gopal L, Kini MM, Badrinath SS, Sharma T. Management of retinal detachment with choroidal coloboma. *Ophthalmology.* 1991; 98:1622-7.

**Medline**

[13]. ]Jesberg DO, Schepens CL. Retinal detachment associated with coloboma of the choroid. *Arch Ophthalmol.* 1961; 65:163-73.

**Medline**

[14]. Morrison DA, Fleck B. Prevalence of retinal detachments in children with chorioretinal colobomas. *Ophthalmology.* 1999; 106:645-6.

**Medline**

[15]. Steahly LP. Retinochoroidal coloboma: varieties of clinical presentations. *Ann Ophthalmol.* 1990; 22:9-14.

**Medline**

[16]. Unli N, Kocaoglan H, Acar MA, Aslan BS, Duman S. Surgical management of retinal detachment with choroidal coloboma. *Eur J Ophthalmol.* 2002; 12:299-303.

**Medline**

[17]. Gopal L, Badrinath SS, Sharma T, et al. Surgical management of retinal detachments related to coloboma of the choroid. *Ophthalmology.* 1998; 105:804-9.

**Medline**

[18]. Leff SR, Britton WA, Brown GC, Lucier AC, Brown JF. Retinochoroidal coloboma associated with subretinal neovascularization. *Retina.* 1985; 5:154-6.

**Medline**

[19]. Maberley AL, Gottner MJ, Antworth MV. Subretinal neovascularization associated with choroidal coloboma. *Can J Optom.* 1989; 24:172-4.

[20]. Rouland JF, Constantinides G. Retinochoroidal coloboma and subretinal neovascularization. *Ann Ophthalmol.* 1991; 23:61-2.

**Medline**

[21]. Brodsky MC. Magnetic resonance imaging of colobomatous optic hypoplasia. *Br J Ophthalmol.* 1999; 83:755-6.

**Medline**

[22]. Dailey JR, Cantore WA, Gardner TW. Peripapillary choroidal neovascular membrane associated with an optic nerve coloboma. *Arch Ophthalmol.* 1993; 111:2-441.

[23]. Guirgis MF, Lueder GT. Choroidal neovascular membrane associated with optic nerve coloboma in a patient with CHARGE association. *Am J Ophthalmol.* 2003; 135:919-20.

**Medline**

[24]. Shaikh S, Trese M. Infantile choroidal neovascularization associated with choroidal coloboma. *Retina.* 2003; 23:585-6.

**Medline**

[25]. Spitzer M, Grisanti S, Bartz-Schmidt KU, Gelisken F. Choroidal neovascularization in retinochoroidal coloboma: thermal laser treatment achieves long-term stabilization of visual acuity. *Eye (London).* 2006; 20:972-1069.