

Congenitally Missing Lateral Incisor with Orthodontics, Bone Grafting and Single-Tooth Implant: A Case Report

Abu-Hussein Muhamad*, Abdulgani Azzaldeen**, Watted Nezar***
Zahalka Mohammed****

*University of Naples Federic II, Naples, Italy, Department of Pediatric Dentistry, University of Athens, Athens, Greece.

**Department of Orthodontics, Arab American University, Jenin, Palestine

*** Department of Conservative Dentistry, Al-Quds University, Jerusalem, Palestine

****Postgraduate student, Programm of Implantology, Gothe University in Frankfurt/Germany

Abstract: Congenitally missing teeth are frequently presented to the dentist. Interdisciplinary approach may be needed for the proper treatment plan. The available treatment modalities to replace congenitally missing teeth include prosthodontic fixed and removable prostheses, resin bonded retainers, orthodontic movement of maxillary canine to the lateral incisor site and single tooth implants. Dental implants offer a promising treatment option for placement of congenitally missing teeth. Interdisciplinary approach may be needed in these cases. This article aims to present a case report of replacement of unilaterally congenitally missing maxillary lateral incisors with dental implants.

Keywords: Congenitally missing teeth, dental implants, interdisciplinary approach.

I. Introduction

Missing maxillary lateral incisors creates an esthetic problem with specific orthodontic and prosthetic considerations, therefore treatment planning always poses a challenge to the clinicians.(1)

The frequency of hypodontia varies, according to different investigators, from 0.27 to 11.0% depending on the methods of registration, grouping of the material and racial differences. The vast majority of cases of agenesis among the permanent teeth involve the second premolars and maxillary lateral incisors. The required amount of space needed for replacing missing lateral incisors is determined by two factors. The first is the esthetics of mesiodistal width between the anterior teeth. Occlusion is the second factor that affects the amount of space that needs to be created(2,3,4).

The prosthetic options with orthodontic space opening currently available for replacing missing teeth are traditional fixed partial dentures, resin-bonded fixed partial dentures, removable partial dentures and osseointegrated implant supported prostheses.

Osseointegrated implants are the most biologically conservative and most commonly used option for replacing missing lateral incisors(1,4,5).

When implants are part of the treatment plan, their size dictates the amount of space that needs to be opened. The minimum interdental space needed for a 3.75 mm implant that provides optimal gingival health and sufficient bony support is about 6 mm. Currently, the preferred method for replacement appears to be the implant retained crown following orthodontic treatment. Long-term reliability studies leave little doubt that implant-retained crowns are the most stable long-term restoration available. With current treatment modalities, the replacement can be very esthetic and durable .(6,7)

Regardless of the type of replacement therapy, multiple disciplines will most likely be involved in managing the patient with congenitally missing teeth. Multidisciplinary treatment considerations require excellent communication to obtain the result necessary for restorative excellence. A thorough diagnosis and treatment plan must precede orthodontic therapy. The orthodontist must understand critical parameters of root alignment and symmetrical distribution of edentulous spaces. Diagnostic wax-ups at the end of orthodontic treatment can be decisive in determining final tooth position, and consultation with the surgeon who will place the implants is critical.(1,7,8,9)

Circumstances exist that contraindicate the use of implants:

1. Patient age and lack of physical maturity: implants should not be placed until definitive proof of growth completion exists. A good guide is consecutive-year cephalometric radiographs revealing no further growth
2. Inadequate root alignment and spacing: implants cannot be successfully placed if the appropriate dimension of bone (facial-lingual and mesio-distal) is unavailable in which to place the implant
3. Patient is unwilling to have orthodontic treatment.
4. Inadequate bone architecture in conjunction with a patient unwilling to have bone-grafting procedures.

5. Patient's emotional maturity.
6. Financial concerns: parents could possibly make compromised decisions based on lack of funds.

Older teenagers and young adults typically go through life transitions that keep them away from dental offices. This is particularly important when considering interim treatments that require frequent recall maintenance visits.(10,11)

Some situations dictate a postponement of definitive treatment. Missing front teeth are usually diagnosed early in a child's life. While many of the restorative decisions are made for them by parents and their dentist, the emotional maturity of a patient could indicate postponement of definitive treatment. It can be advantageous to allow a patient to make his or her own decision as a responsible adult(1,11,12,13). Conservative, reversible tooth replacement schemes fulfill immediate esthetic needs while postponing final decisions concerning definitive replacement therapy.(11)

To accommodate a standard implant there should be a minimum of 10 mm of incisio-gingival bone and a minimum of 6.0 mm of facial-lingual bone (2). In cases where there is insufficient alveolar bone for implant placement, ridge augmentation may be necessary in addition to orthodontic repositioning of adjacent teeth (3). Since routine ridge augmentation techniques and materials are expensive and require a lengthy healing time, we presented in this case report a chair-side ridge augmentation procedure using autograft bone harvested with trephine drills and placed without using screws.(14)

Adequate space for the implant is also required between the adjacent roots. The average dental implant fixture is 3.75 mm wide, and 1 to 2 mm of space is necessary between the fixture and the adjacent roots (3,11). Typically, between 6 and 8 mm of bone between the central and canine roots is recommended. Creating adequate space between the roots must be specifically addressed since the central and canine roots may be brought into closer proximity when the teeth are initially aligned orthodontically (2).To create adequate space for the implant, further orthodontic treatment may be necessary to move the roots further apart. Space for the coronal restoration must also be assessed. The average implant platform, which is 4.0 mm wide, requires a space of 1.0 mm mesially and distally between the platform and the adjacent tooth to facilitate proper healing and the development of a papilla postoperatively, thus, a minimum of 6 mm of space for the lateral crown is required (4,5,11) The aim of this study was to report a case in which a congenitally missed lateral incisor was treated with orthodontic interventions ,bone grafting and single tooth implantation.

II. Case Report

This case was a 18-year-old female who had congenitally missed maxillary left lateral incisor. Her chief complaint was diastema and missing her upper left lateral. (Figs. 1a-c)

The treatment plan was:

- Initial therapy (SRP)
- Orthodontic therapy for alignment and achievement of sufficient space.
- Surgery: Ridge augmentation and implant placement.
- Prosthesis.
- SPT (Supportive periodontal therapy).

First by orthodontic therapy the space required for implant placement was achieved. (Figs. 2a-c)

Materials and Methods: Autogenous bone grafts are the best materials for limited ridge augmentations. They can be obtained in a number of ways and from several donor sites. In the present case report, the recipient sites were limited in size, and trephine drills .(6) were used to obtain the bone graft because the tomography showed that the ridge width was insufficient for implant placement. After anesthetizing the operation site with lidocaine a crestal incision was performed. An envelope flap was retracted using blunt dissection to limit it to the graft site with no excessive extension. The periosteum was raised, intact and undamaged, from the bone. The flap was extended laterally to obtain enough space for the bone graft, and no vertical incision was made. We obtained bone from the internal oblique ridge area. A lingual sulcular incision was made to expose the donor site from the distal end of the first molar to the distal aspect of second (or third, if present) molar. A number 5 or 6 trephine drill was used as needed to harvest one or two pieces of bone.(Figs. 3a-b)

Next, the donor site was sutured and compressed with damp gauze sponge. The bone blocks were placed inside the envelope flap at the recipient site. In some cases, the shape of the bone graft was adjusted to enhance its adaptation to the recipient site. Due to the limited extension of the flap and the orderly setting of the bone blocks, there was no need to use screws to secure the bone grafts in place.

The recipient site was then sutured and covered with periodontal dressing . From 24 h prior to the operation, patients were administered Amoxicillin (500 mg) every 6 h, and the treatment continued for 5–7 d. Chlorhexidine mouthwash (0.2% solution) was prescribed for two weeks for all of the cases. Additionally, the

patients were prescribed Acetaminophen plus Codeine. After a week, the sutures were removed. Six months later, the recipient site was reopened, and the bone width was measured, and one Implant with 3.8 mm diameter and 10 mm length was placed. Three months later, second stage surgery and aesthetic surgery for leveling of gingival margins was performed and final restoration was placed (Figs. 4a-d,5a-b).

III. Discussion

Patients afflicted with congenital absence of either single or multiple teeth are unique and appropriate candidates for tooth replacement using osseointegrated implants. However, adjunctive procedures to optimize esthetics and longevity are frequently needed for replacement of missing tissues consistently found in these patients(,14,15).

Frequently, these patients have differences in spatial position relative to the opposing arch, which places emphasis on ancillary treatment with orthodontics and oral surgery. A thorough diagnostic work-up should include an interdisciplinary approach to ensure optimal treatment and timing of treatment in those who are developing.(11,16)

This case report was a simple method for ridge augmentation in limited edentulous areas. Titanium endosseous implants have become a successful treatment for tooth loss and have a high predictability for good prognoses. In some cases, implant placement is difficult or even impossible due to bone resorption. In such situations, the use of bone grafts, especially autogenous grafts, is an excellent solution with many advantages. However, one disadvantage of autogenous bone grafts is that they require two simultaneous surgeries.

Verdugoe et al. (2009) previously evaluated different areas of the mandible as bone graft donor sites and found that the second and third molar regions could provide good bone graft pieces with a mean thickness of 2.8 ± 0.6 mm (8). We performed a simple, non-aggressive operation by designing an envelope flap limited to the edentulous area. The bone blocks that were harvested using trephine drills were placed into the envelope, and there was no need to secure the bone pieces.(7,8,11,17)

Dental implants provide a promising treatment options for treatment options for the replacement of congenitally missing teeth. They provide the advantages of preservation of adjacent natural tooth structure, preservation of the alveolar ridge and achievement of optimal esthetic and restorative results(18,19). The limitations faced for the implant patient includes inadequate available space, inadequate alveolar ridge thickness and inadequate alveolar bone support for gingival papilla. Another factor that plays an important role is completed skeletal growth or the age of the patient at the time of implant placement. If the implant is placed before the cessation of the peak growth periods, it can cause various esthetic and functional problems. Orthodontic treatment is required when the space available between the adjacent roots and the adjacent crowns is inadequate. In this case the space available for implant placement was inadequate after extraction of right and left primary maxillary canines(11,20). To gain the space for implant placement, simultaneous closure of midline diastema and distalization of canine was done.

The advantages of this technique are its simplicity, the fact that there is no need for decortication of the recipient site, and no need for using screws. Previously, Accocella et al. (2009) used bone blocks obtained from the mandibular ramus for lateral augmentation and reported a 4 ± 0.77 mm increase in ridge width (9). Funaki et al. (2009) used distraction osteogenesis and bisection techniques to increase ridge width and reported a 2.7 mm increase for distraction and a 1.7 mm increase for bisection (10). Antal used the same method for achievement of optimal emergence profile (11).

IV. Conclusions

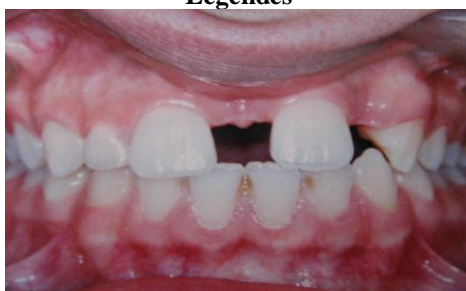Dental implants are the treatment of choice for most patients with congenitally missing laterals. An implant will preserve tooth structure and alveolar bone and provide esthetics and function. However, this case report demonstrate an acceptable increase in ridge width and this technique may be used successfully as an alternative to the current, invasive augmentation methods. Furthermore, successful restorative treatment involving implants depends on interdisciplinary treatment planning, preprosthetic orthodontic tooth alignment for achievement sufficient space, bone grafting for augmentation ridge width and implant surgery and prosthesis.

References

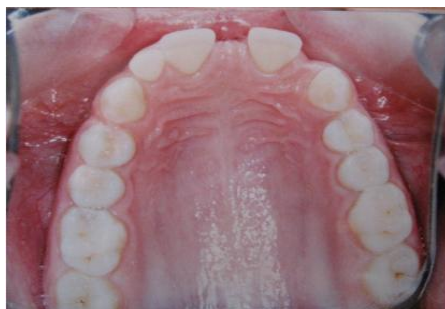- [1]. Richardson G, Russell KA. Congenitally missing maxillary lateral incisors and orthodontic treatment considerations for the single-tooth implant. *J Can Dent Assoc* 2001;67:25-8
- [2]. Dhanrajani PJ. Hypodontia: Etiology, clinical features, and management. *Quintessence Int* 2002;33:294-302.
- [3]. Bishop K, Addy L, Knox J. Modern restorative management of patients with congenitally missing teeth: 4. The role of implants. *Dent Update* 2007;34:79-80,82.
- [4]. Kokich VG. Maxillary lateral incisor implants: Planning with the aid of orthodontics. *J Oral Maxillofac Surg* 2004;62:48-56
- [5]. Valle AL, Lorenzoni FC, Martins LM, Valle CV, Henriques JF, Almeida AL, et al. A multidisciplinary approach for the management of hypodontia: Case report. *J Appl Oral Sci* 2011;19:544-8
- [6]. Millar BJ, Taylor NG. Lateral thinking: The management of missing upper lateral incisors. *Br Dent J* 1995;179:99-106

- [7]. Zarb GA, Schmitt A. The longitudinal clinical effectiveness of osseointegrated dental implants: The Toronto study. Part I: Surgical results. *J Prosthet Dent* 1990;63:451-7
- [8]. Verdugo F, Simonian K, Smith McDonald R, Nowzari H. Quantitation of mandibular ramus volume as a source of bone grafting. *Clin Implant Dent Relat Res* 2009; 11 Suppl 1:e32-7.
- [9]. Acocella A, Bertolai R, Colafranceschi M, Sacco R. Clinical, histological and histomorphometric evaluation of the healing of mandibular ramus bone block grafts for alveolar ridge augmentation before implant placement. *J Craniomaxillofac Surg* 2010; 38: 222-30.
- [10]. Funaki K, Takahashi T, Yamuchi K. Horizontal alveolar ridge augmentation using distraction osteogenesis: comparison with a bone-splitting method in a dog model. *Oral Surg Oral Med Oral Pathol Oral Radiol Endod* 2009;107:350-58.
- [11]. Abu-Hussein M., Watted N., Abdulgani A., and Bajali M.; Treatment of Patients With Congenitally Missing Lateral Incisors: Is an Interdisciplinary Task, *RRJDS*2014,2(4),53-68.
- [12]. Polder BJ, Van't Hof MA, Van der Linden FP, Kuijpers-Jagtman AM A meta-analysis of the prevalence of dental agenesis of permanent teeth. *Community Dent Oral Epidemiol.* 2004;32: 217-226
- [13]. Högberg G, Lagerheim B, Sennerstam R The 9-year crisis reflected at a rehabilitation center, at a child health care center and at a child and adolescent psychiatric center. *Lakartidningen.* 1986, 83: 2038-2042
- [14]. Kokich OV, GA Kinzer and J Janakievski. Congenitally missing maxillary lateral incisors: Restorative replacement. *American J Orthodont Dentofacial Orthop.* 2011;139(4):435-445.
- [15]. Krassnig M, and S Fickl. Congenitally missing lateral incisors- A comparison between restorative, implant, and orthodontic approaches. *Dent Clin N Am.* 2001;1:283-299.
- [16]. Garg AK. Treatment of congenitally missing lateral incisors: Orthodontics, Bone grafts, and Osseointegrated implants. *Dental Implantology Today.* 2002,13(2): 9.
- [17]. Garib DG, NLM Zanella and S Peck. Associated Dental Anomalies: Case report. *J Appl Oral Sci.* 2005;13(4): 431-436
- [18]. Watkin A, Kerstein RB. Improving darkened anterior peri-implant tissue color with zirconia custom implant abutments. *Compend Contin Educ Dent* 2008;29:238-40,242.
- [19]. Aydin C, Yilmaz H, Ata SO. Single-tooth zirconia implant
- [20]. located in anterior maxilla. A clinical report. *N Y State Dent J* 2010;76:30-3.
- [21]. Fudalej P, Kokich VG, Leroux B. Determining the cessation of vertical growth of the craniofacial structures to facilitate placement of single-tooth implants. *Am J*
- [22]. *Orthodont Dentofacial Orthop* 2007;131(4 Suppl):S59-67.

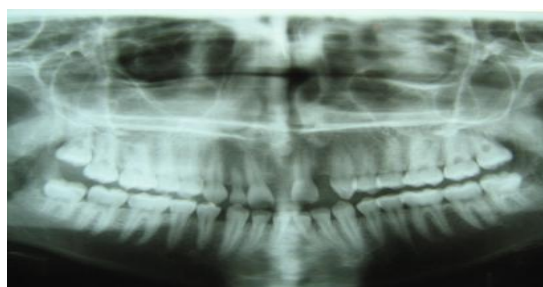
Legendes



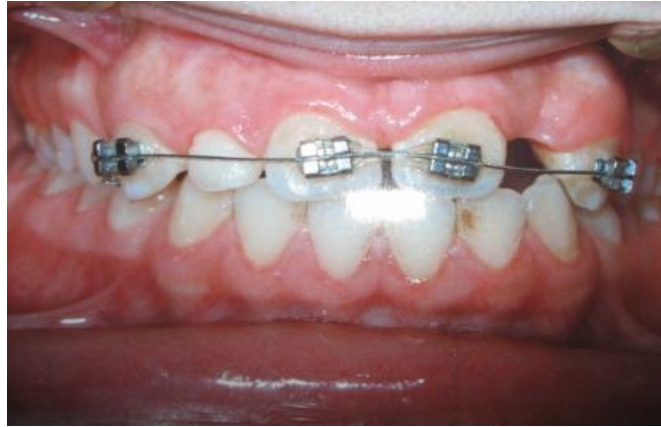Figs. 1a- Intraoral view of the patient



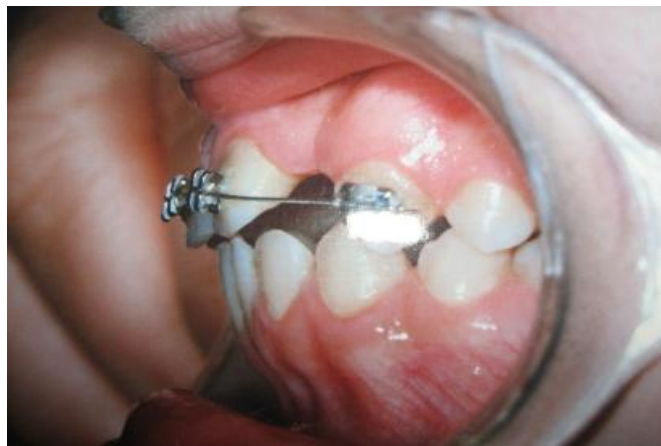Figs. 1b -Occlusal view of the patient



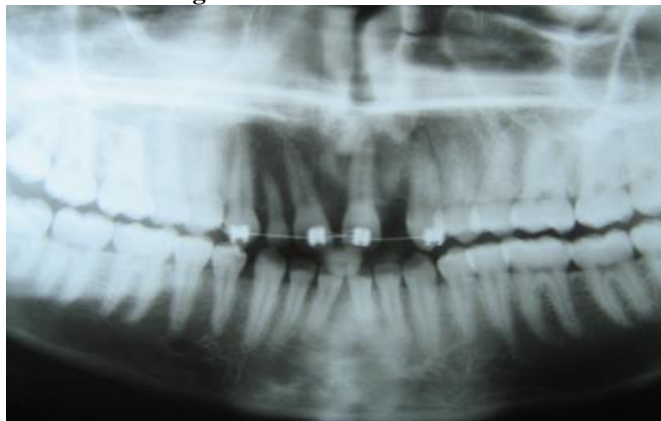
Figs. 1c -OPG of the patient



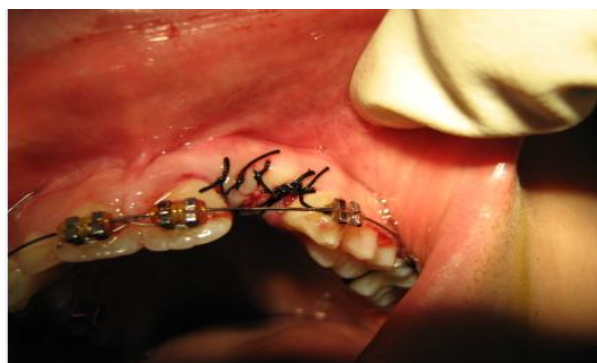Figs. 2a -Orthodontic treatment for space management

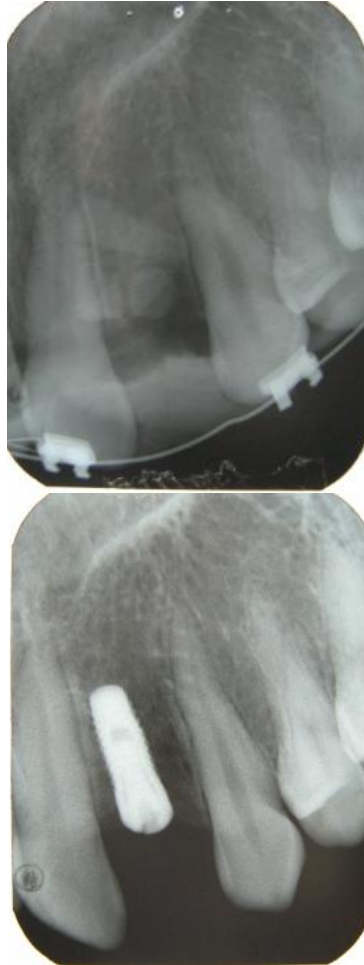

Figs. 2b- Orthodontic treatment

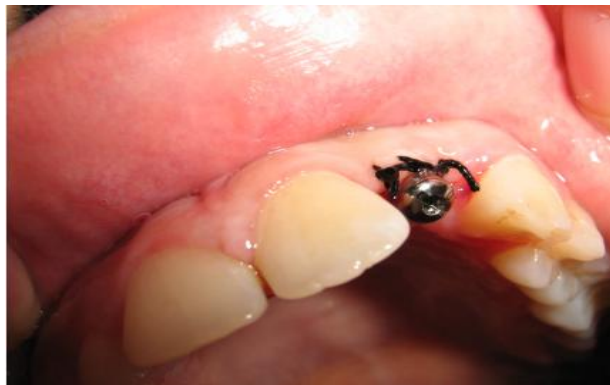

Figs. 2c-Panoramic Orthodontic treatment

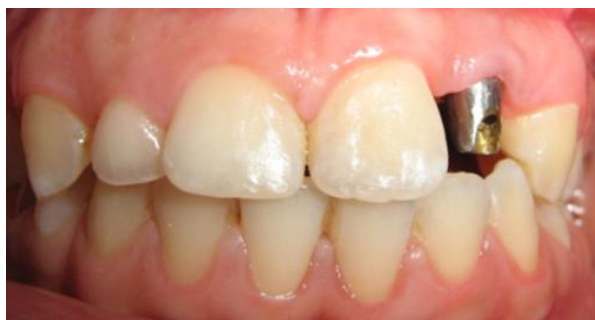



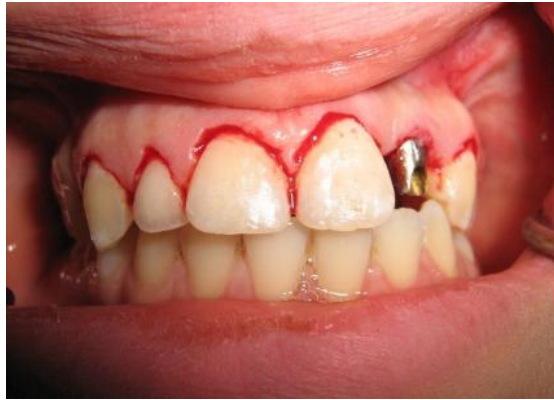Figs. 4a- PA radiography immediately after graft placement



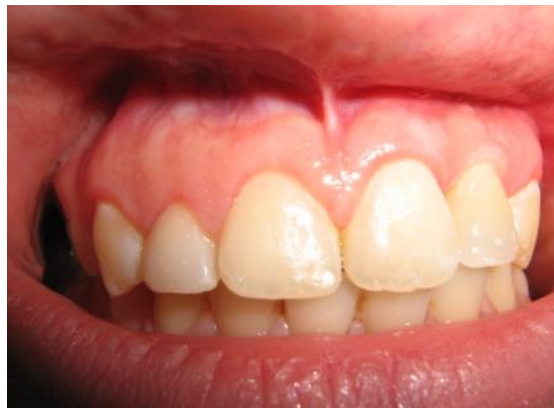Figs. 4b- Gingival Former placement in second stage surgery



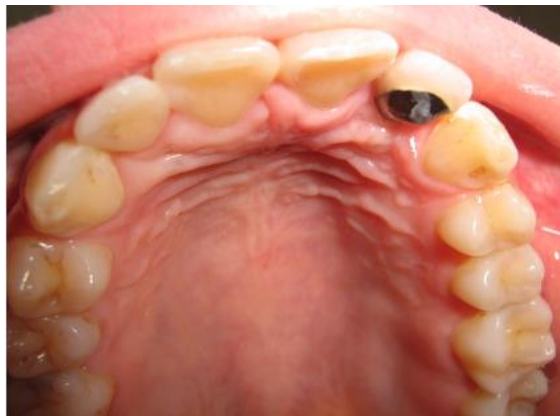Figs. 4c -Abutment placement



Figs. 4d- Aesthetic surgery for leveling of gingival margins.



Figs. 5a- Final Restoration



Figs. 5b- Final Restoration.