

Imaging Approach with Magnetic Resonance Imaging to evaluate White Matter Lesions - A Prospective Study

Dr. Sindu P. Gowdar, Dr. Pramod Setty J., Dr. Naveen S. Maralihalli,
Dr. Jeevika.M.U., Dr. Mohd Kamran Siddiqui

Abstract:

Background and Objectives: MRI is an important noninvasive imaging modality which has a very high sensitivity for detecting white matter lesions due to its excellent gray-white matter resolution. The objectives are: to evaluate the role of magnetic resonance imaging in white matter diseases, to establish an accurate diagnosis. To assess the severity and extent of the underlying lesion in various conditions and to demonstrate the different patterns of abnormal myelination in white matter diseases.

Materials and Methods: 50 patients who were clinically suspected of white matter diseases underwent MR imaging in a period of 2 years from 2012- 2014 using 1.5T PHILIPS Achieva machine. The main source of data for the study are patients from the following teaching hospitals attached to Bapuji Educational Association, J.J.M. Medical College, Davangere. (Bapuji hospital, Chigateri General Hospital, Women & Child Health Care). Sequences used localizer sequence conventional spin echo, sagittal FLAIR, STIR, T1 FS, axial and sagittal T1 images, axial, sagittal and coronal T2 images, proton density images, diffusion weighted imaging and ADC map, axial grey matter only and white matter only sequences, IV contrast study (optional).

Results: 50 patients who were clinically suspected of white matter diseases were subjected to MR imaging. Among these 50 patients, 26% had Leukodystrophies (Leukodystrophies include ALD, Alexander Disease, Canavan Disease, Krabbe's Disease, MLD, and Nonspecific Leukodystrophy), 16% had ADEM (16%) and 16% had Vacuolating Leukoencephalopathies (16%) (including PVL, Megaloencephalic Leukoencephalopathy and Cavitating Leukoencephalopathy and Vanishing white matter diseases), 12% had hypomyelination, 8% had Multiple Sclerosis and SVIC, 4% each of Leigh's Disease, HIV Encephalopathy, Nonspecific demyelination and 2% had progressive multifocal Leukoencephalopathy. In general, patients in the paediatric age group constituted 82% of the total study group with an overall there was slight male predominance. Post contrast studies helps in differentiating acute from chronic lesions and thus monitoring the progression of the disease. MRI allows simultaneous imaging of orbit especially in cases of multiple sclerosis. It helps in early diagnosis of mild and atypical cases so that treatment can be started early in curable disease. It is ideal for posterior fossa and spinal cord imaging.

Conclusion: MR imaging has become the primary imaging modality in patients with white matter diseases and plays an important role in the identification, localization, and characterization of underlying white matter abnormalities in affected patients. Systematic analysis of the finer details of disease involvement may permit a narrower differential diagnosis, which the clinician can then further refine with knowledge of patient history, clinical testing, and metabolic analysis. MRI is noninvasive and there is no radiation hazard. Its multiplanar imaging capability and excellent grey-white matter resolution makes MRI very sensitive in detecting subtle white matter lesions. In our study we observed that FLAIR sequence has better sensitivity for white matter lesions especially those in periventricular locations. Specificity of MR imaging can be improved by MR Spectroscopy studies.

Keywords: Magnetic Resonance Imaging, Leukodystrophies, White Matter Diseases, MRI, Leukoencephalopathy.

I. Introduction

Only recently with the advances in imaging technology, have white matter diseases of central nervous system been extensively studied and understood. CT and MRI are the imaging modalities which are currently available for the investigation of these diseases and it has been proven beyond doubt that MRI is far superior to CT and the imaging modality of the choice in these diseases.

MRI is an important noninvasive imaging modality which has a very high sensitivity for detecting white matter lesions due to its excellent gray-white matter resolution. Multiplanar imaging is possible only with MRI, which helps in the detection and localization of lesions. It is also found to be ideal in posterior fossa imaging and allows simultaneous imaging of extra cerebral sites like spinal

cord and optic nerve. MRI thus is very helpful in defining the pathogenesis and in the early diagnosis of disease and in monitoring the treatment. Recent advances like MR spectroscopy, diffusion imaging and magnetization transfer imaging have revolutionized the role of MRI in increasing the specificity of diagnosis in many of these conditions.

By correlating the clinical features and biochemical analysis with the MRI findings, we can come to a diagnosis in majority of cases. Many of the diseases if detected early are reversible and thus plays the major role of MRI in the early diagnosis so that the treatable conditions among them can be detected early and cured. This study is selected because of the important role of MRI in investigating white matter diseases and also to evaluate the data obtained from cranial MRI in these diseases.

II. Aims And Objectives

The main aims of our study was to evaluate the role of magnetic resonance imaging in white matter diseases, to demonstrate the different patterns of abnormal myelination in white matter diseases, to establish an accurate diagnosis and to narrow down the differential diagnosis in various white matter diseases and also to assess the severity and extent of the underlying lesion in various conditions of white matter diseases.

III. Methodology:

The main source of data for the study is patients from the following teaching hospital attached to Bapuji Education Association, J.J.M. Medical College, Davangere.

All patients referred to the department of Radio diagnosis with clinical history suspicious of white matter diseases in a period of 2 years from September 2012 to September 2014 will be subjected for the study.

Patients of all age groups with clinical suspicion of white matter diseases were included. Incidental finding of white matter diseases/ lesions were also considered in our study.

Our study group excluded all patients with clinical suspicion of post-traumatic white matter injury, all patients with intracranial tumors and metastatic disease, patients having history of claustrophobia and those having metallic implants insertion, cardiac pacemakers and metallic foreign body in situ.

Magnetic Resonance Imaging was done with 1.5 Tesla Philips Achieva Machine using Sense Head coils. MRI findings were correlated with biochemical parameters (for metabolites) where feasible to increase the accuracy of diagnosis.

IV. Results

Statistical analysis:

Data was entered into Microsoft excel data sheet and analyzed using Epi Info 7 version software. Categorical Data was represented in the form of frequencies and proportions. Bar diagrams and Pie chart were plotted to represent graphically.

In the study it was observed that most common white matter disease was Leukodystrophy (26%). [Leukodystrophies includes ALD, Alexander disease, Canavan disease, Krabbes disease, MLD, and Nonspecific Leukodystrophy]. Second most common disease was ADEM (16%) and Cavitating Leucoencephalopathies (16%) [PVL, Megaloencephalic leukoencephalopathy and cavitating leukoencephalopathy and Vanishing VMD]. Followed by Hypomyelination (12%), Multiple sclerosis and SVIC (8%) and others.

Table 1: MRI Diagnosis in white matter diseases

		Frequency	Percent
MRI diagnosis	Leukodystrophy	13	26.0
	ADEM	8	16.0
	Cavitating Leucoencephalopathies	8	16.0
	Hypomyelination	6	12.0
	Multiple sclerosis	4	8.0
	SVIC	4	8.0
	Leigh's disease	2	4.0
	HIV encephalopathy	2	4.0
	Nonspecific	2	4.0
	PML	1	2.0
	Total	50	100.0

Table 2: Age distribution among the White matter diseased subjects

	Age group						Total
	0 to 10 yrs	11 to 20 yrs	21 to 30 yrs	31 to 40 yrs	41 to 50 yrs	> 50 yrs	
Leukodystrophy	13	0	0	0	0	0	13
ADEM	5	2	1	0	0	0	8
Leucoencephalopathies	8	0	0	0	0	0	8
Hypomyelination	6	0	0	0	0	0	6
Multiple sclerosis	0	3	1	0	0	0	4
SVIC	0	0	0	0	0	4	4
Leigh's disease	2	0	0	0	0	0	2
HIV encephalopathy	0	0	0	1	1	0	2
Nonspecific	2	0	0	0	0	0	2
PML	0	0	0	1	0	0	1
	36	5	2	2	1	4	50

Majority 36 cases were in the age group 0 to 10 years followed by 11 to 20 yrs (5) and > 50 years (4).

100% of Leukodystrophy, Leucoencephalopathies, Hypomyelination, Leigh's disease and Nonspecific white matter diseases were observed in 0 to 10 yrs age group.

ADEM was also common among 0 to 10 yrs age group. All the 4 SVIC cases were observed in the age group >50 yrs. Multiple sclerosis was common among 11 to 20 yrs age group. HIV encephalopathy and PML was found after 30 years.

Table 3: Various types of Leukodystrophy white matter diseases

		Frequency (n=13)	Percentage
Leukodystrophy	MLD	5	38.4%
	ALD	3	23.1%
	Canavan Disease	2	15.4%
	Krabbes Disease	1	7.7%
	Alexander Disease	1	7.7%
	Nonspecific Leukodystrophy	1	7.7%

Among 13 Leukodystrophy conditions various diagnosis in the study were MLD (38.4%), ALD (23.1%), Canavan disease (15.4%), 7.7% Krabbes disease, Alexander Disease and Nonspecific Leukodystrophy.

Table 4: Various types of Leucoencephalopathies in White matter disease

Leucoencephalopathies	Frequency (n=8)	Percentage
PVL	4	50%
Megaloencephalic Leucoencephalopathy	2	25%
Cavitating Leucoencephalopathy	1	12.5%
Vanishing WMD	1	12.5%

Among 8 Leucoencephalopathies 50% was PVL, 25 % was Megaloencephalic Leucoencephalopathy and 12.5% was Cavitating Leucoencephalopathy, Vanishing WMD respectively.

V. Discussion

Normal Myelination of The Brain

The myelination of white matter is an important component of brain maturation because it facilitates the transmission of neural impulses through the CNS. The high contrast resolution of MR permits highly sensitive assessment of gray and white matter changes occurring in the maturing brain.

Normal brain myelination is a dynamic process that begins during the fifth fetal month and continues throughout life. Myelination usually occurs in a highly predictable orderly pattern so that any delay from the expected patterns can be readily detected by MR imaging.

Barkovich and colleagues¹ charted the ages at which the changes of myelination appeared on T1 and T2 weighted images.

Anatomic region	Age when changes of myelination	
	T1-weighted images	T2-weighted images
Middle cerebellar peduncle	Birth	Birth to 2 months
Cerebral white matter	Birth to 4 months	3-5 months
Posterior limb of internal capsule		
Anterior portion	Birth	4-7 months
Posterior portion	Birth	Birth to 2 months
Anterior limb internal capsule	2-3 months	7-11 months
Genu corpus callosum	4-6 months	5-8 months
Splenium of corpus callosum	3-4 months	4-6 months
Occipital white matter		
Central	3-5 months	9-14 months
Peripheral	4-7 months	11-15 months
Frontal White matter		
Central	3-6 months	11-16 months
Peripheral	7-11 months	14-18 months
Centrum semiovale	2-6 months	7-11 months

Classification of White Matter Diseases

White matter disease is a loosely defined term that includes practically any disease process that has pathological changes limited to or predominantly within the white matter. From pathological point of view white matter diseases can be broadly classified into three major groups.

PRIMARY DEMYELINATING DISORDERS:	Multiple Sclerosis	
SECONDARY DEMYELINATING DISORDERS:	Infectious:	• Acute disseminated encephalomyelitis
		• Progressive multifocal Leukoencephalopathy
		• Human immunodeficiency virus encephalopathy
		• Sub acute sclerosing pan encephalitis
	Metabolic:	• Central pontinemyelinolysis
		• Vitamin B12 deficiency
		• Beriberi
		• Wernicke encephalopathy
		• Marchiafava- Bignami disease
	Trauma:	• Diffuse axonal injury
		• Radiation changes
	Vascular:	• Thallium intoxication
• Periventricular leukomalacia		
• Aging changes affecting white matter		
DYSMYELINATING DISORDERS (AKA HEREDITARY LEUKODYSTROPHIES):	Lysosomal disorders:	• Hypertensive Leukoencephalopathies
		• Metachromatic leukodystrophy (MLD)
		• Krabbe's disease (Globoid cell leukodystrophy)
		• Neiman Pick disease
		• Fabry disease
	Peroxisomal disorders:	• GM ₁ Gangliosidosis
		• GM ₂ Gangliosidosis
		• Adrenoleukodystrophy (ALD)
	Amino acid and Organic acid metabolic disorders:	• Zellweger syndrome
		• Classic Refsum disease
	Mitochondrial dysfunction (predominantly gray matter involvement):	• Canavan's disease
		• Leigh's disease
		• Myopathy, encephalopathy, lactic acidosis, and stroke like episodes (MELAS)
		• Myoclonus epilepsy with ragged red fibres (MERRF syndrome)
	Disease of unknown metabolic defect:	• Kearns – Sayre disease
• Pelizaeus – Merzbacher disease		
		• Alexander's disease

VI. Discussion

Metachromatic Leukodystrophy

In our study five out of 13 cases of leukodystrophies suffered from metachromatic leukodystrophy (38.4%), among which 4 were males (80%) and 1 was female (20%). All patients belonged to the age group from 10 months to 25 months i.e., late infantile group.

Alves D et al² reported that late infantile constitutes 70% of all cases and this is the commonest variety.

MR imaging of these patients revealed bilaterally symmetrical and confluent lesions in all cases among which 100% incidence of periventricular white matter involvement, 80% of patients showing frontal white matter involvement and 60% showing parietal, temporal and cerebellar white matter involvement.

Tae Sung Kim et al³ studied 7 patients of Metachromatic Leukodystrophy, of which all of them showed bilateral, symmetrical and confluent high signal intensities on T2 weighted imaging. They reported 100% incidence of periventricular white matter and centrum semi ovale.

One of our patients, aged 25 months, showed involvement of subcortical U fibres. This is in correlation with the study by Tae Sung Kim et al,³ who reported that a follow up MRI of a 26 month old patient showed demyelinating process progressed to the subcortical U fibres.

In a study of three patients of Metachromatic Leukodystrophy by Humera A et al⁴, all of which were male patients showed 100% involvement of periventricular white matter showing high signal intensities on T2 weighted and FLAIR images.

Is an autosomal recessive neurological disorder characterized by demyelination and accumulation of sulfatides in the nervous system due the deficient activity of the lysosomal enzyme aryl sulfatase A.

There are 4 principal forms of the disease, congenital late infantile, juvenile and the adult variant of which the late infantile form is the most common.

. It has been observed that patients with onset at 1-2 years of age constitute 70% of all cases.⁵

MRI reveals extensive symmetric increase in the signal intensity of periventricular and subcortical white matter on T2-weighted images resulting in a butterfly configuration. The demyelination initially spares the subcortical U fibres and the basal ganglia and shows no enhancement on contrast administration. The lesion usually begins in the frontal region and shows posterior progression unlike the other leukodystrophies

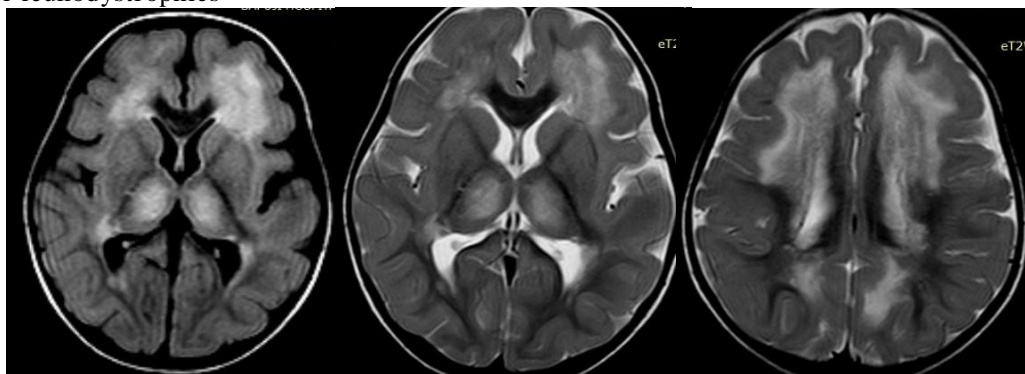


FIG 1 (a,b,c): METACHROMATIC LEUKODYSTROPHY - Axial T2 and FLAIR hyperintensities are seen in bifrontal, temporal and parietal periventricular white matter with sparing of subcortical U fibres. The hyperintensities are more marked in bifrontal lobes and cerebellum. Oval hyperintense foci with central cystic area are seen involving bilateral thalami.

Adrenoleukodystrophy:

In our study, three out of 13 cases of leukodystrophies suffered from Adrenoleukodystrophy (23.1%), among which two were males (66.67%) and one was female (33.33%). Age of patients ranged from 9 months to 6 years. Snyder RD et al⁶ reported that childhood onset Adrenoleukodystrophy (4-8 years) is the commonest type. This is a true leukodystrophy, with no lesions within the grey matter structures. White matter abnormalities usually appear in the occipital regions initially, with early involvement of the splenium of the corpus callosum and posterior limbs of internal capsules.⁷ The progression pattern of the disease is centrifugal and postero-anterior.⁸ This results in the most characteristic imaging feature of the disease.

Our study shows no involvement of frontal white matter in all three patients. All patients showed temporal and occipital white matter abnormalities (100%) and 66.67% showing periventricular and brain stem involvement. All patients showed enhancement on contrast study (100%) and also choline peak in MR spectroscopy. In a study of three patients of Adrenoleukodystrophy by Humera A et al⁹, it was reported 66.67% involvement of periventricular white matter specifically in trigonal area showing high signal intensities on T2

weighted and FLAIR images. Elias R. Melhem et al⁹ in a study of forty three patients of Adrenoleukodystrophy reported 21 patients (49%) showing contrast enhancement.

This is an X-linked recessive disorder mapped to Xq28 region and thus presents exclusively in males. Though the disease was first described by Siemerling and Creutzfeldt in 1923, it was Singh et al who showed that the accumulation of very long chain fatty acids (VLFAS) occur in Adrenoleukodystrophy and established it as a peroxisomal disorder.¹⁰ The classic MR appearance is the bilateral and symmetrical involvement of the occipital lobes and the splenium of corpus callosum with marked prolongation of T1 and T2 relaxation times. Enhancement of the inflammatory leading edge of demyelination is noted when contrast is administered. In the early phase of the disease, the peripheral white matter is spared. The corticopontine and corticospinal tracts in the brain stem show T2 prolongation. The splenium is atrophic and is typically involved. Calcification can be seen in the parieto-occipital region. Atypical patterns of involvement like frontal involvement or unilateral involvement can be seen. Secondary degenerative changes in the posterior limb of the internal capsule, cerebral peduncles, pons, pyramid and cerebellum are common.

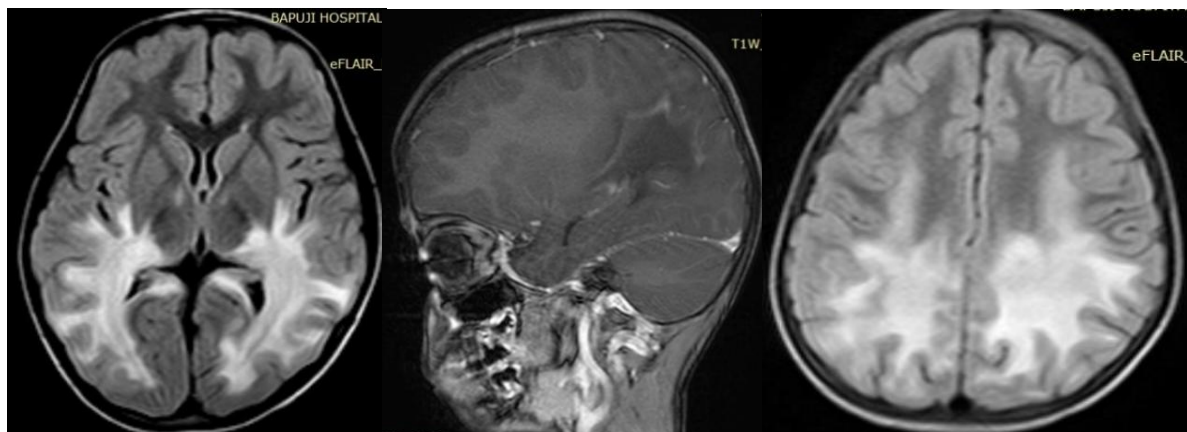


FIG 2 (a,b,c,d) :ADRENOLEUKODYSTROPHY- Bilateral symmetric T2 and FLAIR hyper intensities are seen involving the parieto-temporo-occipital white matter with sparing of subcortical U fibres, splenium of corpus callosum, posterior internal and external capsules, anterolateral mid brain and scattered in pons. Sagittal post contrast T1 weighted image shows peripheral edge enhancement of the bilateral parietal white matter.

Canavan Disease:

In our study two patients out of 13 cases of leukodystrophies were reported to have Canavan disease. One of our two patients showed diffuse bilateral symmetric cerebral and cerebellar white matter high signal intensities on T2 and FLAIR images and no lobar predominance. Another patient showed involvement of bilateral deep gray matter and subcortical U fibres. Both the patients were subjected to MR spectroscopy study which revealed and marked rise in the N-acetyl aspartate (NAA) peak.

Steven J. Michel and Curtis A. Given II¹¹ reported a case of Canavan disease in which there was diffuse, bilateral, and symmetric increased T2 signal intensity throughout the cerebral white matter. These findings were noted to a lesser degree in the cerebellar white matter, thalamus, globipallidi, and dorsal brainstem. The white matter abnormality specifically involved the subcortical white matter. There was no lobar predominance of white matter abnormalities. Single- voxel point-resolved spatially localized MR spectroscopy revealed a marked increase in both the N-acetyl aspartate (NAA) peak and the ratio of NAA to creatinine. The choline peak was not elevated. Our MR findings are in correlation with their study.

Our findings are in correlation with a study performed by CihadHamidi et al¹² on Canavan disease who reported that Symmetric white matter hyper intensities at T2 weighted brain MRI images with particular involvement of subcortical U fibers, Globus pallidi, internal and external capsules, thalami and both dentate nuclei also affected. Short period (144msn) single voxel spectroscopy depicting markedly elevated NAA peak at the left centrum semiovale. NAA-to-choline ratio and the NAA-to creatinine ratio were markedly increased, findings highly suggestive for Canavan disease.

Also called as spongy degeneration of the cerebral white matter, it is an autosomal recessive disease seen in children of Ashkenazi Jewish descent characterized by deficiency of N-aspartocyclase and resultant accumulation of N-acetyl aspartate. The brain is abnormally enlarged and definitive diagnosis is by brain biopsy which shows characteristic spongy appearance which is most prominent in the subcortical whitematter.

MR appearance is that of megalencephaly with diffuse and symmetrically increased signal seen throughout the white matter on T2-weighted images and relative sparing of the internal capsules. The demyelination is known to begin in the subcortical arcuate fibres. The putamen retain a dark signal with the globus pallidus more commonly affected. Cerebral atrophy is a late finding in Canavan's disease.

Marks HG et al¹³ suggested that MR spectroscopy by measurement of NAA is particularly useful to confirm the diagnosis in suspected cases of Canavan's disease.

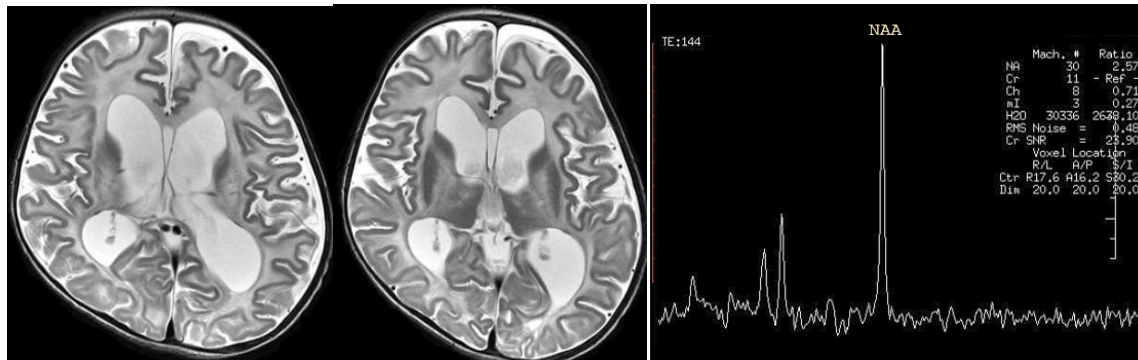


FIG 3 (a,b,c) :CANAVAN DISEASE- Axial T2 weighted image shows high signal in white matter typically a diffuse bilateral involvement of sub cortical U fibres. MR spectroscopy - markedly elevated NAA and NAA:creatine ratio

Krabbes Disease:

We reported one case of Krabbes Disease in our study. Our patient showed both supratentorial and infratentorial lesions predominantly bilateral lesions in the parietal lobes, occipital lobes, deep gray matter and cerebellar white matter. Basal ganglia and thalami were hyperintense on T1 W and hypointense on T2W images. MR spectroscopy revealed choline and myo-Inositol peaks.

This is in correlation with the study done by SB Grover et al¹⁴, who reported a case of Krabbe's disease. They found that the abnormalities on CT and MR occur in basal ganglia, cerebellum and white matter. On MR imaging, basal ganglia and thalami were hyperintense on T1 W and hypointense on T2W images. The periventricular and cerebellar white matter showed hyperintensities on T2W FLAIR images. The clinical and neuroimaging findings were consistent with infantile Krabbe's disease.

In a study by Laura Farina et al¹⁵ it is described that MR imaging shows progressive atrophy and diffuse abnormalities of the white matter, which may be difficult to recognize at a very early age, when the white matter is still normally hyperintense on T2-weighted images. CT studies may be more helpful, because they may show hyperdense areas in the thalami or in the posterior periventricular regions that likely correspond to the clusters of globoid cells in which the galactosylceramide accumulates; calcium deposits may contribute to the hyperdensity. In conclusion, therefore, Krabbe's disease should be considered in the diagnosis of early onset infantile seizures and in older children with spasticity and ataxia. Characteristic CT and MR imaging features help to clinch the diagnosis.

A recent review of MR imaging studies in 22 patients with Krabbe disease Loes DJ et al¹⁶ showed that in early-onset cases there is a frequent involvement of deep gray matter and cerebellar white matter, and nearly constant involvement of the pyramidal tract.

Also known as globoid cell leukodystrophy, it is an autosomal recessive leukodystrophy caused by deficiency of galactosylceramide beta-galactosidase. Krabbe's disease has a predictable neurologic deterioration that is less variable than the other leukodystrophies. In contrast to classic early infantile type which presents with irritability, intermittent fever, delayed development and bulbar signs, late onset variants have also been reported presenting with visual dysfunction and gait disturbances.¹⁷ Definitive diagnosis is by the assay of beta galactosidase in the white blood cells or skin fibroblasts.

MR reveals central to peripheral demyelinating pattern. The thalamus, lateral geniculate body and dentate nuclei show paramagnetic effect characterized by short T1 and T2 early in the course of disease. Later increased signal intensity is seen in deep cerebral and cerebellar white matter, the parietal lobes being particularly affected. The peripheral white matter is spared early in the course of the disease.

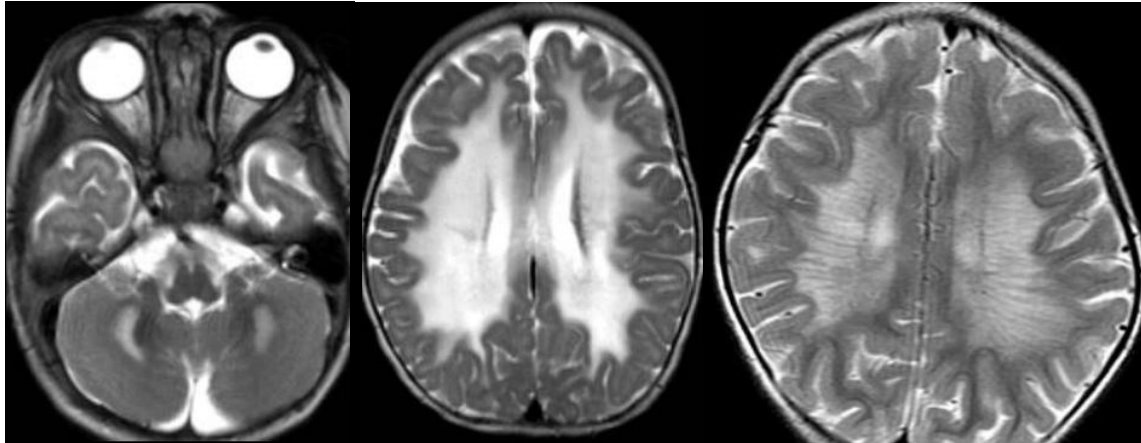


FIG 4 (a,b,c):KRABBES DISEASE- Axial T2 weighted images show bilateral parietal, occipital, deep gray matter and cerebellar white matter hyperintensities with spared subcortical white matter.

Alexander Disease:

Our study revealed one male patient of 2 years of age found to be a case of alexander disease. MR imaging study of this patient showed hyperintensities on T2 weighted images predominantly in the frontal white matter with extension into the parietal and temporal white matter, periventricular regions and subcortical U fibres. The lesions show contrast enhancement. MR spectroscopy revealed a rise in Lactate peak.

In a study by Marjo S. van der Knaap et al¹⁸ Five MR imaging criteria were defined: extensive cerebral white matter changes with frontal predominance, a periventricular rim with high signal on T1-weighted images and low signal on T2-weighted images, abnormalities of basal ganglia and thalami, brain stem abnormalities, and contrast enhancement of particular gray and white matter structures. Four of the five criteria had to be met for an MR imaging-based diagnosis. Our study meets four criteria mentioned in their study, thus correlating with the study

It is a rare disorder unusual for leukodystrophies in that it occurs sporadically without a familial incidence. Less than fifty histologically proven cases have been reported in the world literature.¹⁹

The disease is characterized by macrocephaly, frequently associated with hydrocephalus, diffuse loss of myelin, an extensive proliferation of reactive astrocytes and formation of Rosenthal fibres which are predominantly seen in the perivascular, subependymal and subpial regions. The presentation may be in the infantile, juvenile or adult forms. Infant develops with developmental delay, macrocephaly, spasticity and seizures.

CT and MR appearance is that of an evolving course of demyelination which shows anterior to posterior progression with generalized gray and white matter atrophy. The frontal white matter is usually involved early and more severely than the peritrial white matter. In the late stage, MR picture is that of hyperintensity involving any portion of white matter including the internal capsule (which is usually spared in Canavan's disease).

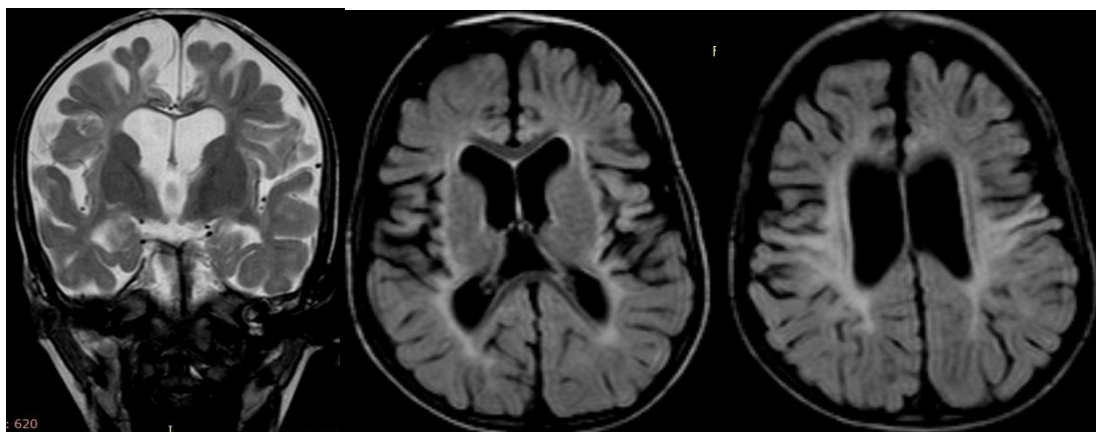


FIG 5 (a,b,c): ALEXANDER DISEASE- Axial T2 and FLAIR cortical hyperintensities are seen in bilateral high frontal lobe and also in posterior periventricular white matter.

Nonspecific Leukodystrophy:

In our study we encountered one case of nonspecific leukodystrophy. The imaging findings of this patient include megalencephaly with hyperintensities on T2 and FLAIR images in bilateral temporal lobes with cystic lesions along with involvement of subcortical U fibres.

de Santos-Moreno MT et al²⁰ conducted a study and found that the patterns of MR has permitted isolation of two new clinical conditions of the nonspecific leukodystrophies group: leukodystrophy with megalencephaly and temporal cysts (Van der Knaap, 1995) for which currently the term vacuolizing leukoencephalopathies with megalencephaly is preferred and the CASH syndrome (childhood ataxia with central hypo myelination or vanishing white matter disease) (Van der Knaap, 1997). They presented a review of nine cases of nonspecific leukodystrophies with an average course of 13 years. They were studied using the protocol of the European working party on demyelinating diseases. One of these fulfilled clinical and radiological criteria for the diagnosis of vacuolizing leukoencephalopathies with megalencephaly: onset in early childhood, macrocephaly, normal metabolic studies, moderate progression and alteration of the white matter signal which was bilateral, symmetrical and diffuse with the presence of oedema and temporal subcortical cysts. Our study meets the above criteria to be concluded as nonspecific leukodystrophy.

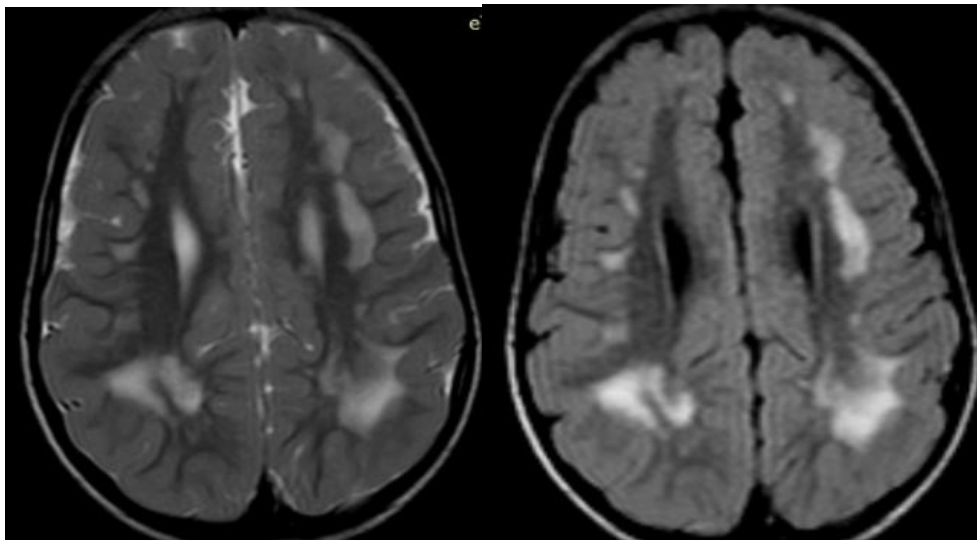


FIG 6 (a, b): NONSPECIFIC LEUKODYSTROPHY - Axial T2 and FLAIR images show bilateral subcortical cerebral white matter hyperintensities.

Multiple Sclerosis:

In our study we had four patients suffering from multiple sclerosis all of which are in the age group of 15-24 years and three female and one male patient.

MR imaging findings include all patients showing bilateral periventricular hyperintensities on T2 weighted and FLAIR images. Deep grey matter hyperintensities were also identified in all patients. One patient showed hyperintense lesions in bilateral frontal, parietal and occipital lobes, each lesion measuring approximately 5-10 mm in size.

The currently most commonly used diagnostic MRI criteria for multiple sclerosis are those by Paty et al. (1988)²¹, which were established in a prospective study. Authors defined MRI criteria for multiple sclerosis as by 4 or more lesions, or 3 lesions of which 1 is periventricular. Our results confirm that those criteria are quite sensitive.

In a study by Tas et al., 1995²² showed that gadolinium-enhancement was more specific for diagnosing multiple sclerosis than abnormalities revealed on T2-weighted imaging.

In a study of 42 patients by Frederik Barkhof et al,²³ gadolinium-enhancement was identified as the most predictive MRI parameter. Authors have mentioned the diagnostic criteria of MS on MRI such as periventricular lesions, 9 or more T2 lesions. When taken as a cut off point enhancement of at least 1 lesion on post Gd T1W images, it is seen positive in 28 patients with a sensitivity of 61%, specificity of 80% and accuracy of 72%. When compared these results with our study where we have found similar diagnostic criteria for MS on MRI such as 9 or more T2 hyperintense lesions, periventricular lesions and gadolinium enhancement in all the 4 patients of our study who were clinically suspected strongly for Multiple sclerosis. Thus our study results with a high accuracy rate of 100% correlate with these studies.

Multiple sclerosis is the most common and extensively studied of all the demyelinating diseases. The exact etiology is unknown but is thought to be due to autoimmune mediated demyelination in genetically susceptible individuals.²⁴

The vast majority of MS cases are categorized into the classic form or Charcot type, the other variants being Marburg type, Schilder, Balo type or Devic type. Most patients present in the third and fourth decades of life with a definite female preponderance. The patient presents with impaired or double vision, weakness, numbness and gait disturbance, the first clinical symptom being impaired or double vision. Spinal fluid analysis shows alteration to oligoclonal bands myelin basic protein and immunoglobulin. Cognitive impairment may be noted in long standing cases. Phillip M. et al²⁵ in his study suggested that the subcortical lesions particularly its extent are responsible for causing cognitive impairment.

On MR, there is a distinct propensity for the lesions to occur in certain regions of white matter like periventricular white matter optic nerves brain stem and spinal cord. About 50% occur in a periventricular distribution predominantly near the angles of the lateral ventricles and is seen anatomically related to subependymal veins. This perivascular demyelination called Dawson's fingers is quite specific for MS. Multiple focal periventricular lesions with small size (almost always less than 2.5 cm) and irregular outline with a lumpy-bumpy appearance is characteristic for MS.²⁶ The periaqueductal region and floor of 4th ventricle are also frequently affected.

The corpus callosum is a region which is especially sensitive to demyelination with MS, possibly due to its intimate neuroanatomical relationships to the lateral ventricular roof and its relationship to small penetrating vessels. Even though long TR images typically show focal corpus callosal lesions to best advantage, the anatomic distortion with focal thinning in its inferior aspect is better identified on sagittal views.

On contrast administration, ring or solid type of enhancement is seen Gadolinium enhancement and significant mass effect suggests active demyelination. Treatment with steroids will be associated with a marked reduction of lesion morphology and enhancement. Contrast enhancement may add to the specificity of multiple hyperintensities on T2-weighted images since the finding of enhancing along with non enhancing lesions is quite common in MS. Similarly, the temporal changes in enhancing and non-enhancing lesions common in MS cases is very different from other entities.

Decreased T2 signal in the thalamus and putamen is seen in advanced MS owing to the increased iron deposition. The chronic progressive pattern typically has more severe spinal cord involvement. Wallerian degeneration is a relatively rare and unusual finding seen in Schilder variant and established cases of MS. It is not typically associated with early MS.

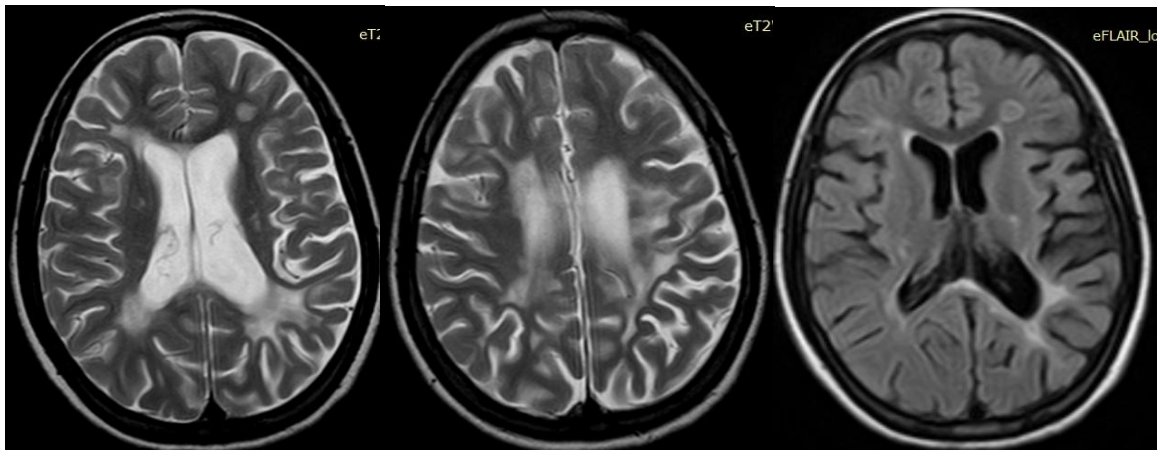


FIG 7 (a,b,c) : **MULTIPLE SCLEROSIS**- Axial T2 and FLAIR periventricular hyperintensity is seen involving bilateral periventricular white matter, internal capsules and splenium of corpus callosum.

Leigh's Disease:

We had two cases of Leigh's disease in our study aged 1-2 years showing hyperintensities on T2 weighted and FLAIR images involving deep grey matter and brainstem.

According to study done by LeenaValanneet al²⁷, typical imaging findings are the diagnostic hallmark of Leigh syndrome, which explains the uniformity of the MR findings. The diagnosis of Leigh syndrome, which earlier could be made only by post-mortem examination, is characterized by vascular proliferation and demyelination, which lead to necrosis and cavitation in typical locations, including the basal ganglia, midbrain, pons, and posterior column of the spinal cord. MR lesions in

corresponding locations therefore strongly suggest the presence of a defect in the energy-producing pathway. Putaminal involvement is reported to be a consistent feature in Leigh syndrome. Hence our findings are in correlation with this study.

Leigh disease, or sub acute necrotizing encephalomyelopathy, is an inherited, progressive, neurodegenerative disease of infancy or early childhood with variable course and prognosis. Affected infants and children typically present with hypotonia and psychomotor deterioration. Ataxia, ophthalmoplegia, ptosis, dystonia, and swallowing difficulties inevitably ensue. Characteristic pathologic abnormalities include micro-cystic cavitation, vascular proliferation, neuronal loss, and demyelination of the midbrain, basal ganglia, and cerebellar dentate nuclei and, occasionally, of the cerebral white matter.

Typical MR imaging findings include symmetric putaminal involvement, which may be associated with abnormalities of the caudate nuclei, globus pallidi, thalami, and brainstem and, less frequently, of the cerebral cortex. The cerebral white matter is rarely affected. Enhancement may be seen at MR imaging and may correspond to the onset of acute necrosis.²⁸

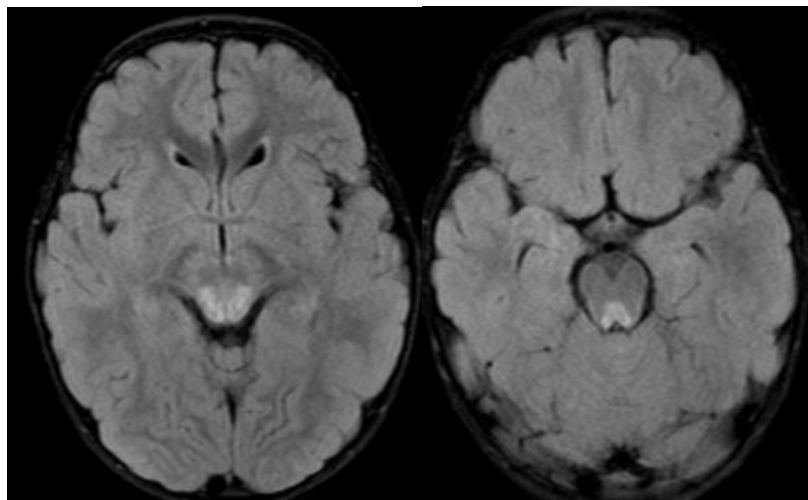


FIG 8 (a, b): LEIGHS DISEASE - Axial FLAIR images show hyperintense lesions in midbrain and pons posteriorly.

HIV Encephalopathy:

Two patients suffering from Human Immunodeficiency Virus Encephalopathy aged about 40-42 years, one male and one female, were subjected to MR imaging under our study group. Findings were diffuse, multifocal and nonspecific in both patients showing T2 and FLAIR hyperintensities involving bilateral cerebral and cerebellar hemispheres including deep grey matter. In a study by McArthur *et al*²⁹, of 149 patients, focal hyperintensities in the white matter were observed in 67% of those with AIDS.

Human retroviruses like HIV are known to cause white matter changes which may be difficult to assess subjectively especially in the early stages of the disease. HIV encephalopathy is a progressive subcortical dementia that is a form of sub-acute encephalitis. The most common neurological manifestation would be sub-acute encephalopathy presenting as dementia and global cognitive impairment. Though CT and MRI are relatively insensitive in detecting microglial nodules early in the course of the disease, they are very sensitive in the detection of secondary parenchymal changes.³⁰

Clinical and radiological studies have shown a major contribution of basal ganglia dysfunction in the pathogenesis of HIV dementia.³¹

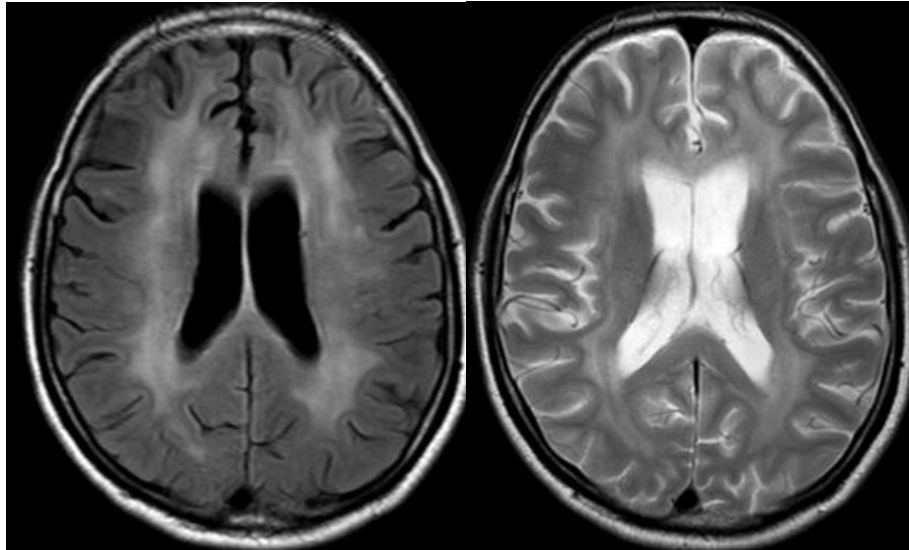


FIG 9 (a, b): HIV ENCEPHALOPATHY- Axial FLAIR and T2 weighted images show diffuse multifocal nonspecific hyperintensities in bilateral cerebral hemispheres.

Progressive Multifocal Leukoencephalopathy :

One case of Progressive Multifocal Leukoencephalopathy was encountered in our study. The patient was 33 year old male patient with HIV seropositive status. MR imaging findings revealed multifocal bilateral parietal, occipital, periventricular, subcortical U fibres, deep gray matter and bilateral cerebellar white matter hyperintensities on T2 weighted and FLAIR images.

Humera Ahsan et al³² reported, in their study, that One male patient suffered from Progressive Multifocal Leukoencephalopathy. He was 30 years old and tested positive for Human Immunodeficiency Virus (HIV). MRI showed abnormal signal intensity in deep white matter of brain in right frontal regions, parietooccipital regions, putamen and midbrain. The signals were isointense on T1 and hyperintense on T2 weighed images. It is observed that these findings are in correlation with our study.

It is probably the best known virally induced demyelinating disease. It is caused by reactivation of a latent Papova virus (the JC virus) infection. Though generally seen in immune compromised patients, it is found to have a strong association with AIDS.³³

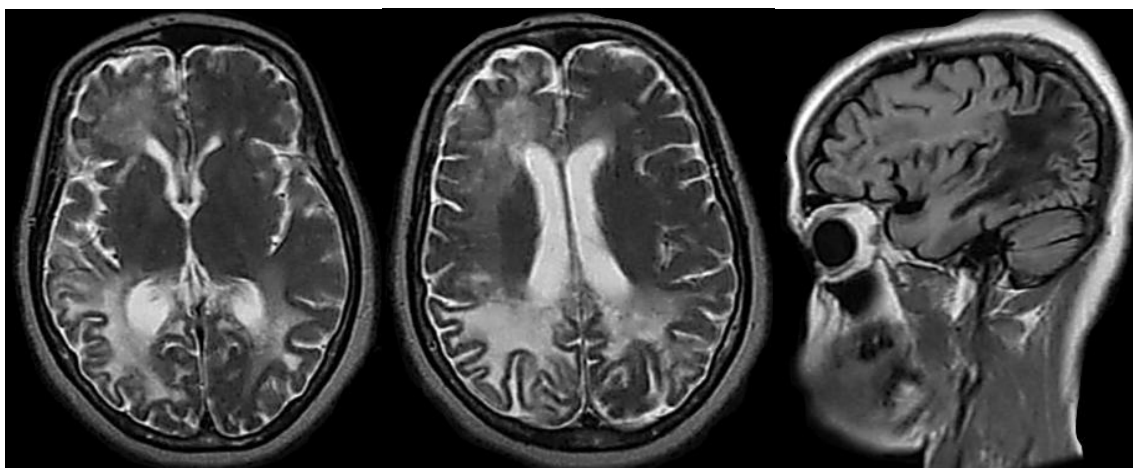


FIG 10 (a,b,c,d)PROGRESSIVE MULTIFOCAL LEUCOENCEPHALOPATHY- Axial T2 weighted images show multifocal bilateral parietal, occipital, periventricular, subcortical U fibres, deep gray matter hyperintensities. Sagittal T1 weighted image shows posterior hypointensities. Coronal T2 weighted image shows occipital and bilateral cerebellar white matter involvement.

Acute Disseminated Encephalomyelitis:

In our study seven patients suffering from Acute Disseminated Encephalomyelitis were obtained among which four were females and three were male patients ranging from 2 – 16 years of age.

MR findings included hyperintense lesions involving bilateral frontal (75%), parietal (62.5%), temporal (50%), occipital (25%), deep grey matter (12.5%), periventricular region (37.5%), subcortical U fibres (50%), cerebellar white matter (50%) and brain stem involvement (50%). Three patients were subjected to contrast study out of which two patients showed contrast enhancement (66.67%). Two patients also showed features of edema. MR spectroscopy done in one patient showed rise in the level of choline peak.

Nathan P. Young et al³⁴ stated that ADEM is more frequent in children.

Mikealoff et al³⁵ reported in their study that 66% of their patients suffering from acute disseminated encephalomyelitis showed juxtacortical hyperintensities on MR imaging. Marchioniet al³⁶ in their study reported that 42% of their patients with ADEM showed gadolinium enhancement whereas Lin et al⁸⁹ reported that 40 % of their patients suffering from ADEM showed gadolinium enhancement. These findings are in correlation with our study.

Menor F et al³⁷ opined that T2 prolongation in deep gray matter, specially thalamic involvement is a useful distinguishing feature of ADEM over MS. Moreover ADEM being a monophasic disease, lesional enhancement will be homogenous and new lesions would not be expected to occur in serial MRI. Though ADEM lesions are typically bilateral and asymmetric, occasionally it can present as large, symmetrical and confluent periventricular hyperintensities with only mild mass effect as compared to the expected size of the lesion.

ADEM is an immune mediated demyelination which is typically seen 5 days to 2 weeks following a viral illness (measles, varicella, rubella and Epstein-Barr viruses) or immunization and resemble primary viral encephalitis clinically headache, fever and drowsiness are the initial symptoms which progresses to seizure. On MRI, the lesions of ADEM are identical to that of MS. Most ADEM lesions are located in the subcortical white matter with asymmetric involvement of both hemispheres with or without brain stem involvement. Though it predominantly involves the white matter, it may affect the gray matter as well.³⁸ and focal neurological deficits.

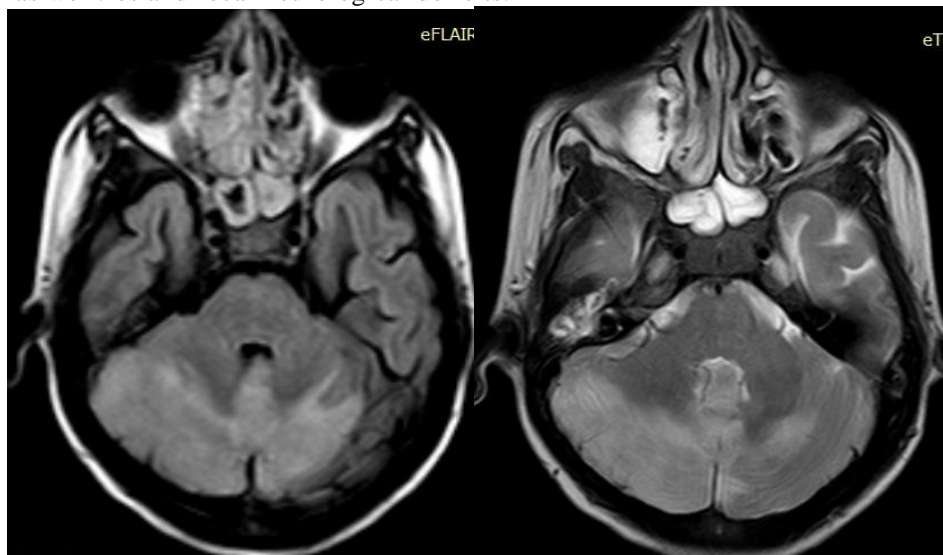


FIG 11 (a, b): Acute Disseminated Encephalomyelitis- Diffuse ill defined abnormal signal intensities are seen predominantly involving the cortices of both cerebellar hemispheres (R> L) and cerebellar vermis, appearing homogeneously hyperintense on T2 and FLAIR, hypointense on T1WI. There is minimal mass effect seen in the form of effacement of the involved sulci.

Small Vessel Ischemic Changes:

In our study we observed in 4 elderly patients that there were white matter punctate and confluent hyperintensities on T2 and FLAIR images involving supratentorial and infratentorial brain white matter (periventricular region in 75%, subcortical U fibres in 50%, frontal, parietal, temporal, occipital and brainstem hyperintensities in 25% of the patients). All patients ranged from 61 to 82 years, 50% male and 50% female. The lesions were attributed to degenerative changes of small vessels.

Fazekas F, et al³⁸ conducted a study on histopathological changes associated with incidental white matter signal hyperintensities on MRIs from 11 elderly patients (age range, 52 to 82 years) to a descriptive classification for such abnormalities. Punctate, early confluent, and confluent white matter hyperintensities corresponded to increasing severity of ischemic tissue damage, ranging from mild perivascular alterations to large areas with variable loss of fibres, multiple small cavitations, and marked arteriolosclerosis. Microcystic infarcts and patchy rarefaction of myelin were also characteristic for irregular periventricular high signal intensity. This is in correlation with our study

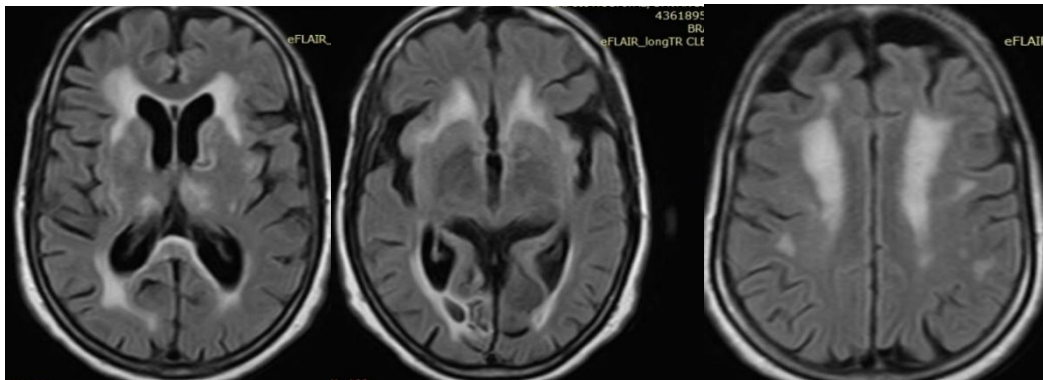


FIG 12 (a,b,c):Small Vessel Ischemic Changes - Multiple confluent and discrete T2 and FLAIR hyperintense lesions are seen in bilateral periventricular white matter, bilateral thalami and in the brain stem (pons) with significant white matter volume loss.

Hypomyelination:

Six patients in our study group showed hypomyelination all of which belonged to the age group from one to four years. All patients showed uniform white matter hyperintensities in the periventricular regions. Contrast was administered for one patient, which showed no enhancement on T1 weighted post contrast images.

Hypomyelination refers to a permanent, substantial deficit in myelin deposition in the brain.

Marjan E. Steenweg et al³⁹ in a study of 128 patients retrospectively with hypomyelination noted that the T1 and T2 signals of the white matter during normal myelination and in hypomyelination differ from those observed in demyelination and other lesions. The T2 hypointensity of the white matter is milder in hypomyelination than in demyelination and other white matter lesions. In demyelination and other lesions the T1 signal is invariably low, much lower than the cortex, whereas the T1 signal is mildly hyperintense, isointense or mildly hypointense relative to the cortex in hypomyelination.

White matter lesions were defined as areas of prominent T2 hyperintensity and prominent T1 hypointensity. A total of 112 patients identified with positive MRI findings for hypomyelination in various hypomyelinating diseases with an accuracy of 87.5%. Atrophy was defined as volume loss leading to enlargement of the ventricles and subarachnoid spaces. Only obvious atrophy was scored as present, equivocal atrophy was scored as absent. In our study we had 6 patients presenting with similar MRI hypomyelinating features with strong clinical suspicion of hypomyelinating diseases. Thus, our study correlates with the above mentioned study with an accuracy of 100%.

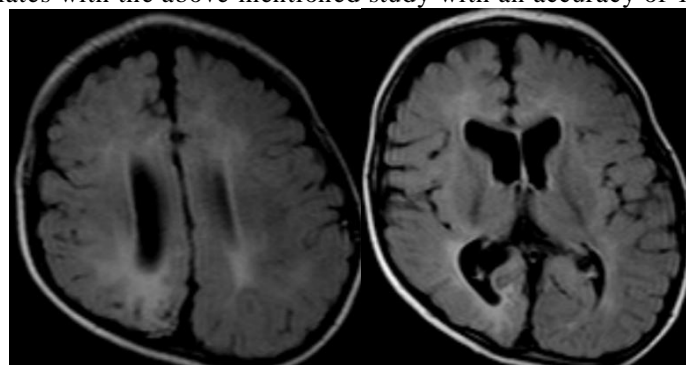


FIG 13 (a,b):Hypomyelination - Axial FLAIR images of supratentorial brain parenchyma shows diffuse atrophic changes seen as evidenced by widening of CSF spaces. Asymmetric bilateral posterior periventricular hyperintensities seen.

Vanishing White Matter Disease:

In our study one male patient of age 4 years clinically suspected of white matter disease underwent MR imaging. The findings were diffuse white matter abnormalities involving the bilateral cerebral white matter including the periventricular regions and subcortical U fibres and cerebellar white matter including the brain stem. Cystic degeneration was noted. MR spectroscopy revealed a rise in the lactate peak.

Eulàlia Turón-Viñas et al⁴⁰ in their study reported that Vanishing white matter disease (VWMD), also known as childhood ataxia with central hypomyelination (CACH), is one of the most prevalent hereditary white matter diseases. It typically appears in a previously healthy child, and it produces a progressive neurological deterioration with some acute exacerbations in reaction to certain stimuli, such as infections, cranial trauma, and acute fright. It can also produce optic atrophy and progressive macrocephaly. The most frequent clinical forms of the disease have their onset during childhood: the early childhood-onset appears before five years of age and the late childhood-onset between ages 5 and 15. MRI images show important diffuse abnormalities of the signal on T1 and T2 of almost all the cerebral white matter, with progressive rarefaction and cystic degeneration that leads to its complete disappearance. MRI features in the above mentioned study is in correlation with our study.

Vanishing white matter disease, also called CACH, is an autosomal recessive disease, due to mutations in all five gene subunits encoding the eukaryotic translation initiation factor eIF2B. This factor is a regulator of translation initiation (i.e., the final step of proteins production, in which mRNA is translated into proteins) under circumstances of mild stress. It has been suggested that an abnormal stress reaction (related to the dysfunction of eIF2B that plays a crucial role in regulating protein synthesis under mild stress conditions) may cause deposition of denaturated proteins within oligodendrocytes leading to hypomyelination, loss of myelin, and subsequent cystic degeneration.⁴¹

Eva-Maria Rataiet al⁴² report that MRI of vanishing white matter disease (VWMD) also has a characteristic pattern. It shows features of confluent cystic degeneration, white matter signal appears CSF-like with progressive loss of white matter over time on proton density and FLAIR images. Regions of relative sparing include the U-fibres, corpus callosum, internal capsule, and the anterior commissure.

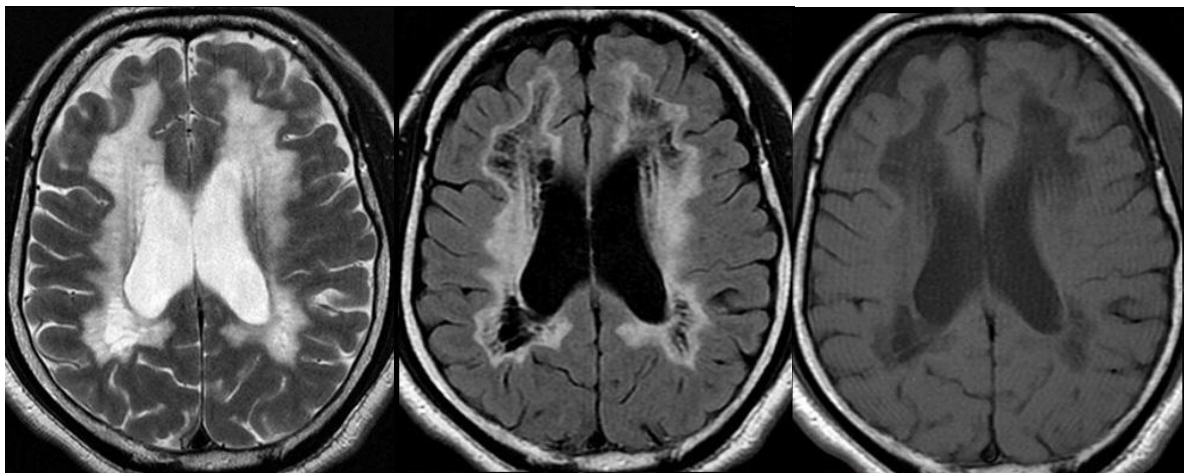


FIG 14 (a,b,c): Vanishing White Matter Disease- Axial T2 weighted image shows diffuse white matter hyperintensity similar to CSF intensity extending from periventricular white matter to the subcortical arcuate fibres. Axial FLAIR image shows white matter vanished and replaced by near-CSF intensity fluid i.e., it attenuated. Axial T1 weighted image shows diffuse white matter hypointensity similar to CSF intensity.

Cavitating Leukoencephalopathy:

In our study we encountered one female patient of age 3 years who was clinically suspected of white matter disease. MR imaging in this patient revealed diffuse white matter abnormality in both cerebral hemispheres with involvement of the periventricular and subcortical white matter (up to U fibres). Central cavitations were also noted within involving both basal ganglia. On diffusion-weighted images and corresponding apparent diffusion coefficient map restriction of diffusivity in the abnormal white matter with increased diffusivity in the central cavitations was noted. Sagittal T1-

weighted images show involvement of the corpus callosum with atrophy and central cavitations. Ex-vacuo dilatation of frontal horns of both lateral ventricles are also noted.

Cystic Leukoencephalopathies without megalencephaly was first described by Olivier et al⁴³ in 1998.

In a study by Eliete Chiconelli Faria et al⁴⁴, MRI showed bilateral lesions with signal intensity that is isointense to the one of cerebrospinal fluid in both temporal lobes, compatible with cysts and patchy areas of high signals intensity in the white matter of temporal, frontal and parietal lobes.

Henneke et al. (2005)⁴⁵ reported 15 infants with early onset of severe psychomotor impairment associated with non-progressive encephalopathy. MRI showed bilateral cysts in the anterior temporal lobe and white matter lesions with pericystic abnormal myelination and symmetric lesions in the periventricular regions. MRI findings in the above mentioned studies are in correlation to the findings in the patient of our study

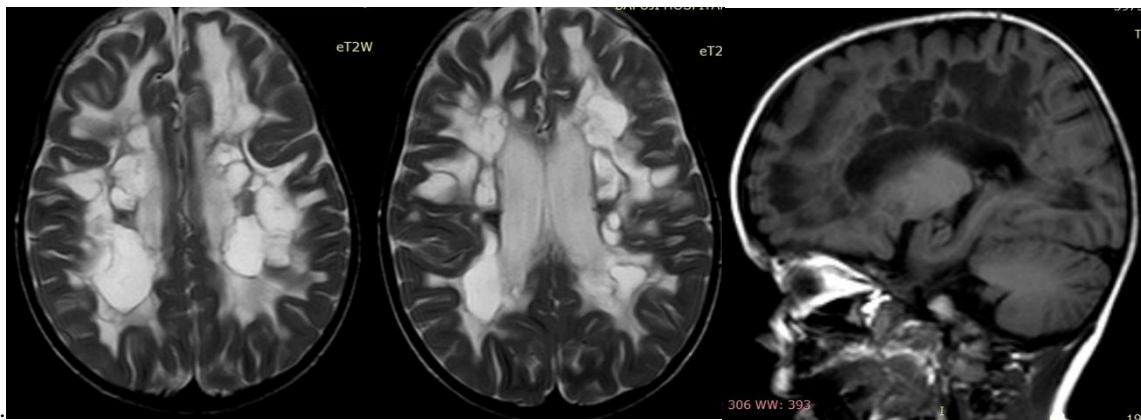


FIG 15 (a,b,c):Cavitating Leukoencephalopathy-Axial T2 and FLAIR images show diffuse white matter abnormality is noted in both cerebral hemispheres with involvement of the periventricular and subcortical white matter (up to U fibres). Central cavitations are also noted within involving both basal ganglia. Sagittal T1-weighted images show involvement of the corpus callosum with atrophy and central cavitations. Ex-vacuo dilatation of frontal horns of both lateral ventricles are also noted.

Periventricular Leukomalacia:

We have reported four cases of periventricular Leukomalacia in our study. The patients belonged to the age group of 18 months to 4 years. 50% were females and 50% were male patients. Two had a history of preterm delivery & asphyxia. On MR imaging, all patients showed periventricular white matter hyperintensities, 75% patients showed white matter hyperintensities in frontal, parietal, temporal and occipital white matter and cystic lesions, 50% patients showed features of edema and 25% patients showed involvement of deep grey matter. Ventriculomegaly was seen in 3 patients and scalloping of ventricular margins.

BN Lakhkaret al⁴⁶ conducted a study in which four cases of periventricular Leukomalacia (PVL) were reported. Two had a history of preterm delivery & asphyxia while the remaining two were full term infants with insult in the prenatal life. The most common clinical presentation was spastic diplegia (cerebral palsy) followed by seizures. MRI showed loss of white matter volume and bilateral symmetrical hyperintensity of the periventricular white matter especially of the periatlial region in all patients. Ventriculomegaly and scalloping of ventricular margins were seen in two patients. They opined that the typical imaging findings include peritrigonal hyperintensities on T2WI, focal ventricular enlargement and irregular, scalloped ventricular contours. White matter volume is reduced and the posterior corpus callosum appears moderately atrophic. These findings are consistent with the MR findings in our study.

It is due to the ischemic infarction of periventricular white matter, the vascular watershed zone in the developing fetus. It is particularly seen in preterm infants and in perinatal asphyxia.⁴⁷The most characteristic presentation is spastic diplegia, a form of cerebral palsy.

Typical imaging findings include peritrigonal hyperintensities on T2-weighted images, focal ventricular enlargement and irregular, scalloped ventricular contours. White matter volume is reduced and the posterior corpus callosum appears moderately atrophic. Though usually bilateral and asymmetric, it can present as multifocal white matter lesions.

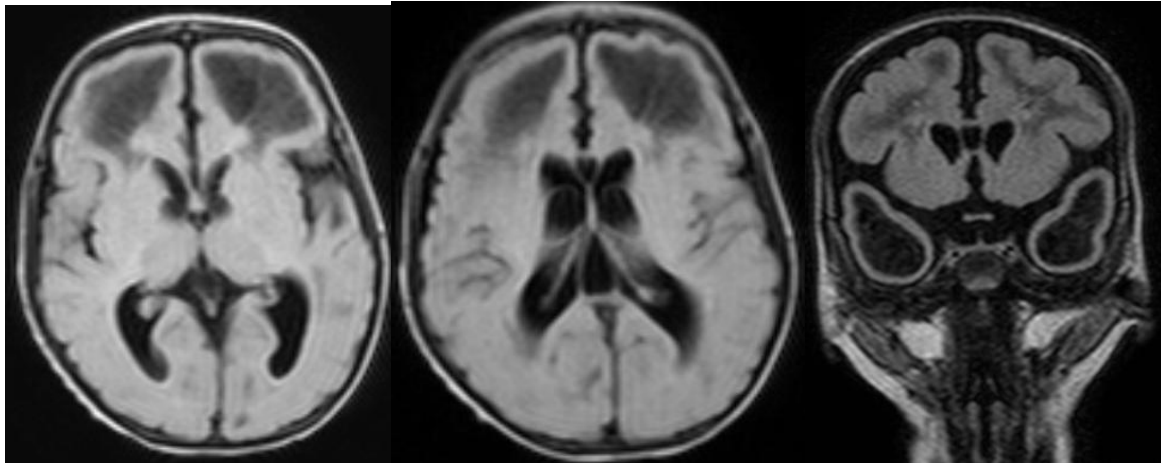


FIG 16(A,B,C):Periventricular Leukomalacia- Axial and coronal FLAIR images show bilateral symmetric periventricular cystic lesions measuring 8-12mm are seen in adjacent to frontal / body of lateral ventricles and also anterior to temporal horns. In addition smaller size lesions are seen in bilateral posterior periventricular white matter. Mild volume loss is seen in bilateral periventricular brain parenchyma.

Megaloencephalic Leukoencephalopathy (Also Known As Van Der Knaap Disease):

In our study we reported two cases of Megaloencephalic Leukoencephalopathy ranging from age 15 months to 3 years, both being male patients. Three year old patients showed white matter hyperintensities in bilateral cerebral white matter with sparing of periventricular regions and involving deep grey matter. Features of edema was seen in this patient as well. 15 month old patients showed white matter hyperintensities in bilateral frontal, parietal and temporal white matter with involvement of subcortical U fibres. Both the patients showed cystic lesions in the temporal lobes.

KV Rajagopale et al⁴⁸ reported a case of Megaloencephalic Leukoencephalopathy, in which they described the MR findings in a 2 year old boy. Findings include extensive bilaterally symmetrical white matter changes, which are hypointense on T1 weighted and hyperintense on T2 weighted and FLAIR images suggestive of extensive demyelination. Additionally, large well defined symmetrical subcortical cysts were noted in anterior temporal lobe and which are hypointense on T1, hyperintense on T2 and suppressed on FLAIR images consistent with a diagnosis of Megaloencephalic Leukoencephalopathy. Thus these findings are in correlation with our study.

Megaloencephalic Leukoencephalopathy (MLC) with subcortical cysts is a rare disease first described by van der Knaap et al, in 1995. Megaloencephalic Leukoencephalopathy with subcortical cysts is a relatively new entity of neurodegenerative disorder characterized by infantile onset macrocephaly, cerebral Leukoencephalopathies and mild neurological symptoms and an extremely slow course of functional deterioration. Megaloencephalic Leukoencephalopathy with subcortical cysts is a rare disease with autosomal recessive inheritance. In typical cases, the MR findings are often diagnostic of MLC. MR shows 'swollen white matter' and diffuse supratentorial symmetrical white matter changes in the cerebral hemispheres with relative sparing of central white matter structures like the corpus callosum, internal capsule, and brain stem. Subcortical cysts are almost always present in the anterior temporal region and are also frequently noted in frontoparietal region. Grey matter is usually spared. Gradually the white matter swelling decreases and cerebral atrophy may ensue. The subcortical cysts may increase in size and number.⁴⁸

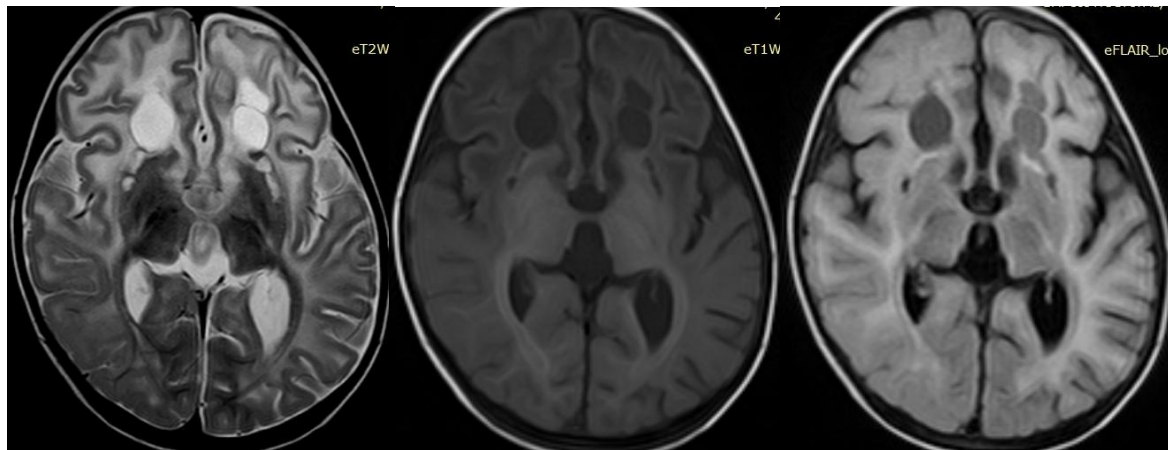


FIG 17 (a,b,c):MEGALOENCEPHALIC LEUKOENCEPHALOPATHY - Axial T2, T1 and FLAIR images show diffuse swelling and T2 hyperintensity of bilateral cerebral white matter and posterior internal capsule is seen. Large subcortical cysts are seen in bilateral frontal lobes measuring 11- 13 mm. in addition small subcentimeter cysts are seen in bilateral caudate and lentiform nuclei.

VII. Conclusion

MRI has allowed for much progress in the field of white matter diseases. Prior to arrival of MRI, the specific vulnerability of brain white matter was not well understood. Today, MRI has helped define disorders through the recognition of specific lesion patterns and their evolution over time. This has also led to identification of novel leukodystrophies and the genes underlying these disorders. Even in previously well characterized disorders, MRI patterns have shed light on disease mechanisms. The understanding of the pathology and molecular basis of leukodystrophies has in turn allowed for new insight into the significance of MRI changes and elucidated the capabilities of MR techniques. Brain MRI today is a valuable tool in monitoring disease progression and the success of therapeutic interventions in white matter diseases. Advances in new techniques encourage a multimodal approach employing a variety of sequences sensitive to different brain tissue characteristics. Together, these techniques will be able to provide clues to the early stages of disease – insight not gained by pathology in the past.

VIII. References

- [1]. Barkovich AJ, Lyon G, Evrard P. Formation, maturation and disorders of white matter. *AJNR* 1992;13:447-461.
- [2]. Alves D, Pires MM, Guimaraes A, Miranada MC. Four cases of late onset metachromatic leukodystrophy in a family, clinical, biochemical and neuropathological studies. *J Neurol Neurosurg Psychiatry* 1986;14:17-1422.
- [3]. Kim TS, Kim IO, Kim WS, Choi YS, Lee JY, Kim OK, et al. MR of childhood metachromatic leukodystrophy. *AJNR* 1997 Apr;18:733-738.
- [4]. Ahsan H, Rafique MZ, Ajmal F, Wahid M, Azeemuddin M, Iqbal F. Magnetic resonance imaging (MRI) findings in white matter disease of brain. *J Pak Med Assoc* 2008 Feb;58(2):86-88.
- [5]. Alves D, Pires MM, Guimaraes A, Miranada MC. Four cases of late onset metachromatic leukodystrophy in a family, clinical, biochemical and neuropathological studies. *J Neurol Neurosurg Psychiatry* 1986;14:17-1422.
- [6]. Snyder RD, King JN, Keck GM, Orrison WW. MR imaging of the spinal cord in 23 subjects with ALD-AMN complex. *AJR* 1992;158:413-416.
- [7]. Barkovich AJ, Ferriero DM, Bass N, Boyer R. Involvement of the pontomedullary corticospinal tracts : a useful finding in the diagnosis of X-linked adrenoleukodystrophy. *Am J Neuroradiol* 1997;18:95-100.
- [8]. van der Knapp MS, Valk J. The MR spectrum of peroxisomal disorders. *Neuroradiology* 1991;33:30-37.
- [9]. Melhem ER, Loes DJ, Georgiades CS, Raymond GV, Moser HW. X-linked adrenoleukodystrophy : The role of contrast-enhanced MR imaging in predicting disease progression. *Am J Neuroradiol* 2000 May;21:839-844.
- [10]. Naidu S, Moser HW. Peroxisomal disorders. *Neurologic Clinics* 1990;8(3):507-525.
- [11]. Michel SJ, Given CA. Case 99 :Canavan disease. *Radiology* 2006;241:310-314.
- [12]. Hamidi C, Adin E, Goya C, Ekici F, Onder H, Hattapoglu S. Finding Canavan disease, and diagnostic hallmark MR- Spectroscopy. *IJBCS* 2012;1(II):75-79.
- [13]. Marks HG, Caro PA, Wang ZY, Detre JA, Boqden AR, Gusnard DA, et al. Use of computed tomography, Magnetic resonance imaging and localized magnetic resonance spectroscopy in Canavan's disease. A case report. *Ann Neurol* 1991;30(1):106-110.
- [14]. Grover SB, Gupta P, Jain M, Kumar A, Gulati P. Characteristic CT and MR features of Krabbe's disease : A case report. *Indian J Radiol Imag* 2005;15(4):503-506.
- [15]. Farina L, Bizzi A, Finocchiaro G, Pareyson D, Sghirlanzoni A, Bertagnolio B, et al. MR imaging and proton MR spectroscopy in adult Krabbe disease. *AJNR* 2000 Sept;21:1478-1482.
- [16]. Loes DJ, Peters C, Krivit W. Globoid cell leukodystrophy : distinguishing early – onset from late onset disease using a brain MR imaging scoring method. *AJNR* 1999;20:316-323.
- [17]. Arvidsson J, Hagberg B, Mansson JE, Svennerholm L. Late onset globoid cell leukodystrophy – Swedish case with 15 years of follow up. *Acta Paediatr* 1995;84(1):218-221.
- [18]. van der Knaap MS, Naidu S, Steven N, Breiter, Blaser S, Stroink H, et al. Alexander disease : diagnosis with MR imaging. *AJNR* 2001 Mar;22:541-552.

- [19]. Tatke M, Sharma A. Alexander's disease. A case report of a biopsy proven case. *Neurology India* 1999;47:333-335.
- [20]. De Santos-Moreno MT, Campos-Castello J. Non-specific leukodystrophy. A new case of vacuolizing leukoencephalopathy with megalencephaly. *Rev Neurol*. 2002;34(1):19-27.
- [21]. Paty DW, Oger JF, Kastrukoff LF, Hashimoto SA, Hooge JP, Eisen AA, et al. MRI in the diagnosis of MS : a prospective study with comparison of clinical evaluation, evoked potentials, oligoclonal banding and CT neurology 1988;38:180-5.
- [22]. Tas MW, Barkhof F, van Walderveen MAA, Polman CH, Hommes OR, Valk J. The effect of gadolinium on the sensitivity and specificity of MR in the initial diagnosis of multiple sclerosis. *AJNR* 1995;16:259-64.
- [23]. Barkhof F, Filippi M, Miller DH, Scheltens P, Campi A, Polman CH, et al. Comparison of MRI criteria at first presentation to predict conversion to clinically definite multiple sclerosis. *Brain* (1997), 120, 2059-2069.
- [24]. Niebler G, Harris T, Davis T, Raos K. Fulminant multiple sclerosis. *AJNR* 1992;13:1547-1551.
- [25]. Filippi M, Tortorella C, Rovaris M, Bozzali M, Possa F, Sormani MP, et al. Changes in the normal appearing brain tissue and cognitive impairment in MS. *J NeurolNeurosurg Psychiatry* 2000;68:157-161.
- [26]. Wallace CJ, Seland TP, Forig TC. Multiple sclerosis : The impact of MR imaging. *AJR* 1992;158:849-857.
- [27]. Valanne L, Ketonen L, Majander A, Suomalainen A, Pihko H. Neuroradiologic findings in children with mitochondrial disorders. *AJNR* 1998 Feb;19:369-377.
- [28]. Cheon JE, Kim IO, Hwang YS, Kim KF, Wang KC, Cho BK, Chi JG, et al. Leukodystrophy in children : A pictorial review of MR imaging features. *Radiographics* 2002;22:461-476.
- [29]. McArthur JC, Kumar AJ, Johnson DW, Selnes OA, Becker JT, Cohen BA, Saah A. Incidental white matter hyperintensities on magnetic resonance imaging in HIV-1 infection. Multicenter AIDS Cohort Study. *J Acquir Immune Defic Syndr* 1990;3(3):252-259
- [30]. Post MJD, Tate LG, Quencer RM, Hensley GT, Berger JR, Sheremata WA, et al. CT, MR and pathology in HIV encephalitis and meningitis. *AJR* 1988;151:373-380.
- [31]. Berger JR, Nath A, Greenberg RN, Andersen AH, Greens RA, Bognar A, et al. Cerebrovascular changes in the basal ganglia with HIV dementia. *Neurology* 2000;54:921-926
- [32]. Ahsan H, Rafique MZ, Ajmal F, Wahid M, Azeemuddin M, Iqbal F. Magnetic resonance imaging (MRI) findings in white matter disease of brain. *J Pak Med Assoc* 2008 Feb;58(2):86-88
- [33]. Krupp LB, Lipton RB, Swerdlow ML. Progressive multifocal leukoencephalopathy : Clinical and radiographic features. *Ann Neurol* 1985;17:344-349
- [34]. Young NP, Weinschenker BG, Lucchinetti CF. Acute disseminated encephalomyelitis : Current understanding and controversies. *Semin Neurol* 2008 Feb;28(1):84-94.
- [35]. Mikaeloff Y, Caridade G, Husson B, Suissa S, Tardieu M. Acute disseminated encephalomyelitis cohort study : prognostic factors for relapse. *Eur J Paediatr Neurol* 2007;11(2):90-95.
- [36]. Marchioni E, Ravaglia S, Piccolo G, et al. Postinfectious inflammatory disorders : subgroups based on prospective follow up. *Neurology* 2005;65(7):1057-1065.
- [37]. Menor F. Demyelinating diseases in childhood : Diagnostic contribution of magnetic resonance. *Rev Neurol* 1997;25(142):966-969.
- [38]. Fazekas F, Offenbacher H, Fuchs S. Criteria for an increased specificity of MRI interpretation in elderly subjects with suspected multiple sclerosis. *Neurology* 1988;38:1822-1825.
- [39]. Steenweg ME, Vanderver A, Blaser S, et al. Magnetic resonance imaging pattern recognition in hypomyelinating disorders. *Brain* 2010;133(1):2971-2982
- [40]. Turon-Vinas, Pineda M, Cusi V, Lopez-Laso E, et al. Vanishing white matter disease in a Spanish population. *J Central Nervous System Disease* 2014;6:59-68.
- [41]. Maja Di Rocco, Biancheri R, Rossi A, Filocamo M, Tortori-Donati P. Genetic disorders affecting white matter in the pediatric age. *Am J Med Genetics Part B (Neuropsychiatric Genetics)* 2004;129B:85-93.
- [42]. Eva-Maria Ratai, Paul Caruso, Florian Eichler. *Advances in MR imaging of leukodystrophies. Neuroimaging – Clinical Applications*, Peter Bright (Ed.). ISBN : 978-953-51-0200-7.
- [43]. Olivier M, Lenard HG, Aksu F, Gartner J. A new leukoencephalopathy with bilateral anterior temporal lobe cysts. *Neuropediatrics* 1998;29:225-228.
- [44]. Faria EC, Arita JH, Peruchi MM, Lin J, Masruha MR, et al. Cystic leukoencephalopathy without megalencephaly. *Arq Neuropsiquiatr* 2008;66(2-A):261-263.
- [45]. Henneke M, Preuss N, Engelbrecht V, Aksu F, Bertini E, Bibat G, et al. Cystic leukoencephalopathy without megalencephaly : a distinct disease entity in 15 children. *Neurology* 2005;64:1411-1416.
- [46]. Lakhkar BN, Aggarwal M, John JR. MRI in white matter diseases – Clinico radiological correlation. *Indian J Radiol Imag* 2002;12(1):43-50.
- [47]. Mann KI, Haqberg B, Petersen D, Riethmuller J, Gut E, Michaelis R. Bilateral spastic cerebral palsy – Pathogenetic aspects from MRI. *Neuropediatrics* 1992;23(1):46-48.
- [48]. Rajagopal KV, Ramakrishnaiah RH, Avinash KR, Lakhkar BN. Van der Knaap disease, A megalencephalic leukoencephalopathy. *Indian J Radiol Imag* 2006;16(4):733-734