

## **Aneurysmal Bone Cyst of Distal Fibula Treated With En-Bloc Excision and Ligamentous Ankle Stabilisation: A Rare Case Report**

**Dr. Arun Kumar V<sup>1</sup>, Dr. MJ Naidu<sup>2</sup>, Dr. Bharat Mandava<sup>3</sup>**

1. Senior Resident, Department Of Orthopaedics, Andhra Medical College, Visakhapatnam.
2. Senior Consultant, Department Of Orthopaedics, MJ Naidu Hospitals, Vijayawada.
3. Junior Consultant, Department Of Orthopaedics, MJ Naidu Hospitals, Vijayawada.

### **I. Introduction**

Aneurysmal Bone Cyst (ABC) is considered to be a pseudotumor which arises from bone and is locally destructive. The most common locations of its occurrence are proximal humerus, distal femur, proximal tibia followed by spine with its preference being metaphysis of long bones. ABC itself accounts for less than 6% of all bone tumours and is four times more rarer than osteosarcoma<sup>(1)</sup>. The etiology of ABC still remains unclear however many proposed that it may result from local circulatory disturbance which inturn leads to increased venous pressure and local hemorrhage production. It is more common during 2<sup>nd</sup> decade of the lifetime and is a rare entity above 30 years<sup>(2)</sup>. General histological picture shows that the stroma is filled with dilated capillaries and cavernous channels. The lesions have osteoclast like giant cells with multiple nuclei. Typically the trabeculae are thick and regular and located along the thin fibrous septa around the blood filled channels<sup>(3)</sup>.

### **II. Case Report**

A 54 year old male presented with pain right ankle with difficulty in movements of ankle joint and gradual swelling since 2 years. There is no history of trauma, fever, cough. There were no associated symptoms. On examination swelling was diffuse and bony hard in consistency present in the anterolateral aspect of right ankle. Swelling was immobile in both planes and getting underneath the swelling was not possible, hence clinically proving it was arising from the bone. Patient had tenderness over the swelling on deep palpation. There was very mild local rise of temperature and without any other signs of inflammation like erythema, induration. Movements of the ankle joint were restricted and he had antalgic gait.

Routine Blood investigations and Chest X-ray were in normal limits. Plain radiograph of the ankle joint revealed an expansile lytic lesion that elevates the periosteum at distal end of fibula which almost involves the articular surface of ankle joint, but remains contained by a thin shell of cortical bone(Fig 1 & 2). MRI of right ankle joint showed that there is a heterogenous area with lytic destruction involving distal fibula with adjacent soft tissue component(Fig 3 & 4). Biopsy report revealed sheets of multinucleate giant cells with surrounding blood vessels, hemorrhage and no malignant cells were seen(Fig 5).

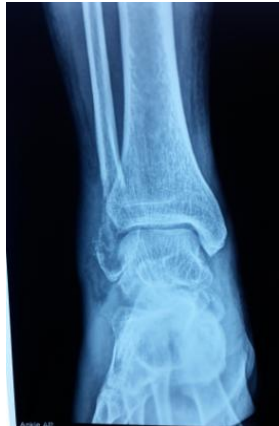Patient was then explained about the treatment we planned and then posted for surgery. Under tourniquet control, distal end of fibula was excised sufficiently and to maintain ankle stability, peroneus brevis tendon was transected proximally at its myotendinous junction and then sutured to the calcaneofibular and anterior talofibular ligaments in sequence and then tenodesed to the lateral distal tibia. Post operatively patient had to be immobilised in a cast for 6 weeks followed by gradual weight bearing and mobilisation of ankle joint(Fig 6 & 7).

### **III. Discussion**

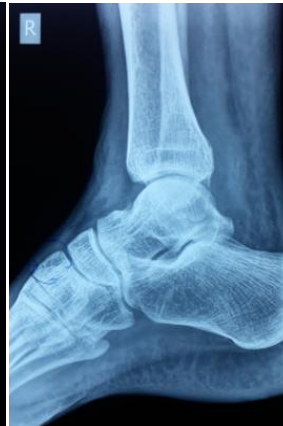ABC is a bony tumor which is osteolytic characterized by several sponge-like blood or serum filled, generally non-endothelialized spaces of various diameters. It is a reactive process with unknown etiology and was first described by Jaffe and Lichtenstein in 1942<sup>(4)</sup>. More than 90% cases of ABC are reported before the age of 30<sup>(5)</sup>, however it is a rare occurrence at the age of 54 as reported here. This lesion commonly occurs at the metaphysis of long bones generally proximal humerus, distal femur or in vertebral bodies and is eccentrically located. Differential diagnosis of ABC include GCT, chondroblastoma, osteoblastoma, fibrous dysplasia, nonossifying fibroma, and chondromyxoid fibroma. ABC is differentiated with Unicameral bone cyst by MRI where the presence of a double-density fluid level and intralesional septations usually indicates an aneurysmal bone cyst. Given that the incidence of ABC in distal fibula is very low, treatment options are also few<sup>(6)</sup>. Regular treatment protocol for ABC is curettage and bone grafting, but since here the lesion involves the lateral malleolus completely en-bloc excision is preferred followed by ankle stabilisation. Few also have described en bloc excision with allograft reconstruction for bony stability<sup>(7)</sup>. Lesion at distal end of fibula is definitely a rare entity and its treatment is a complex issue to deal with, since maintaining ankle stability is difficult following en-bloc excision.

#### IV. Conclusion

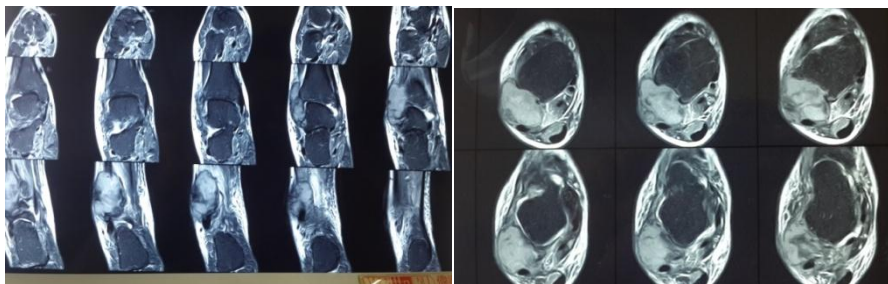
Based on the literature till date, aneurysmal bone cyst occurring at the level of lateral malleolus is rare. Here we report a rare case of ABC at distal end of fibula which was successfully treated with en-bloc excision and ligamentous ankle stabilisation.



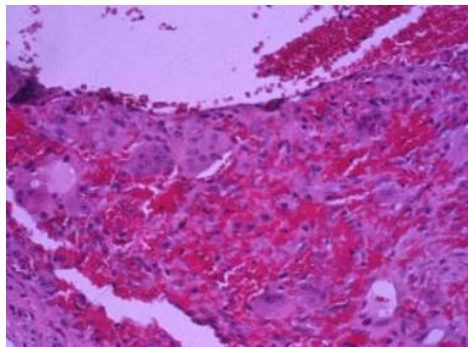
**Fig 1 :** Ankle AP view



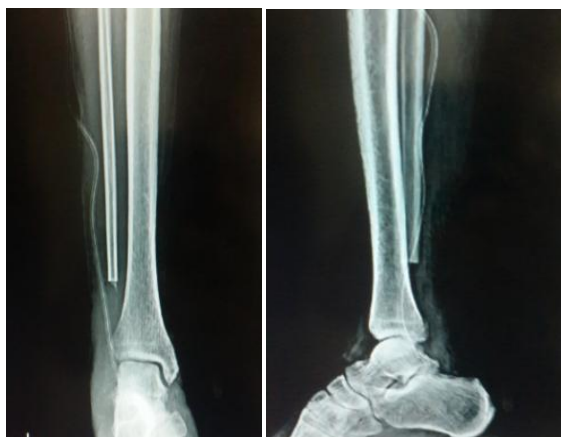**Fig 2 :** Ankle Lateral view



**Fig 3 & 4 :** MRI of Ankle joint



**Fig 5 :** Microscopic picture of ABC



**Fig 7 & 8 :** Post operative pictures of Ankle joint

### References

- [1]. Aneurysmal bone cyst. M. Szendrői, I. Cser, A. Kónya, A. Rényi-Vámos, November 1992, Volume 111, Issue 6, pp 318).
- [2]. Windhager R, Lang S, Kainberger F, Universitätsklinik für Orthopädie, Wien. Der Orthopäde [1995, 24(1):57-64]
- [3]. Aneurysmal bone cyst. A clinicopathologic study of 238 cases. Cancer volume 69, issue 12, pg 2921-2931, 1992 . Ariel M. Vergel De Dios, Jeffrey R. Bond, Thomas C. Shives, Richard A. McLeod and K. Krishnan Unni
- [4]. JAFFE, H. L., and LICHTENSTEIN, L. (1942): Solitary Unicameral Bone Cyst with Emphasis on the Roentgen Picture, the Pathologic Appearance and the Pathogenesis. Archives of Surgery, 44, 1,004
- [5]. Aneurysmal Bone Cyst: A Population Based Epidemiologic Study and Literature Review. Leithner, Andreas MD; Windhager, Reinhard MD; Lang, Susanna MD; Haas, Oskar A. MD; Kainberger, Franz MD; Kotz, Rainer MD. Current Orthopaedic Practice June 1999, Volume 363.
- [6]. Clinical management and surgical treatment of distal fibular tumours: a case series and review of the literature. Perisano C, Marzetti E. Journal Article, Review, Case Reports DOI: 10.1007/s00264-012-1536-3.
- [7]. Aneurysmal bone cyst of the fibula: en bloc resection with allograft reconstruction. Lubliner JA, Robbins H. Europe pubmed central (PMID:2990622) <http://europepmc.org/abstract/med/2990622>.