

## Management of Severe/ Recurrent Blount's Disease – The Oghara Experience

Enemudo RET<sup>1</sup>, Edomwonyi EO<sup>2</sup>, Bafor A<sup>3</sup>, Nwokike OC<sup>2</sup>, Ugwueke GI<sup>4</sup>  
Emina BK<sup>1</sup>

1. Department of Orthopaedics and Trauma, Delta State University Teaching Hospital, Oghara.

2. Irrua Specialist Teaching Hospital, Irrua.

3. University of Benin Teaching Hospital, Benin-City

4. Supreme Faith Specialist Clinic, Asaba

---

**Abstract:** Aim: To report the outcome of treatment of Severe Blount's disease in late-onset type by gradual correction using Ilizarov and multi-axial devices in Delta State University Teaching, Hospital, Oghara.

**Patients And Method:** A three-year retrospective study of five knees in five patients with late-onset Severe Blount's disease treated by gradual method of correction between 12<sup>th</sup> of January 2012 and 31<sup>st</sup> of December 2014 was done. They were managed in a single step, by a gradual method of correction, using the Ilizarov device in four patients and multi-axial correction (MAC) device in one. The procedure comprised of medial tibial plateau elevation, varus deformity and limb length discrepancy (LLD) correction all by distraction osteogenesis after osteotomy. The tibial torsion was corrected acutely after osteotomy. The age range of the patients was 9-35 years (mean=15.8 years), the range tibiofibular (TFA) angle was 30<sup>o</sup>-50<sup>o</sup> (mean=45<sup>o</sup>) and LLD was 4-8cm (mean=6cm). MPTA range was 35-50<sup>o</sup>. Outcome was assessed by Schoenecker criteria.

**Results:** After a mean period of 4 months (3-5months) of removal of the device, results were good in all 5 patients. The range of TFA was 5-9<sup>o</sup> valgus (mean=6.8<sup>o</sup>). The range of MPTA post procedure was 15-22<sup>o</sup> (mean=18<sup>o</sup>). LLD was resolved in all limbs. The results remained same after a follow up period of 1-2years (average of 14 months). Complications include pains around pin sites, pin-tract infection and muscle spasms during distraction and hypertrophic scar or keloid formation in the surgical wound. The complications were resolved with treatment but the hypertrophic scar and keloid remained.

**Conclusion:** Correction of unilateral severe Blount's disease with associated LLD, often seen in recurrent and neglected Blount's disease, is possible with gradual method of correction using Ilizarov or multi-axial correction device. This is not possible with acute methods of correction except it is bilateral.

---

### I. Introduction

Blount's disease is a developmental disorder of children and adolescents<sup>1</sup>. It is characterized by growth disorder of the posteromedial aspect of the proximal tibia physis, epiphysis and metaphysis leading to progressive lower limb deformity. It is a multiplanar deformity with 3 main features; tibia vara deformity on a frontal view, procurvatum on a sagittal view and internal torsion<sup>1,2,3</sup>. In severe forms, the distal femur is involved and there may be shortening of the affected limb leading to limb length discrepancy<sup>4</sup>.

Blount's disease was first identified by Erlacher in 1922<sup>5</sup> but was first published in an article in 1937 by Blount<sup>5</sup>, where he highlighted the clinical and radiological features of the disease. Blount classified the disease into 2 groups; early (infantile) and late onset<sup>2,3</sup>. The late type is subdivided into juvenile and adolescent<sup>2,3</sup>. The early type is usually bilateral and is often not associated with obesity<sup>6</sup>. The late type, however, is usually unilateral and is often associated with obesity<sup>5</sup>. Langenskiold observed the progression of the disease in x-rays and classified it into 6 stages (i-vi)<sup>2,3</sup>.

Treatment of the condition is usually by acute or gradual correction of the deformity<sup>7-9</sup>. Several methods of correction have been carried out. The use of braces (knee-ankle-foot orthosis) to prevent progression at the early stage<sup>10</sup>, use of staples on the lateral side of the proximal tibia and proximal fibula, different types of osteotomies (lateral based closed wedge, medial open wedge, dome-osteotomy<sup>7</sup>. Acute correction involves use of osteotomies and is preferred for early type. Acute correction gives better outcome if carried out before the age of 4years to prevent recurrence<sup>11</sup>. It may, however, be associated with failure and recurrence when used for the late-onset types<sup>12,13</sup>. Gradual correction is achieved by distraction osteogenesis using Ilizarov device<sup>8,9</sup>, Taylor spatial<sup>14</sup> frame or Multi-Axial Correction (MAC) device<sup>15</sup>. It gives better outcome for both early and late types. It also addresses the problems of failure and recurrence resulting from acute methods of correction<sup>8,9</sup>.

We present our experience with the gradual method of correction of deformities associated with neglected and recurrent forms of severe Blount's disease using the Ilizarov device and Multi-Axial Correction (MAC) device.

## **II. Materials And Method**

This is a three-year (Jan 2012-Dec 2014) retrospective study of the 5 patients with neglected and recurrent severe Blount's disease managed by gradual method of correction using Ilizarov and MAC devices in Delta State University Teaching hospital Oghara. Inclusion criteria were those patients with severe forms of Blount's disease, those with recurrent forms of Blount's disease, both sexes, all ages. Exclusion criteria include patients who had tibia vara deformity from other causes such as trauma, metabolic derangements and genetic abnormalities. All patients were followed up clinically and radiologically.

Data collected included gender, unilateral/bilateral nature of the disease, age at operation, number of previous surgeries, duration of external fixator, period of follow up. Presence of any intra-operative or post-operative complication(s) was noted. Data was analyzed using simple statistical methods.

### **Operative Technique (with Ilizarov device)**

Patient was placed in supine position under general anaesthesia. Parenteral prophylactic antibiotic (ceftriaxone) was given. A tourniquet was applied at the mid thigh of the affected limb. The limb was cleaned and draped exposing the distal thigh and the whole leg. A longitudinal incision was made on the lateral aspect of the middle of the leg. This was dissected deep to expose the fibula. The periosteum was incised and the fibula osteotomized obliquely. Wound was irrigated and closed up in 2 layers. A lazy S was made extending from the lateral aspect of the knee to the medial aspect of the leg to expose the proximal end of the tibia. The centre of rotation of angulation (CORA)<sup>8,9</sup> was identified at the proximal half of the tibia. Two kirschner (K) wires were passed close to the proximal end of the tibia and parallel to the tibia plateau. They were separated from each other by 30 degrees. These were attached and tensioned to the opposing surface of a half ring of the Ilizarov device, placed on the anterior aspect of the leg. Two short Steinmann pins, were attached to this half ring by means of a Rancho cube each. At middle third of the leg, below the CORA, a pair of K-wires separated by 30 degrees from each other were inserted into the tibia perpendicularly and attached and tensioned to a half ring placed anterior to the leg. Another pair of K-wires was attached similarly to a third half ring placed at distal third of the leg. The 2<sup>nd</sup> and 3<sup>rd</sup> rings were connected together by connecting rod placed at the medial, lateral and middle of the half rings. The 1<sup>st</sup> and 2<sup>nd</sup> rings were linked together by hinges placed at the medial, middle and lateral ends of the rings. The periosteum on the proximal third of the tibia was incised and corticotomy done at the level of CORA and made parallel to the proximal ring and tibia plateau. Wound was irrigated and closed up in one layer. The nuts were tightened. A latency period of 1 week was observed before distraction was commenced. The distraction was done at the middle and lateral connecting rods. The middle one was turned at 45 degrees and the medial one at 90 degrees every 6 hours while the lateral one was not turned. This continued until the 1<sup>st</sup> and the 2<sup>nd</sup> rings became parallel. At this point all three rods were distracted between the 1<sup>st</sup> and 2<sup>nd</sup> rings to correct residual limb length discrepancy. Patient and relation (mother most times) were taught how to distract and care for the pins and device. Patient was discharged home after 2 weeks on admission by which time the relatives had mastered the procedure and care of the device. They were seen in the out-patient's clinic every week for the first month to monitor how they were coping with the procedure and correct any error made. Thereafter the visit was 2 weekly until distraction was complete. The device was maintained for 2 months to allow the regenerate consolidate a bit before the limb was incorporated into a scotch cast. The external Ilizarov rings were removed leaving the traversing k-wires and schanz pins until the regenerate got fully consolidated. A protective above knee scotch cast was applied, before graduated weight bearing was commenced.

### **Operative Technique (with MultiAxial Correction device)**

A mid thigh tourniquet was applied on the affected limb after giving prophylactic antibiotic (ceftriaxone). The operation site was prepared and draped. A longitudinal incision was made on the lateral aspect of the middle of the leg. This was dissected deep to expose the fibula. The periosteum was incised and the fibula osteotomized. The wound was irrigated and closed up in two layers. A lazy S incision was made on proximal metaphyseal region exposing the CORA. An inverted mediolateral dome osteotomy centred on the CORA was done. The proximal fragment was rotated to make the tibial plateau lie horizontally. The distal fragment was rotated externally to correct the internal tibia torsion. The MAC device was then applied on the tibia to maintain the correction achieved. The 3 horizontal pin of the device attached to the proximal fragment and vertical component on the distal tibia fragment. A latency period of 1 week was observed before distraction osteogenesis was commenced at the rate of 1mm/day. This was stopped when the limb length discrepancy between the two limbs was corrected. The proximal hinge in the device was slackened to allow correction of the knee into 7 degree valgus before the hinge was tightened again. Thereafter the limb was incorporated into scotch cast to maintain the correction. Non-weight bearing ambulation with the aid of axillary crutches was done over a period of two months. Graduated weight bearing was thereafter commenced until the regenerate got fully consolidated.

All patients received analgesics (diclofenac/ibuprofen and tramal), muscle relaxant (methocarbamol), antibiotics (ciprofloxacin/cefuroxime), vitamin C and D plus calcium supplement. Pin and pin sites were cleaned daily using normal saline and methylated spirit and dressed with povidone iodine. Post-operative radiographs were obtained at one month intervals in order to monitor the progress of healing. Patients were followed up for periods of 1-2 years after removal of device.

### III. Results

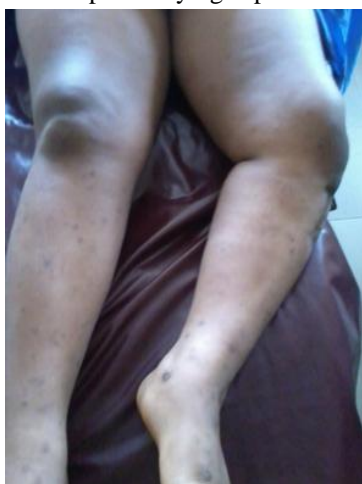A total of 5 patients treated for severe Blount's disease were reviewed in this study. All the patients treated had unilateral Blount's disease. Three of the cases were unilateral and recurrent from an initial bilateral Blount's disease that had been operated previously, while the other two cases were neglected 12 years and 35 years old respectively. All the cases were late-onset Blount's disease, two being juvenile type (9-10years) and the rest adolescent type (>10years). There was a M: F ratio of 1:4. The age range was 6-35 years with a mean age of 15.8 years. Four patients were treated with Ilizarov device and one with monoaxial correction device. The range of limb length discrepancy (LLD) managed was 4-8cm (mean=6cm). This was corrected after surgery. Outcome was good in all the patients using Schoencker criteria<sup>15</sup>. The range of TFA seen was 30-50° varus (mean=45°) before surgery. After treatment, the mean TFA achieved was 6.8° valgus with a range of 5-9°. The range of pre-operation MPTA was 35-50° (mean=42.2°). The post-procedure MPTA was 15°-22° with a (mean=18°). The mean operative time for the Ilizarov technique was 3 hours while for MAC technique, it was 2½ hours. The complications seen in this study were pain, muscle spasm, pin tract infection, wound dehiscence, hypertrophic scars and ligamentous laxity of the knee joint.

**Table: Clinical Details Of Patients And Outcome.**

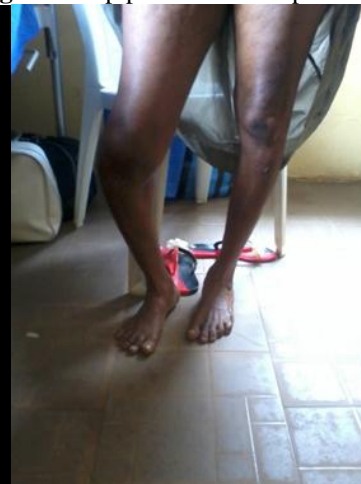Age (years)	Sex	LLD (cm)	TFA (varus)	Nature of disease	surgery before procedure	Outcome
10 35° / 15°	F	6	45°	Unilateral	2	9°
9 45° / 18°	M	4	30°	Bilateral	1	8°
35 41° / 15°	F	6	50°	Unilateral	0	6°
12 50° / 22°	F	8	50°	Unilateral	2	5°
13 40° / 20°	F	6	50°	Unilateral	0	6°

TFA= Tibiofemoral, LLD=Limb length discrepancy, M=male, F=female, op=operation, MPTA= medial proximal tibial angle.

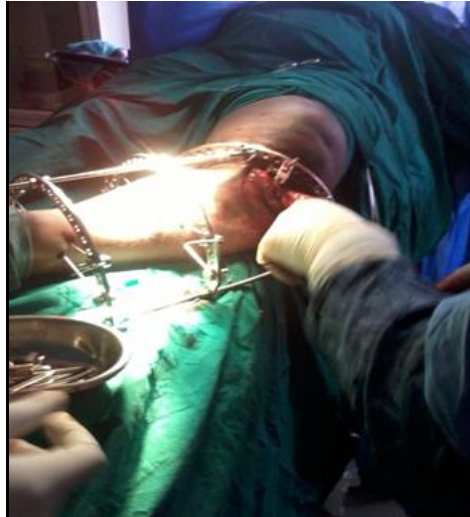
**Fig 1:** Pre-op picture of patient lying supine



**Fig 2:** Pre-op picture of a 2<sup>nd</sup> patient standing



**Fig 3 :** Intra-op picture of Fig 1 patient.



Fi 4 & 5: shows clinical post-op state and x-ray during distraction respectively of patient in Fig 1

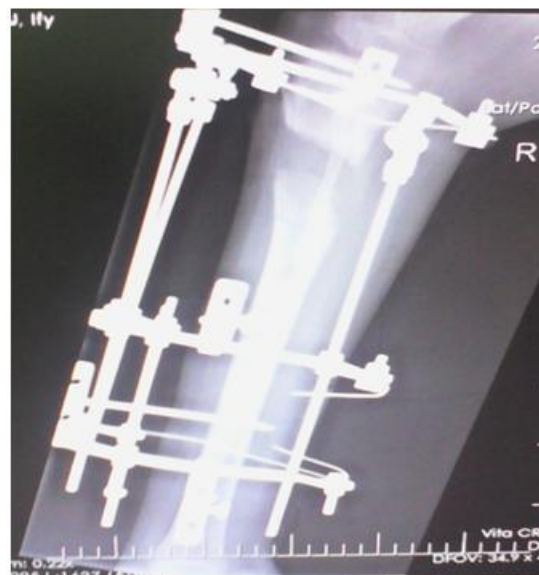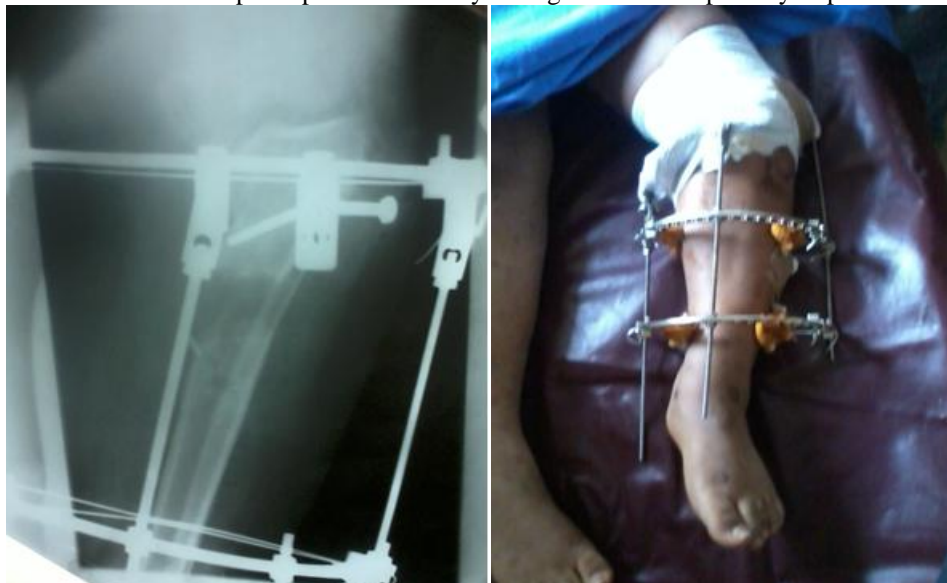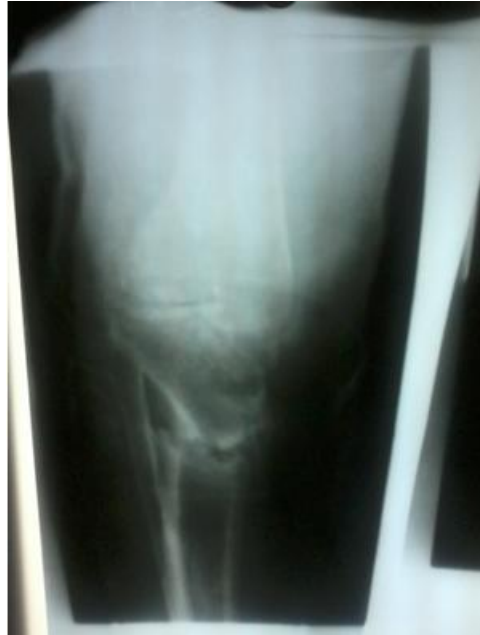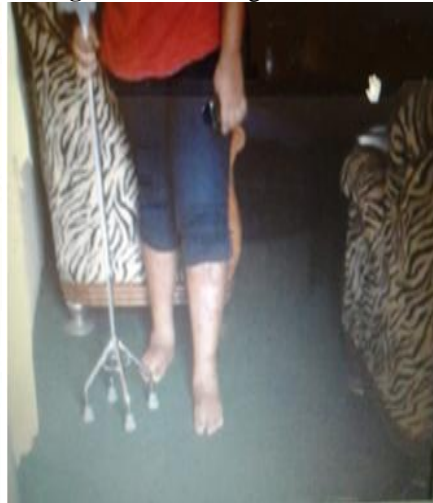


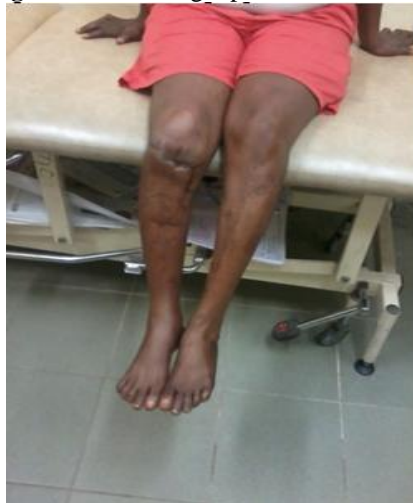Fig 6: X-ray of 2<sup>nd</sup> patient during distraction by Ilizarov distraction  
Fig 7: X-ray of 2<sup>nd</sup> patient limb post-distraction



**Fig 8:** Patient in Fig 2 post-correction

**Fig 9:** Patient in Fig 1 after correction.



#### IV. Discussion

The concept of gradual correction of Blount's disease was first reported by Price, Scott and Greenberg<sup>17</sup>. The problems of recurrence and failure often associated with severe Blount's disease managed by acute methods of corrections (using the various osteotomies) have been resolved with the development of gradual methods of correction of Blount's disease<sup>8,9</sup>. The principle of gradual correction is distraction osteogenesis, a process that leads to the formation of new soft tissues and bone tissues<sup>8,9</sup>. This is not possible with acute methods of correction. LLD that occurs in unilateral Blount is easily resolved by gradual methods of correction and not by acute method while LLD that occurs in bilateral Blount can be corrected by both acute and gradual methods of correction<sup>8,9</sup>. This demonstrates the versatility of the gradual method. All the patients managed in this study with LLD from unilateral Blount's disease were successfully corrected without tampering with the longer unaffected opposite limb. Three of the patients had recurrence in one limb. They initially had bilateral juvenile Blount's disease that was treated by corrective osteotomies (acute method). Two of them had surgery twice while the third patient had one surgery done for him prior to their presentation. The recurrences are due to the following reasons; one is incomplete correction of the varus deformity causing the mechanical weight bearing axis to pass through the medial tibial condyle<sup>12,13</sup>. Second is obesity. Obesity was observed in 2 of the female patients in our study. They were 10years and 12 years old and weighed 65kg and 85kg respectively. In addition to the corrective surgery, they were counseled to shed weight. Excess weight suppresses growth in medial tibial plateau area<sup>12,13</sup>. The third reason is the persisting growth arrest in the medial proximal tibia caused by the presence of bone bridge<sup>12</sup>. This factor often warrants repeated corrective

osteotomies in the future until the patient stops growing<sup>12</sup>. The fourth and fifth reasons are the persistence of contracted medial collateral ligament and a lax lateral collateral ligament after acute correction.

Price et al treated 31 tibiae vara in 23 patients successfully using gradual method of correction. They achieved 20 degrees correction between the pre- and post-operative mechanical axis. They concluded that dynamic axial external fixator was easy to apply, adjustable, allowed early weight bearing and had the ability to lengthen the extremity.

Accabded et al<sup>16</sup> treated four patients as follows; percutaneous epiphysiodesis of the superolateral tibia and proximal fibula, elevation osteotomy of the medial tibial plateau, osteotomy of the fibula and dome-shaped metaphyseal osteotomy of the tibia followed by progressive lengthening by Ilizarov frame. Latest follow-up at an average of 6 years 10 months showed that all patients were satisfied with normal limb length, alignment and joint congruence.

Schoenecker et al<sup>17</sup> managed 7 children with severe Blount's disease using acute method by elevating the depressed medial tibial plateau and concomitant osteotomy of the tibial shaft to correct the tibial torsion. The outcome was good in 5 and fair in 2. Hoffman EB et al<sup>19</sup> reviewed 34 knees in 24 children managed by double-elevating osteotomy (acute method) for late infantile Blount's disease. The mean age of the patients was 9.1 years (7-13.5years). All had Langenskiold stage of IV-VI. The osteotomies were elevating osteotomy to correct depressed medial tibial plateau and another osteotomy below the tibial apophysis to correct the tibial varus and internal torsion. In the more recent cases managed by them, an additional tibial epiphysiodesis was performed at the same time. In both studies of Schoenecker and Hoffman, LLD were not significant to affect outcome of treatment or warrant treatment.

Fitoussi et al<sup>20</sup> managed knees in patients using Ilizarov device as external fixator in a single step that comprised medial tibial plateau elevation, lateral tibial epiphysiodesis and proximal osteotomy below tibial tubercle to correct varus and rotational deformity. The mean age of the group studied was 10.5 years. Outcome was good in 6, medium in 1 and poor in 1.

The patients in our study had marked ligamentous laxity of the lateral collateral ligament of their knee joints leading to lateral thrusting of the knee joint during ambulation before treatment. Siffert-Katz test was positive<sup>21</sup>. Part of the laxity was resolved following correction with the devices and the remaining correction occurred when the limb was put in scotch cast and with prolong use of knee brace after removal of the cast. This made the redundant lateral collateral ligament to contract over time. Siffert test was negative afterwards. The marked tethering or contracture of the skin and soft tissues of the medial aspect of the knee joint in Blount's disease is partly responsible for the failures of acute correction. The gradual method made it possible to overcome the soft tissue contractures on the medial aspect of the proximal leg. It also addressed the problem of limb length discrepancy associated with growth arrest.

Gradual method of correction, using the Ilizarov device, has its own disadvantages. Among them are long time it takes to achieve correction, learning curve for the surgeon takes time to attain<sup>22</sup>. It is often cumbersome for the patient to understand the adjustment of the device most times<sup>22</sup>. The complications seen in this study were pains around pin sites, pin-tract infection, muscle spasm and sores<sup>23</sup>. This was more with the Ilizarov than the MAC device because of the fewer pins in the MAC device. This was similar to the findings of other authors in the literature<sup>22, 23</sup>. Some authors have experienced impalement of neurovascular structures and compartment syndrome<sup>20</sup>. The problem of neurovascular injury is avoided by knowledge of neurovascular planes and avoiding them<sup>22</sup>. Most of these problems have been addressed with the development of MAC device<sup>14</sup>. Despite the long delay to achieve correction and other associated problems, the good outcome of the procedure far outweighs the drawbacks.

## V. Conclusion

The use of distraction osteogenesis has helped to gradually correct severe Blount's disease, a complication usually associated with failure of acute correction of late-onset Blount's disease or neglected forms of the disease. Correction of Blount's disease before the age of 4 years is advocated to prevent recurrence. Also important in the treatment of Blount's diseases is weight reduction in obese patients.

## References

- [1]. Blount WP. Tibia vara osteochondritis deformans tibiae. *J. Bone Joint Surg* 1907;19: 1-29
- [2]. Thompson H, Carter JR. Late-onset tibia vara (Blount's disease) Current concepts. *Clin Orthop Relat Res* 1990; 255:24-35
- [3]. Lagenskiold A, Riska GB. Tibia vara (osteochondritis deformans tibiae): a survey of seventy one cases) *J. Bone Joint Surg Am.*1964; 46:1405-20
- [4]. Sabharwal S, Lee J Jr, Zhao C. Multiplanar deformity analysis of untreated Blount's disease. *J.Pediatr. Orthop.* 2007; 27(3):260-5
- [5]. Langenskiold A. Tibia vara; (osteochondrosis deformans tibiae); a survey of 23 cases. *Acta Chir Scand.* Mar 26 1952;103(1):1-22. [[Medline](#)].
- [6]. Gordon JE, Hughes MS, Shepherd K, Szymanski DA, Schoenecker PL, Parker L. Obstructive sleep apnoea syndrome in morbidly obese children with tibia vara. *J Bone Joint Surg Br.* Jan 2006;88 (1):100-3. [[Medline](#)].
- [7]. Sabharwal S. Blount disease. *J Bone Joint Surg Am.* Jul 2009;91(7):1758-76. [[Medline](#)]. Surgical approaches



- [8]. Paley D. Current Techniques of Limb Lengthening. *J. Paediatr. Orthop.*1988; 8:73
- [9]. Ilizarov GA. The Tension-Stress Effect on the Genesis and growth of Tissues II. The Influence of the rate and frequency of distraction. *Clin. Orthop.* 1990; 239:263
- [10]. Richards BS, Katz DE, Sims JB. Effectiveness of brace treatment in early infantile Blount's disease. *J Pediatr Orthop.* May-Jun 1998;18(3):374-80. [[Medline](#)].
- [11]. Loder RT, Johnson CT. Infantile tibia vara. 2<sup>nd</sup> edition. *J.Pediatr.Orthop.*1987; 7:639-46
- [12]. Chotigavanichaya C, Salinas G, Green T, Moseley CF, Otsuka NY. Recurrence of varus deformity after proximal tibial osteotomy in Blount's disease: long term follow up. *J. Pediatr. Orthop.* 2002; 22(5):638-41
- [13]. Arkin AM, Katz JF. The effects of pressure on epiphyseal growth; the mechanism of plasticity of growing bone. *J Bone Joint Surg Am.* Oct 1956; 38-A(5):1056-76. [[Medline](#)].
- [14]. Pandya NK, McCarthy JJ, David Ham B, Hosalkar HS. Correction of Blount's disease by a multi-axial external fixation system. *J. Child Orthop.* 2009;3(4):291-9
- [15]. Eidelman M, Bialik V, Katzman A. A use of the Taylor Spatial Frame in adolescent Blount's disease: is fibular osteotomy necessary?
- [16]. Accadbled F, Laville JM, Harper L. One-step treatment for evolved Blount's disease: four cases and review of literature. *J. Paediatr Orthop.* 2003 Nov-Dec; 23(6):747-52
- [17]. Shoenecker PL, Johnston R, Rich MM, Capelli AM. Elevation of the medial plateau of the tibia in the treatment of Blount's disease. *J.Bone Joint Surg (Am)* 1992;74-A:351-8
- [18]. Price T, Scott DS, Greenberg DA. Dynamic axial external fixation in the surgical treatment of tibia vara. *J. Pediatr. Orthop.*1995;15:23-43
- [19]. Hoffman EB, Olesak M, Hastings CJ, Huyssteen AL. Double-elevating osteotomy for late-presenting infantile Blount's disease. The importance of concomitant lateral epiphysiodesis. *J. Bone Joint Surg Br* 2005; Vol 87 no5:710-5
- [20]. Fitoussi F, Ilharborde B, Lefevre Y, Souchet P, Presedo A, Mazda K, Pennecot GF. Fixator-assisted medial tibial plateau elevation to treat severe Blount's disease: Outcome at maturity. *Orthopedics & amp, Traumatology Surgery & amp, Research.* 2011; Vol 97, no 2:172-8
- [21]. Siffert RS, Katz JF. The intra-articular deformity in osteochondrosis deformans tibiae. *J.Bone Joint Surg Am* 1970;52-A: 800-4
- [22]. Mosca V, Moseley CF. "Complications of Wagner leg lengthening and their avoidance." *Orthop Trans.* 1986;10:462 .
- [23]. Paley D. "Problems, Obstacles and Complications of Limb lengthening by Ilizarov Technique" 1990; 250:81-104