

Unicystic Ameloblastoma- A Case Report

Dr. Shashikala.R¹ Dr. Saurabh Gupta²

1, MDS, Oral and Maxillofacial Surgery,

M.R Ambedkar Dental College and Hospital, Bangalore

2, MDS, Oral and Maxillofacial Surgery, Axiss Dental Pvt Ltd, Bangalore

Abstract: Ameloblastoma can be described as an epithelial odontogenic jaw tumor which shows various single or combined patterns when observed under the microscope. It is the commonest type of jaw tumor after Squamous Cell carcinoma. Generally, it develops as early as tooth formation takes place and in adults it can develop from odontogenic cysts or cell rests. It comprises of solid tissues made up of various cystic cavities. The tumor histologically is made up of webs of ameloblasts. Radio graphically, it represents itself as unicystic or multicystic. The tumor grows gradually and is malignant locally but does not result in metastasis to the lymph nodes generally. Ameloblastoma can be treated by radical surgical removal. The jaw is the commonest site for the tumor to originate and a resection of the mandible is the best treatment in serious cases. Very rarely does the jaw need to be completely resected. Here is a case report on the treatment of Ameloblastoma's in the Oral and Maxillofacial Surgery department of M.R Ambedkar Dental College & Hospital located in Bangalore. In this report, there are two cases which have been treated by resection, one with and the other without the PMMC flap. The patients were regularly followed-up to look for recurrence and to find out any other complications which can arise after the jaw's resection.

Keywords: Ameloblastoma, Hemimandibulectomy, Segmental Resection

Key Messages: The unicystic ameloblastoma must be considered a unique entity and treated conservatively.

I. Introduction

Ameloblastoma can be referred to as an odontogenic tumor of jaws which arise from a number of sites mentioned here. They originate from the cell rests of the enamel organ, remnants of the Hertwig Sheath, remnants of the Dental lamina, epithelial rest of Malassez, basal cell epithelium of the jaws, developing enamel organ and from the heterotropic epithelium in the pituitary gland and the odontogenic cyst specifically the odontomas and the Dentigerous cyst.

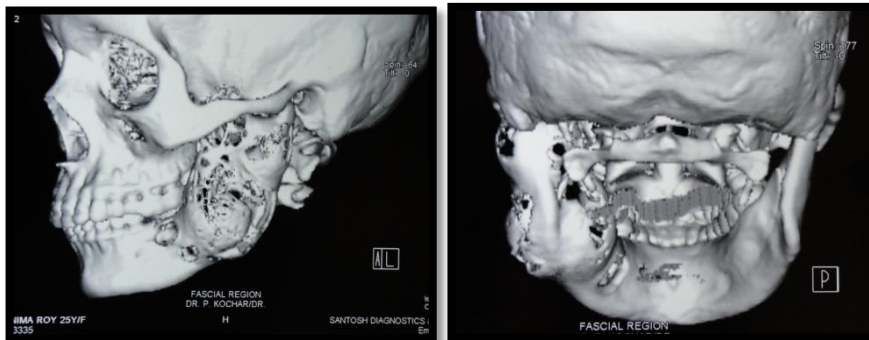
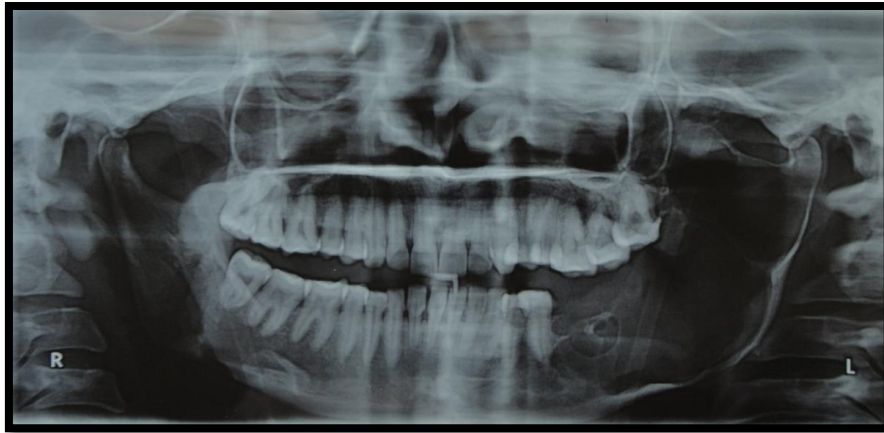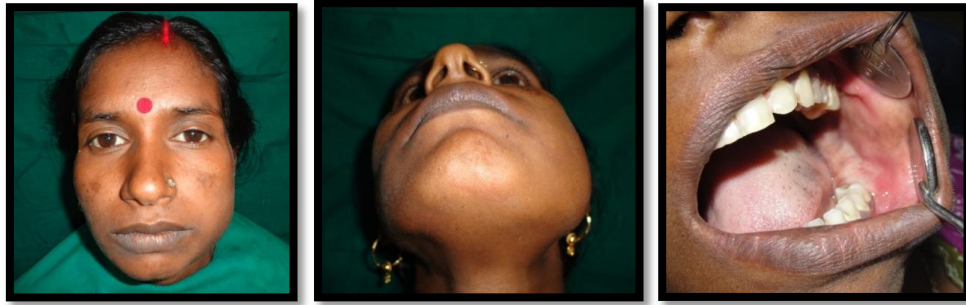
1% of the jaw tumors and cysts are comprised of ameloblasts and its occurrence in the jaw is 5 times greater than the maxilla. The average age at which it occurs is 38.9 years with 52% occurrences in men and 48% in the women. It grows gradually and is quite painless but it can become significantly large within an individual's mid-face involving the brain, skull-base and the orbit. Small & Waldron revealed that about 47% of maxillary ameloblasts originate in the molar area with 33% occurring in the nose floor and the antrum, 9% in the canine and premolar region and 2% on the palate.

In the mandible the commonest site is the ascending ramus and the molar region around 39% out of which 16% in molar premolar region and 9% in anterior area. Also, ameloblastoma is a kind of tumor which rapidly recurs after the treatment. This rate ranges from 17.7% for resection and 34.7% for a conservative therapy. Thus, wide resections were made keeping a safety margin to the recurrence. However, various authors suggest curettage and enucleation in case of unicystic ameloblastoma for mural and intraluminal varieties.

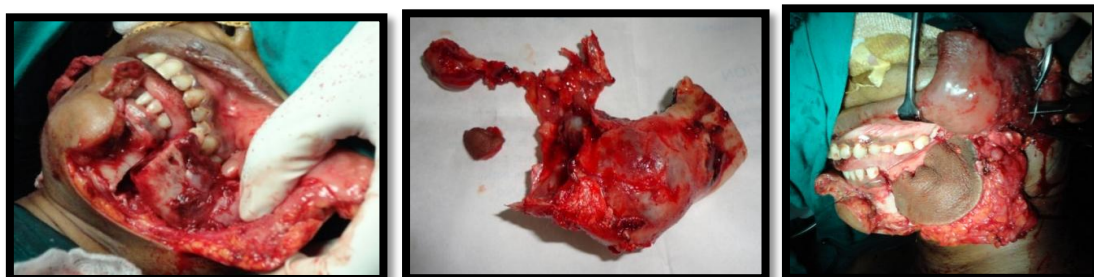
II. Case History

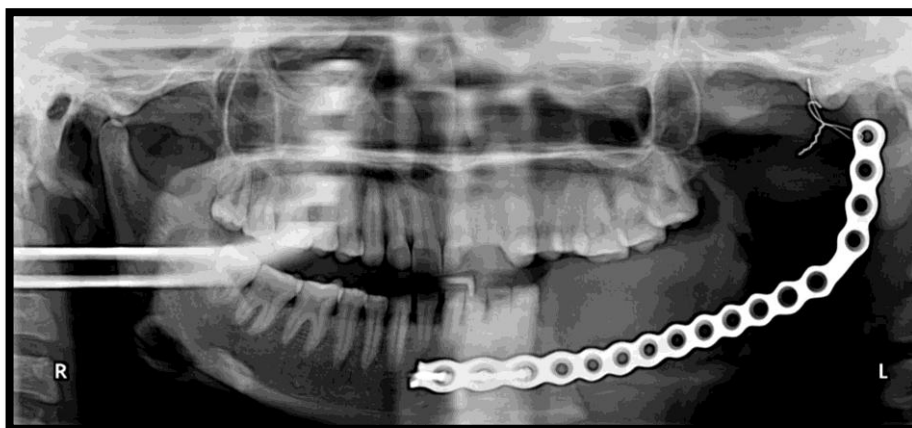Case 1

Back in September 2011, a twenty-five year old woman reported a painless and advanced swelling of her lower left jaw. Extra-oral swelling was seen from the mouth corner to the ear tragus. An intraoral examination showed a swelling subsequent to 35 destroying the buccal vestibule, oral hygiene was found to be poor and 36, 37 and 38 were missing. Radio graphical examination showed that the lesion was a multicystic one.



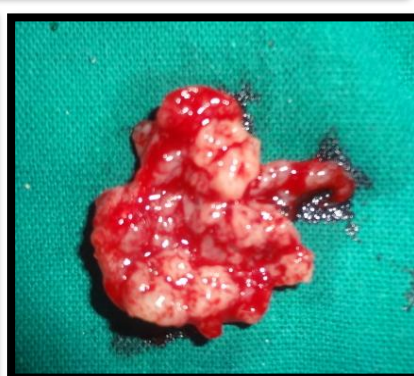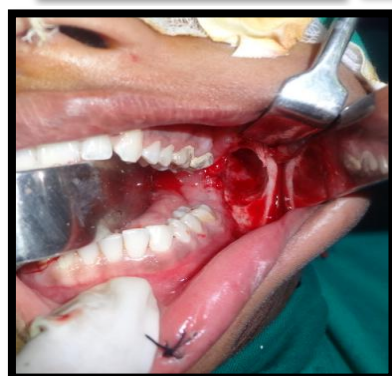
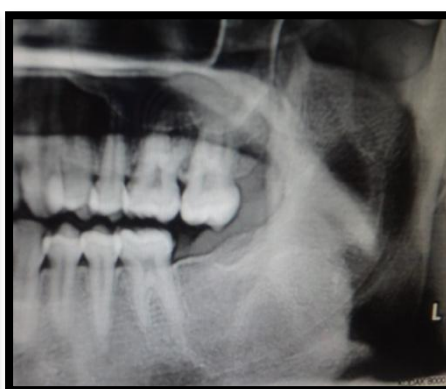The best option for treatment in this case was segmental mandibulectomy and instant reconstruction with the help of reconstruction plate and pectoralis major myocutaneous flap. The diameter of the wound was 90mm and was reported to be a case of unicyclicameloblastoma.

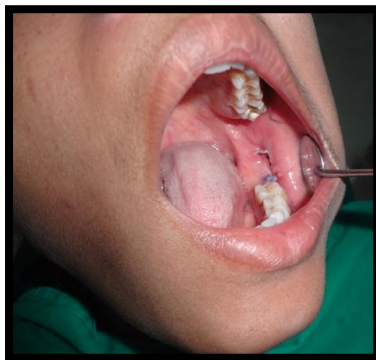



Case 2

In August 2010, a twenty year old female reported an advanced swelling in her lower left jaw. The swelling outside the mouth was tender and was extending from the mouth corner to the ear tragus. Intraoral examination showed exophytic swellings from 36 till 38. Radio graphical examination showed that the lesion was a unicyclic one and 36 had root resorption. In the month of September in the same year she was treated with enbloc re-sectioning from 36 till 38 distal ends. Histopathological report revealed a resected unicyclicameloblastoma which is a variant of ameloblastoma. The healing process was normal and she got a discharge within 4 days. Follow-up was done and no recurrence was noticed. According to radio graphical reports the lesion was found to be unicyclic and histopathological reports showed unicyclicameloblastoma. In the follow-up period of 4 months no recurrence and complication was seen.





III. Discussion

Ameloblastoma is the commonest form of odontogenic tumor after odontoma and most of the cases originate in the molar-ramus area. Back in 1934, Churchill suggested the term 'Ameloblastoma'. It is reported to affect both the sexes in equal ratio and largely in the 3rd, 4th and 5th decade. Till date almost 15 different varieties of this tumor have been recorded. The most common ones are plexiform, follicular, desmoplastic, granular, unicystic, basal cell and the peripheral variant of it occurs minimally. Some of the other variants are clear cell, acanthomatous, mucous cell differentiation, keratomeloblastoma and hemangiomatous. The surgical treatment for most of these varieties is same but varies for the unicystic type.

In 1974, Robinson & Martinez first defined the term 'Unicysticameloblastoma'. Among all the types the frequency of this tumor is in between 5 to 22%. The pathogenesis of such a lesion is still a topic for debate.

Three basic mechanisms have been suggested in the development of unicysticameloblastoma. Firstly, the enamel epithelium when reduced along with a developing tooth experiences ameloblastic transformation with successive cystic developments. Secondly, ameloblastomas also occur in odontogenic and dentigerous cysts where the neoplastic ameloblastic epithelium is led by a lining of non-neoplastic squamous epithelial. Thirdly, the ameloblastoma experiences cystic degeneration of the ameloblastic islands followed by the fusion of various micro cysts and forms a lesion which is cystic. The number of PCNA-positive cells is relatively higher than the lining of dentigerous cysts suggesting that the tumor ascends *de novo*. The major complication resulting from the dentigerous cysts is its transformation to the ameloblasts.

The points mentioned here are used to differentiate UA from a cystic lesion. These points were given by Vicker&Gorlin. Firstly, parts of the epithelial lining show some transformation to columnar or cuboidal basal cells having hyper chromatic nuclei. Secondly, nuclear palisading with complete polarization is seen. Thirdly, cytoplasmic vacuoles with some intercellular spacing are found. Lastly, sub-epithelial hyalinization is noticed.

These findings were common in our case also. A histological subgrouping of the ameloblasts which are unicystic has been provided by Ackermann et al. Depending on the classification given above, our case was sub grouped as 1.2. In the surgical context, tumors under sub-group class 1 are enucleated and the jawbone gets salvaged. Higher sub-groups have normal surgical requirements which may differ from hemimandibulectomy to segmental resection depending on the lesions size and the amount of remaining bone. Segmental mandibulectomy along with reconstruction was done in this particular case.

IV. Conclusion

In order to manage maxillofacial ameloblastomas the suggested treatment is aggressive resection. This procedure may not be required in all the cases. The treatment plan should be formulated keeping in mind the patients age and histopathological reports showing the degree of invasion done by the tumor.

When young individuals suffer from ameloblastoma of the intramural and mural area occurring within the cyst wall, lumen or lining, treatments which are less aggressive and therapeutic in nature can be recommended. For example, enucleation along with decortication by applying Carnoy's solution and then peripheral ossectomy can be done. Regular follow-up of the patient must be done.

If vigilant histopathological examination of the various sites of the cyst linings is done, it can greatly help in the correct diagnosis and result in the best therapeutic surgical treatment preventing recurrence.

References

- [1]. Henry M. Cherrick .Odontogenic tumors of the jaw. In: Daniel M Laskin. Ed. Oral and Maxillofacial surgery, Delhi, India: AITBS. 2009. P. 626-636.
- [2]. Small IA, Waldron CA. Ameloblastoma of the Jaws. Oral Surg Oral Med Oral Pathol 1995;8:281-297.
- [3]. Chaudhuri P: Ameloblastoma of the upper jaw. J Laryngol Otol. 1975;89:457-465.
- [4]. Reichart PA, Philipsen HP, Sonner S. Ameloblastoma: Biological profile of 3677 cases. Oral Oncol, Eur 'j Cancer. 1995;31:86-99.
- [5]. WHO classification. Oral Oncol. 2006;42:757- 758.

- [6]. Odontogenic tumors: Hamartomas and neoplasm: In Robert E. Marx. Ed. Oral and maxillofacial pathology A rationale for diagnosis and treatment. Chicago: Quintessence. 2003. P. 640.
- [7]. Shatkin S, Hoffmeister FS. Ameloblastoma: A rational approach to therapy. Oral Surg Oral Med Oral Pathol. 1965;20:421–435.
- [8]. Pogrel MA, Montes DM. Is there a role for enucleation in the management of ameloblastoma? Int J Oral Maxillofac Surg. 2009;38:807-812.
- [9]. Olaitan AA, Adekeye EO. Unicystic ameloblastoma of the mandible: A long term follow up. J Oral Maxillofac Surg. 1997;55:345-348.
- [10]. Carlson ER, Marx RE. The Ameloblastoma: primary, curative surgical management. J Oral Maxillofac Surg. 2006;64:484-494