

## A Rare Case of Massive Pleural Effusion Due To Ruptured Liver Abscess

Dr. Deependra Kumar Rai<sup>1</sup>, Dr. Siddharth Singh<sup>2</sup>, Dr. Shyama Kumari<sup>3</sup>

Assistant Professor & Head<sup>1</sup>, Department of Pulmonary Medicine & Tuberculosis, All India Institute of Medical Sciences, Patna, Bihar

Senior Resident<sup>2</sup>, Department of General Medicine, All India Institute of Medical Sciences, Patna, Bihar  
General physician<sup>3</sup>, Patna, Bihar

**Abstract:** We report a case of ruptured liver abscess with massive right side pleural empyema. This patient presented with breathlessness, upper abdominal pain and generalised body weakness from last 10 days. On examination patients had tachypnea, tender hepatomegaly, with decreased breath sound to whole right hemithorax. USG suggestive of single large liver abscess with right side pleural effusion. Chest x-ray was also done which shows completely right hemithorax opaque which is very rare finding. Patients was managed on antimicrobial treatment with intercostals tube drainage and other conservative treatment. Patients is doing well after treatment. We should keep differential of ruptured liver abscess in completely right hemithorax opaque with abdominal pain in country like India where amebiasis is frequent.

### I. Introduction

Liver abscess (LA) is defined as collection of purulent material in liver parenchyma which can be due to bacterial, amoebic infection etc. Amoebic liver abscess is more common in developing country where as pyogenic liver abscess is more frequent in developed country<sup>1</sup>. Pyogenic abscesses of the liver occur secondary to biliary or intestinal tract infections, haematogenous seeding or extension of contiguous infection, and carry a mortality rate of 20–60% even with appropriate medical–surgical management. In contrast, amoebic abscesses respond well to chemotherapy and rarely require drainage<sup>2</sup>. Pleural effusion arises by two mechanisms in association with amoebic liver abscess. The first occurs when an amoebic abscess produces diaphragmatic irritation and a sympathetic pleural effusion in a manner analogous to that seen with pyogenic liver abscesses<sup>3-4</sup>. Amoebic liver abscess also produce pleural effusion when the abscess ruptures through the diaphragm in to the pleural space. In this situation the pleural fluid is described as “chocolate sauce” or “anchovy paste”<sup>5</sup>.

### II. Case Reports

35 years old non alcoholic male patients presented in pulmonary medicine OPD with breathlessness and upper abdominal pain for last 10 days. On examination patients was thin built look anxious, afebrile, pulse 104/min, BP 112/72 mmHg, RR 28/min, SpO<sub>2</sub> 92% at room air. There is mild pallor and icterus was present but there was no cyanosis, clubbing or pedal edema present. On chest examination breath sound intensity was reduced right hemi thorax with stony dull note on percussion. Abdominal examination revealed tenderness right hypochondrium with hepatomegaly. Investigation revealed Hb 10.7 gm/dl, TLC 26,800/cu.mm, DLC Polymorph 88%, Lymphocyte 10%, Platelet 4,84,000/cu.mm, Serum total bilirubin 11.8 mg/dl ( serum conjugated 7.4 mg/dl, serum unconjugated 4.4mg/dl), AST/ALT 84/24 U/L, serum alkaline phosphatase 707 U/L, GGT 335U/L, Blood urea 46.00 mg/dl and creatinine 1.90 mg/dl. ELISA serology for HIV and HBsAg test were negative. Chest x-ray showed completely opaque right hemithorax (Figure 1). USG Abdomen revealed grade 1 fatty texture and a large volume about 400ml heterogeneous lesion seen in right lobe with large collection in right pleural cavity. Pleural fluid aspirated was pus, sterile on bacterial culture and smear negative for tuberculosis. Pleural fluid also sent for gene-xpert which was negative for Mycobacterium tuberculosis. Amoebic serology was negative.... A diagnosis of ruptured amoebic liver abscess with superadded infection made and immediately intercostals tube placed in right 6<sup>th</sup> intercostals space and more than one litre fluid drained. Patients put on inj Meronidazole 800mg 8hrly, Inj Amoxyclav 1.2 gm 8hrly and Inj Ciprofloxacin 500mg iv 12hrly. After 4 days of treatment Serum bilirubin came down to 3.20 mg/dl, TLC 16200/mm<sup>3</sup>. Chest tube was removed on 9<sup>th</sup> days of tube thoracostomy when drainage was <100 ml/day for two consecutive days. A contrasted enhanced CT chest reveals features suggestive of ruptured liver abscess in right lobe of liver with moderate loculated empyema with loculated hydropneumothorax (Figure 3). Follow-up chest x-ray (Figure 2) shows lung was expanded but localise hydropneumothorax present on right upper zone for which patient breathing exercise through incentive spirometer. A patient is doing quite well during follow-up.

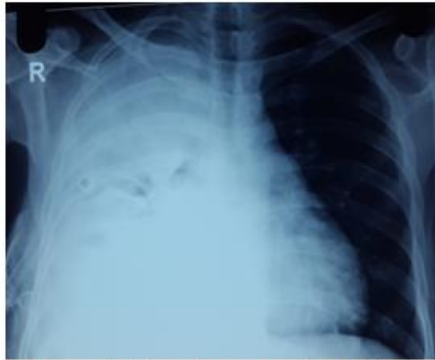
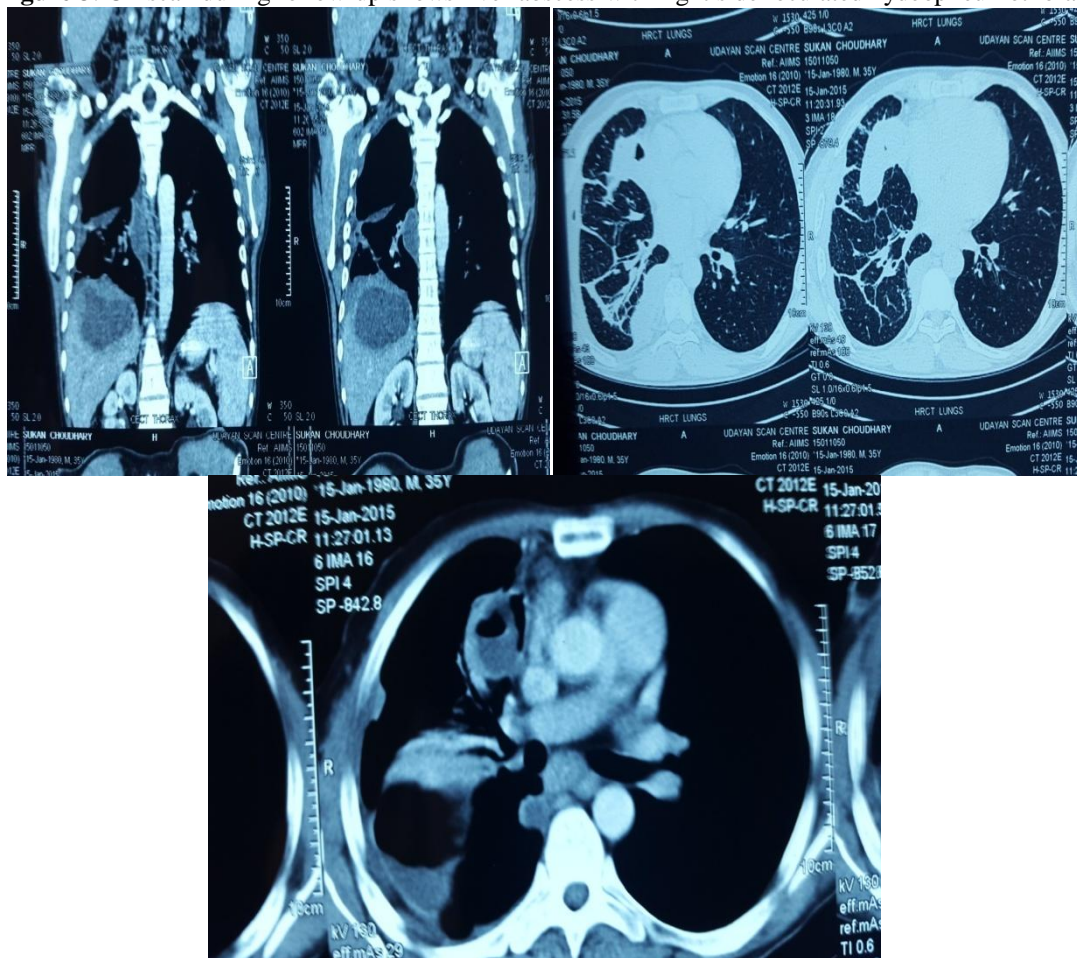


Figure 1. Showing massive right side Pleural effusion (at the time of admission)

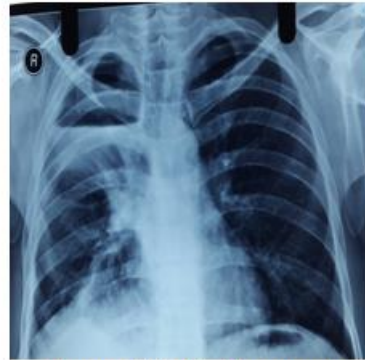

Figure 2. Right side encysted hydropneumothorax (During follow-up)

Figure 3. CT scan during follow-up shows liver abscess with right side loculated hydropneumothorax



### III. Discussion

Liver abscess (LA) is common in the tropical region like the Indian subcontinent. The common etiological agents for LA are *E. histolytica* (amoebic), bacterial (pyogenic), *Mycobacterium tuberculosis*, and various fungi. Out of them, ALA is largely a disease of developing countries like India. They tend to affect younger population especially males. In this era of mass movement of populations in and out of areas with poor sanitary conditions, more cases of Amoebic liver abscess and its thoracic complications are being seen in countries where they were previously uncommon.

It arises from the hematogenous spread of the trophozoites of *Entameba histolytica* from the intestinal mucosa to the liver through the portal vein. The disease is suspected in endemic areas in persons presenting with fever, pain abdomen and liver tenderness<sup>6</sup>. Occasionally It rupture into the pleural cavity was signaled by abrupt exacerbation of pain, sometimes a tearing sensation, followed by rapidly progressive respiratory distress and

sepsis, occasionally with shock<sup>7</sup>. These patients presented with upper abdominal pain, right side chest pain and breathlessness which is a common presenting symptoms in most of the studies<sup>8</sup>. The level of alkaline phosphatase is elevated in more than 75% of patients, whereas the levels of transaminases are elevated in 50%. Our patients also have elevated transaminases and elevated alkaline phosphatase.. Amoebic liver abscess occurs most commonly in the age group of 20 to 45 years consistent with the present case. It has also been noted infrequently at the extremes of age; men are proportionately affected, with reported male to female ratio of approximately 10:1<sup>9</sup>.) The atypical presentation in our case is massive pleural effusion causing completely right hemithorax opaque which is very uncommon presentation. The rupture is into the right pleural space in more than 90% of patients. The diagnosis of amoebic abscess with transdiaphragmatic ruptured is suggested by the discovery of anchovy paste or chocolate sauce pleura fluid on diagnostic thoracentesis. In this case tuber thoracostomy drained chocolate colour fluid which favour for amoebic pathology. Amebas can be demonstrated in the pleural fluid in fewer than 10% of patients but in our patients amebas was not demonstrated in pleural fluid. In our patients leukocytosis may suggest that patients have secondary infection and sterile pus culture might be due to prior antibiotic course. Approximately one third of patients with transhepatic rupture also have bacterial infections of their pleural space. (4).

#### **IV. Conclusion**

Amoebic liver abscess produce pleural effusion through diaphragmatic irritation or when the abscess ruptures through the diaphragm in to the pleural space. In this situation the pleural fluid is described as “chocolate sauce” or “anchovy paste. The thoracic complication of amoebic liver abscess are not uncommon but causing massive empyema which is rare finding. So we should keep differential of ruptured liver abscess even in case of massive empyema.

#### **References**

- [1]. Ochsner, M. de Bakey, and S. Murray, “Pyogenic abscess of the liver. An analysis of forty-seven cases with review of the literature,” *The American Journal of Surgery*, vol.40,no.1,pp. 292–319, 1938
- [2]. Blessmann J, Binh HD, Hung D Met al.(2003) Treatment of amoebic liver abscess with metronidazole alone or in combination with ultrasound-guided needle aspiration: a comparative, prospective and randomised study .*Tropical Medicine and International Health* 8, 1030–1034
- [3]. Ibarra-Perez C. Thoracic complication of amoebic abscess of the liver. *Chest* 1981;79:672-676.
- [4]. Cameron EWJ. The treatment of pleuropulmonary amebiasis with metronidazole. *Chest* 1978;73:647-650Cameron EWJ.
- [5]. Lyche KD, Jensen WA. Pleuropulmonary amebiasis. *Semin Respir Infect* 1977;12:106-112.
- [6]. Haque R, Huston CD, Huges M, Houpt E, Petri WA Jr: Amoebiasis: Review Article. *New Engl J Med* 2003;348:1565-73
- [7]. Ibarra-Perez C. Thoracic complications of amoebic abscess of the liver. *chest* 1981;79:647-650.
- [8]. Sharma OP, Maheshwari A. Lung diseases in the tropics. Part 2: common tropical lung diseases: diagnosis and management. *Tuber Lung Dis* 1993;74:359-370.
- [9]. Acuna-Soto R, Maguire JH, Wirth DF. Gender distribution in asymptomatic and invasive amebiasis. *Am J Gastroenterol* 2000; 95:1277-1283