

Breast Tuberculosis Rare Case Report, Can Masquerade Ca Breast

Dr Shivananda¹ (prof), Dr Ramesh Ainapure²,
^{1,2}, (Department General Surgery, Mysore Medical college/RGUHS Bangalore, India)

Abstract:

Introduction: Breast Tuberculosis is rare form Tuberculosis. Usually occurs in women between 20-50 years of age, unilateral breast involvement. Incidence is more common in underdeveloped countries as compared to developed countries. It is often missed in early presentation or presents like carcinoma breast.

Case Presentation: 48 year old woman presents with lump in the right breast located in lower inner quadrant and clinical and mammographic finding indicative of carcinoma breast. Patient underwent FNAC and excision biopsy revealed Tuberculosis. Patient received anti TB drugs for 6 months without any complications.

Conclusion: Tuberculosis breast is extremely rare. Often diagnosis as carcinoma of breast or pyogenic abscess. Its important to diagnose because it can be treated conservatively by anti tubercular drugs. Surgery can be avoided.

I. Case Presentation

A 48 Year old woman presented with history of lump in the right breast in the lower inner quadrant and two small lumps retroareolar region extending up to nipple. Lower inner quadrant mass about 31*11mm with ill defined margin at 5 o'clock position extending up to nipple. Other lump noted in retroareolar region at 3 o'clock position extending up to nipple and another small lesion about 22*11mm at 3 o'clock position just lateral to above described one, With fullness noted in lower inner quadrant on inspection, no pigmentation, no erythema, no sinus. But patient had pain in the lump since last 3 months with evening rise in temp.

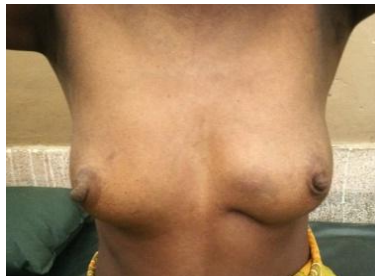

Figure 1.1 shows Nipple elevated and retracted outside and fullness noted lower inner quadrant of right breast compared to normal breast.

Clinically no lymph nodes palpable, Laboratory investigations revealed HB -12.8%, TC- 8200, ESR- 20mm/hr, HIV Negative.

Sonomammography of right breast shows ill defined, hypoechoic lesion in lower inner quadrant with retroareolar extension BIRADS 5.

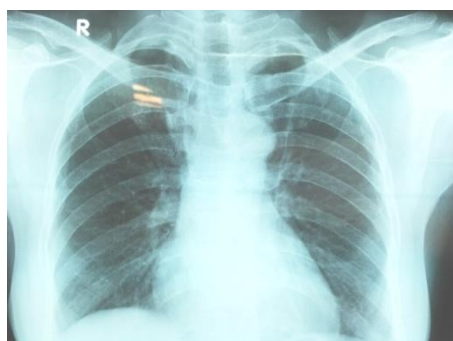


Figure 2 shows no focal lung opacity with borderline cardiomegaly.

- Mammography shows few opacities in right breast as described suspicious retroareolar lesion with bilateral small axillary lymphnodes.

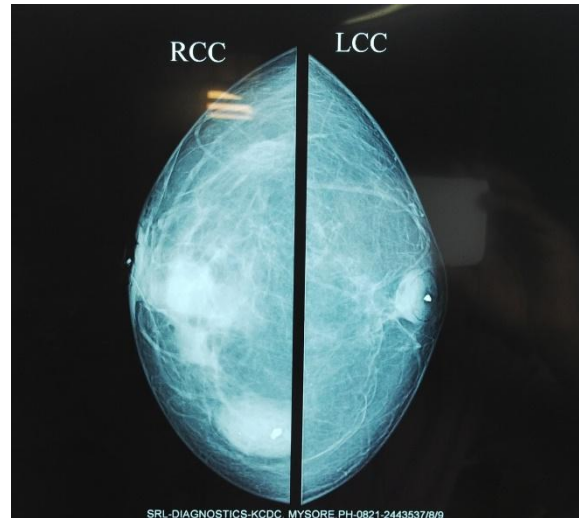


Figure 3 Irregular homogeneous opacity noted in lower inner quadrant extending to retroareolar region right breast- suspicious. Another well defined lesion in lower inner quadrant. Small microcalcification noted in central region.

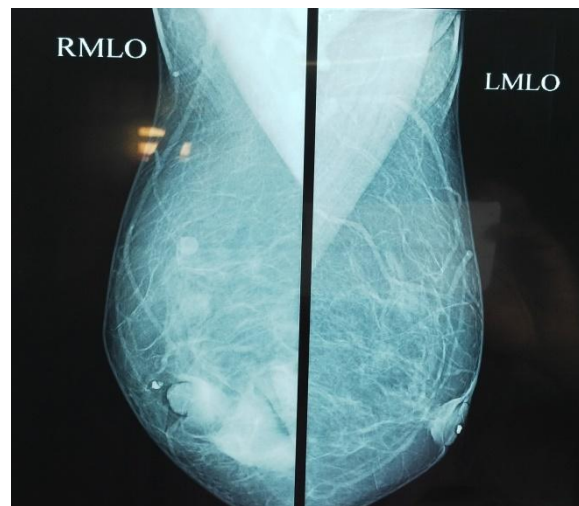


Figure 4 shows small well defined opacity in upper outer quadrant.

- Thoracic CT could not revealed any lung pathology.
- FNAC –yielded whitish pus like material and smear shows many epithelioid cell granulomas with langhans type giants cells and caseous necrosis.

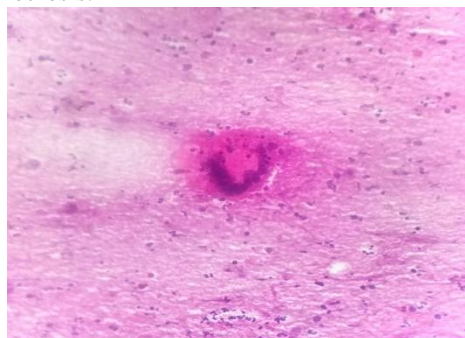


Figure 5 showing langhans type of multinucleated gaint cell.

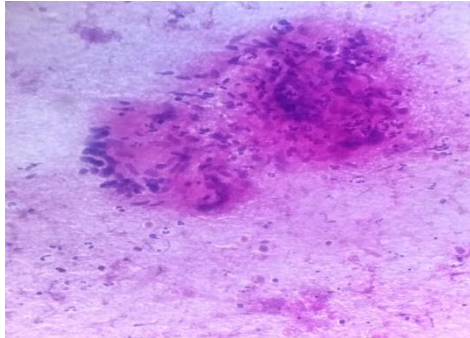


Figure 6 showing cluster epithelioid cells forming granuloma.

II. Case Discussion

First case of breast tuberculosis – Sir Astely Cooper who describe it as “scrofulous swelling of the bosom” and breast TB is very rare entity. Incidence is very less 0.1% in all breast lesions in western countries and 3-4% in endemic regions like India and Africa. Most common presentation is upper and outer quadrant. Clinically may miss diagnosis as carcinoma Breast or pyogenic abscess due to lump is hard and irregular. Might be fixed to chest wall or skin⁵.

Tissues like Breast, skeletal muscles and Spleen are resistant to infection, bacilli survival and multiplication is very difficult[5]. The disease is more frequently seen in women between 20 and 50 years of age, especially among multiparous and lactating females where the breast is more sensitive to infection and trauma. Tuberculous mastitis may be primary, although this is extremely rare¹, or secondary as a result of hematogenous spreading, retrograde spread from axillary lymph nodes or direct extension from the lung, pleura, mediastinum and articular lesions^{1,2}.

The three main features of breast TB are nodular, disseminated and sclerosing, and these features result in multiple discharging sinuses, lumps, ulcers and recurring abscesses of the breast are observed¹. Clinical presentation is extremely variable, often presenting as round nodular lumps mainly in the upper outer quadrant of the breast³. But in our case it was reported that lumps found one lower inner quadrant and two others in retroareolar region..

In our case it was reported that, clinical examination failed to differentiate breast carcinoma from tuberculous breast. The age of the patient, the non-specific findings of mammography and ultrasonography, as well as a low index of suspicion resulted in an incorrect preliminary diagnosis. Additionally, fine needle aspiration biopsy or excision biopsy was performed, which revealed tuberculosis. The patient underwent Anti-tuberculosis therapy, consisting of the same regimen used in pulmonary tuberculosis^{4,5}.

III. Conclusion

Breast tuberculosis is considered a rare entity. But still increasing in endemic area like India, so clinical awareness is essential when treating non-specific breast lesions in these endemic areas. Diagnosis can be established by fine needle aspiration cytology or histology while antitubercular therapy represents the mainstay of treatment, avoiding unnecessary surgical intervention.

Surgery is reserved for selected refractory cases only. [6,7].

References

- [1]. Zandrino F, Monetti F, Gandolfo N: Primary tuberculosis of the breast. A case report. *Acta Radiologica* 2000, 41:61-63.
- [2]. Oh KK, Kim JH, Kook SH: Imaging of tuberculous disease involving breast. *Eur Radio* 1998, 8:1475-1480.
- [3]. Shukla HS, Kumar S: Benign breast disorders in non-western populations: Part II – Benign breast disorders in India. *World J Surg* 1989, 13:746-749
- [4]. Kalac N, Ozkan B, Bayiz H, Dursum AB, Demirag F: Breast tuberculosis. *Breast* 2002, 11:346-349.
- [5]. Tewari M, Shukla HS: Breast Tuberculosis: diagnosis, clinical features and management. *Indian J Med Res* 2005, 122:103-110.
- [6]. Khanna R, Prasanna GV, Gupta P, Kumar M, Khanna S, Khanna AK: Mammary tuberculosis: report on 52 cases. *Postgrad Med J* 2002, 78:422-424.
- [7]. Harris SH, Khan MA, Khan R, Haque F, Syed A, Ansari MM: Mammary tuberculosis: analysis of thirty-eight patients. *ANZ J Surg* 2006, 76:234-237.