

A Surgical Approach to Restore the Unrestorable-Case reports

Dr. Apoorva Khullar¹, Dr. Manish Agarwal², Dr. M.P Singh³, Dr. Pavithra⁴,
Dr. Niharika Mishra⁵,

^{1, 2, 3, 4, 5}(Dept. of conservative & Endodontics, People's college of dental science & RC, People's University, India)

Abstract: With time the treatment modalities have evolved from a non conservative approach to an era of conservation and preservation of tooth structure for its better function and retention in the arch for a longer duration as a functionally active unit. Patients also desire to conserve teeth which are deemed to have a questionable prognosis. Teeth having severe bone loss involving the furcation area and poor periodontal conditions can be retained in the oral environment by the various alternative procedures for their management. The present article will deal with the already established treatment procedures like bicuspidization which involves the splitting of the multirooted tooth along with the crown which serves as single unit into the separated double unit. The second modality is root resection which involves the complete removal of only the root portion of a multirooted tooth.

Keywords: Bicuspidization, Bisection, Root resection, Root separation, Radisection, Radisectomy, Furcation involvement.

I. Introduction

In the twenty first century, advancements in dentistry are evolving as a boon for the preservation of the hopeless tooth by surgical management of the dentition/teeth in order to maintain the teeth in the arch for its better function and esthetics. Molars act as pillars and bear the maximum load in the dental arch. These are one of the first permanent teeth to arrive in the oral cavity and remain for the longest duration. When these teeth are affected by caries or periodontal disease with severe furcal involvement, surgical interventional procedures like bicuspidization and root resection may help in conservation and maintenance of such teeth. Bicuspidization is the separation of mesial and distal roots of mandibular molars along with its crown portion, where both segments are then retained individually. Root resection/amputation refers to removal of one or more roots of multirooted tooth while other roots are retained.^[1] These procedures conserve as much tooth structure with minimal possible damage to tooth. This article deals with the multidisciplinary approach to preserve such teeth in the oral environment.

Indications for bicuspidization are following: [1],[2],[3] Fractures in the root, when regenerative procedures fail in treating cases of severe bone loss involving one or more roots, furcation pathologies, unrestorable tooth structure, severe root proximity, inadequate embrasure space, root trunk fracture or decay with invasion of the biological width. Contraindications include: [1],[2],[3] poor oral hygiene, fused roots, unfavourable tissue architecture and retained roots.

Indications for root resection are: [4],[5],[6] Teeth which are difficult to maintain like grade iii furcation involvement, severe gingival recession around a single root, close root proximity with minimal interdental bone (commonly seen between the maxillary first and second molars), root resorption and perforation and severe vertical bone loss with one or more roots.

II. Case Report: Bicuspidization

A 23 year old male patient reported to the Department of Conservative Dentistry and Endodontics of People's College of Dental Sciences and Research Centre with a chief complaint of pain and in the lower right back tooth region since last 15 days. On oral examination, deep occlusal carious lesion was seen in relation to 46 (Fig 1). The tooth was tender on percussion. On radiographic examination the carious lesion was seen extending till the furcation area and widening of the lamina dura were seen (Fig 3). The pulp testing was done before starting the treatment and the tooth was observed to be non-vital. The diagnosis for this case was determined to be a primary endodontic lesion with secondary periodontal involvement. The treatment procedure planned was root canal therapy followed by bicuspidization. Access opening was done, working length determined followed by cleaning and shaping of the canal using crown down method till Protaper F2 file in all the four canals and obturated. This was followed by post endodontic restoration with nanohybrid composite. (fig 4). Flap reflection (fig 2) was done and a long shank tapered fissure bur was used to completely separate the two root portions involving the furcation area (fig 5). Copious irrigation was done to remove the debris. Interdental sutures were given (fig 6) and the trimmed tooth structure was restored using a nanohybrid composite resin as the core material. (fig 7). Two separate metal crowns were placed on both the fragments. (fig 7 & fig 8).

III. Case Report: Root Resection

A 42 year old male patient reported to the Department of Conservative Dentistry and Endodontics of People's College of Dental Sciences and Research Centre with a chief complaint of food lodgement and pain on mastication in the lower right back tooth region since last 5 days. On oral examination a deep pocket involving the mesial root was seen (fig 9). On radiographic examination root caries was seen in relation to the mesial root of 46. The root defect was not restorable as it was sub gingival in extent. It was diagnosed as a primary endodontic lesion with secondary periodontal involvement. The treatment procedure planned involved root canal therapy followed by root resection. The access cavity was done, working length determined and cleaning and shaping of the canal was done using crown down method till F3 protaper file in the distal half and obturated. Post endodontic restoration was done using a nanohybrid composite. The flap was reflected on the buccal side as more bone loss as was seen with respect to mesial root of 46 (fig 10). Apical bone was removed and root resection was done on the mesial root of the 46 (fig 11 & fig 12). After the root resection, a periodontal pack was given for 10 days and sutures were given (fig 13). Pre and post operative IOPAR are as follows (fig 14 & fig 15). Patient was prescribed analgesics and antibiotics and recalled after 15 days for follow up and referred for the prosthetic restoration.

IV. Figures

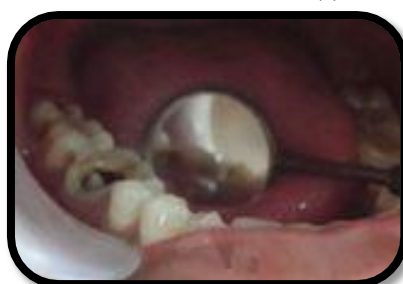

Fig.1

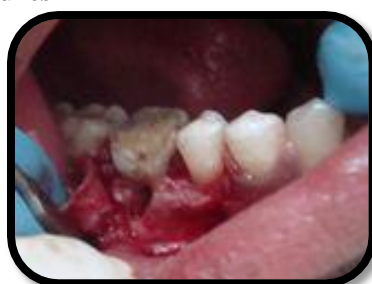

Fig.2

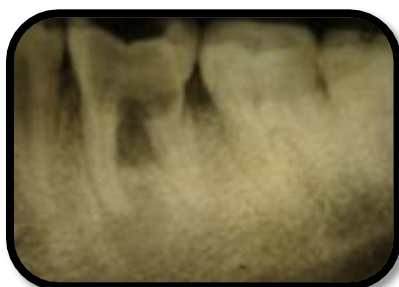

Fig.3

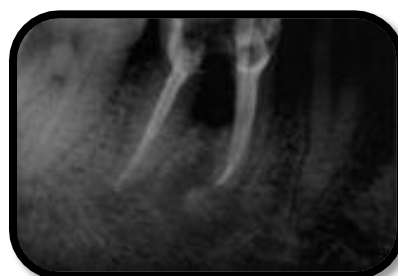

Fig.4

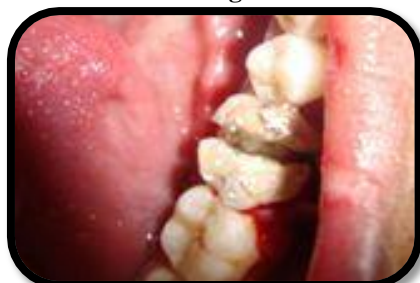

Fig.5

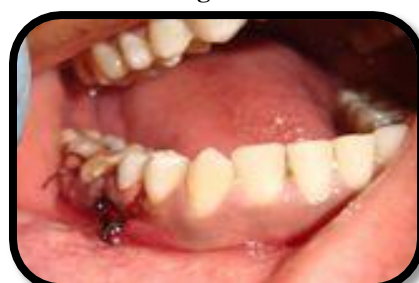

Fig.6

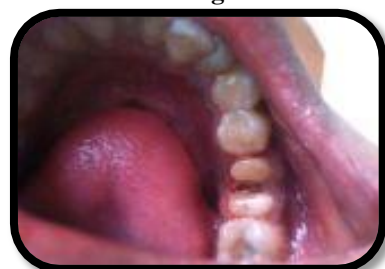

Fig.7

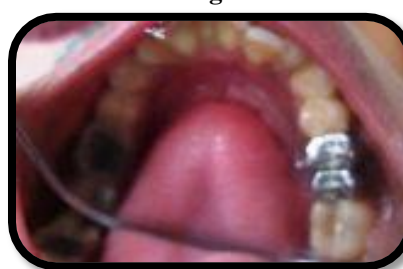

Fig.8

- Fig 1:** Intra-OP view
- Fig 2:** Flap reflection
- Fig 3 & Fig 4:** Pre& Post OP IOPAR
- Fig 5:** Splitting of tooth
- Fig 6:** Suturing of flap
- Fig 7:** Two separate premolars
- Fig 8:** Metal crown cementation

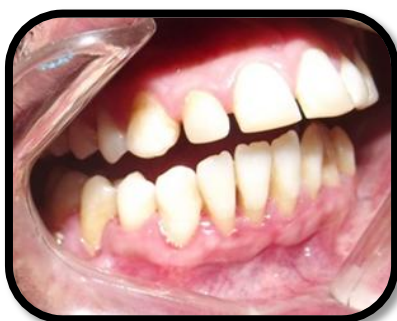

Fig.9

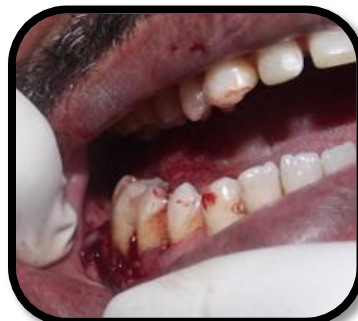

Fig.10

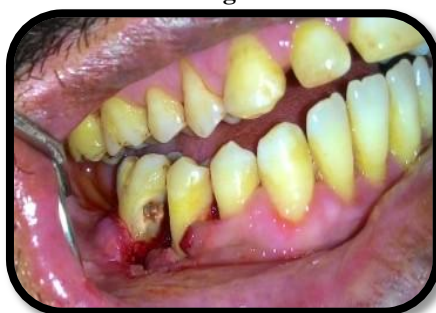

Fig.11

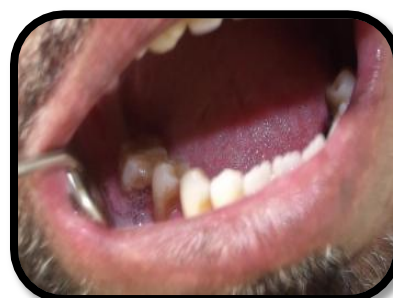


Fig.12

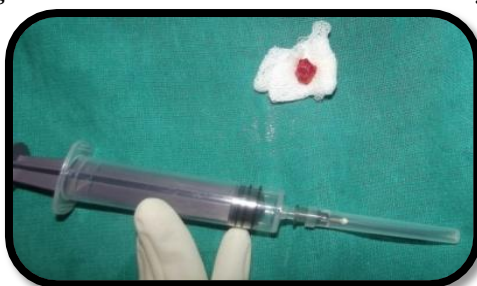

Fig.13

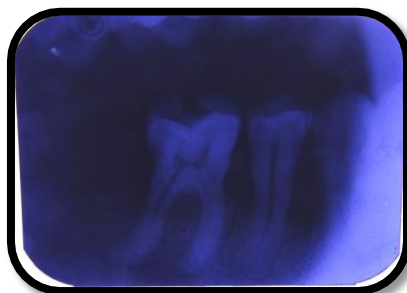


Fig.14

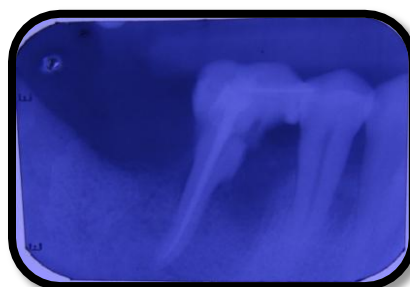


Fig.15

- Fig 9:** Intra-OP view
- Fig 10:** Flap reflection
- Fig 11& Fig 12:** Root resection
- Fig 13:** Resected root
- Fig 14 & Fig15:** Pre&Post-OP IOPAR

V. Discussion

Endodontic surgical procedures are considered to be of prime importance for the treatment and management of teeth and roots with periradicular diseases. The scope of endodontic surgery is not just limited to apical portion but to a greater extent into periradicular areas also.

Hemi section refers to procedures involving sectioning of the crown of the teeth or the removal of half crown and its root or the retention of both the halves which will act as two premolars.^[11] Root resection consists of entire removal of the root portion without the removal of the crown portion these condition may occur when there is vertical fracture, gross periodontal disease, or extensive inflammatory destruction. There are some situations where non surgical approaches are not feasible so these cases are indicated for surgical approaches to preserve the remaining tooth structure.^[10]

Root separation or resection has been used successfully to retain teeth with furcation involvement.^{[7],[8]} Root surfaces that are reshaped by grinding in the furcation or at the site of hemisection are more susceptible to caries and hence very often a favourable result may be negated by decay after treatment if the patients don't maintain their oral hygiene properly.^{[12],[13],[14]} Failure of endodontic therapy due to any reason will cause failure of the procedure.^{[5],[6]} In addition, when the tooth has lost part of its root support, it will require a restoration to permit it to function independently or to serve as an abutment for a splint or bridge. The procedure involving the root resection of the tooth even depends upon the type of case selection. Both of the above mentioned cases have shown good prognosis. Both treatment modalities have proven to show a higher success rate in preserving the tooth.

VI. Conclusion

Bicuspidization and root resection are the treatment modalities which will enhance the preservation of the natural tooth in the field of dentistry. This is a conservative approach to restore the lost tooth structure and involves multidisciplinary approach for its success rate to be enhanced. According to all the above mentioned findings it can be concluded that endodontic surgical procedures are a viable option for the preservation of compromised teeth.

References

- [1]. Vandersall DC, Detamore RJ. The mandibular molar Class III furcation invasion. A review of treatment options. *J Am Dent* 2002; 133: 55-60.
- [2]. Tarnow D, Fletcher P. Classification of the vertical component of furcation involvement. *J Periodontol* 1984; 55:283-84.
- [3]. Frankl S, Weine. *Text book of Endodontology*. Sixth edition.
- [4]. Parmar G, Vashi P. Hemisection: A case report and review. *Endodontol* 2003; 15:26-9.
- [5]. *American Academy of Periodontology*. Glossary of Periodontal Terms. Chicago: *American Academy of Periodontology*; 2001:45.
- [6]. Farrar JM. Radical and heroic treatment of alveolar abscess by amputation of roots of teeth. *Dental Cosmos* 1884;26:79.
- [7]. Simon J.H.S., Glick, D.H., and Frank, A.L. The relationship of endodontic-periodontic lesions. *J Periodontol*.1972;43:202-208.
- [8]. Pontoriero R, Lindhe J, Nyman S, Karring T, Rosenberg E, Sanavi F. Guided tissue regeneration in the treatment of furcation defects in mandibular molars: a clinical study of degree III involvements. *J Clin Periodontol* 1989; 16:170-4.
- [9]. Becker W, Becker BE, Berg L, Prichard J, Caffesse R, Rosenberg E. New attachment after treatment with root isolation procedures: report for treated Class III and Class II furcations and vertical osseous defects. *Int J Periodontics Restorative Dent* 1988;8(3):8-23.
- [10]. Saxe SR, Carman DK. Removal or retention of molar teeth: the problem of the furcation. *Dent Clin North Am* 1969; 13: 783-790.
- [11]. Gutmann's. *Textbook of surgical endodontics*, first edition 1999.
- [12]. Grossman's. *Textbook of endodontic therapy*, eleventh edition. 1988.
- [13]. John S Rhodes. *Textbook of advanced endodontics*, first edition 2006.
- [14]. TR PittFord. *Textbook of endodontic problem solving in clinical practice*, first edition 2002.
- [15]. Gunnar Bergenholtz. *Textbook of endodontology*, second edition 2010.