

## A Study Of Bone Gap Reconstruction By Rail Fixator System

Dr. K. Ramachandra<sup>1</sup>, Dr. Virupaksha Reddy S.P<sup>2</sup>, Dr. Dhameliya Niravkumar<sup>3</sup>,  
Dr. Harsha Ganesuni<sup>4</sup>, Dr. V N Suneel Kumar Munaga<sup>5</sup>, Dr. Anirudh. C. K<sup>6</sup>,

<sup>1</sup>Associate Professor and Head of Unit, Department of Orthopaedics, Navodaya Medical College, Rajiv Gandhi University, India

<sup>2,6</sup> Assistant professor, Department of Orthopaedics, Navodaya Medical College, Rajiv Gandhi University, India

<sup>3,4,5</sup> Resident Doctor, Department of Orthopaedics, Navodaya Medical College, Rajiv Gandhi University, India

**Abstract: Background:** Bone loss following open fracture or infected gap nonunion is a difficult situation to manage. There are many modes of treatment such as bone grafting, vascularized bone grafting and bone transport by ilizarov and monolateral fixator. We evaluated the outcome of rail fixator treatment in reconstructing bone and limb function. We felt that due to problems such as heavy apparatus, persistent pain, deformity of joints and discomfort caused by an Ilizarov ring fixator, rail fixator is a good alternative to treat bone gaps.

**Materials and Methods:** 20 patients (17 males and 3 females with mean age 30.5 years) who suffered bone loss due to open fracture and chronic osteomyelitis leading to infected gap nonunion. Ten patients suffered an open fracture (Gustilo type II and type III) and 10 patients suffered bone gap following excision of necrotic bone after infected nonunion. There were 20 cases of tibia. All patients were treated with debridement and stabilization of fracture with a rail fixator. Further treatment involved reconstructing bone defect by corticotomy at an appropriate level and distraction by rail fixator.

**Result:** We achieved union in all cases. The average bone gap reconstructed was 5.0 cm (range 3.5-7.5 cm) in 9 months (range 6-14 months). Normal range of motion in nearby joint was achieved in 80% cases. We had excellent to good limb function in 85% of cases as per the association for the study and application of the method of ilizarov scoring system [ASAMI] score.

**Conclusion:** All patients well tolerated rail fixator with good functional results and gap reconstruction. Easy application of rail fixator and comfortable distraction procedure suggest rail fixator a good alternative for gap reconstruction of limbs.

**Keywords:** Bone loss, corticotomy, infected nonunion, rail fixator

### I. Introduction

High velocity trauma has caused increased number of cases with open fracture and their treatment and complication has increased drastically.<sup>1</sup> Open fracture<sup>2</sup> itself is one of the most common cause for segmental loss of bone.<sup>3</sup> Treatment of bone gap due to infected nonunion and open fracture is very interesting and controversial topic in orthopaedics due to factor such as poor vascularity of surrounding tissue, deformity of joints, limb length discrepancy and scarring of skin due to previous surgeries. There are many modes of treatment advocated by different authors from time to time such as bone grafting, vascularized bone grafting, and bone transport by ilizarov and monolateral fixator.<sup>3,12</sup> For treating bone gap when Ilizarov ring fixator is used, it achieves union, eradicates infection, corrects deformities, reestablishes limb length and at the same time maintains function. The successful results achieved by Ilizarov ring fixator bears a testimony to the success of this system. But due to many complications such as persistent pain, deformity of joints and discomfort caused by Ilizarov ring fixator, inspired the development of rail fixator. This study was performed to assess the role of bone transport by rail fixator (PITKAR, INDIA) in treatment of bone gap in long bones due to open fracture and infected nonunion.

### II. Materials and methods

A Retrospective and Prospective study for 20 cases (17 male and 3 females with mean age of 30.5 years), (range 17-44 years) was conducted in Raichur institute of medical sciences, Raichur, Karnataka (RIMS) and Navodaya medical college hospital & Research centre Raichur, Karnataka (NMCH&RC) From 2005-2014 of infected gap nonunion of long bones with bone loss due to open fracture and chronic osteomyelitis were included in study [Table 1]. In All cases, rail fixator was applied on tibia. Six cases had active sinuses with raised C-reactive protein levels. All patients in present study had previous operative procedures performed on them. 12 patients had an average of two procedures and remaining 8 had three procedures. The average bone gap in this series was 5.0 cm (range 3.5-7.5 cm). This bone gap was either created at the time of injury or after thorough debridement following compound fracture or sequestrectomy. This study plan was approved by our

institutional review board. Informed written consent was taken from all patients. The preoperative medical evaluation of all patients was done. The culture and sensitivity of discharge was sent preoperatively. The neurovascular status of limb was assessed preoperatively. All patients were treated with debridement and application of rail fixator in the same sitting. According to site of defect, appropriate corticotomy was done after settlement of wound to decrease the chance of infection at corticotomy site and it was done at second stage in all cases. Corticotomy was done at single level. Joint motion was started as early as possible after the operation. Transport was commenced after 5-7 days of corticotomy. Rate of transport was 1.00 mm/day in 4 divided increments. At the conclusion of transport, the defect was closed by removing soft-tissue at docking site and giving compression between the bone ends in all cases. Partial weight bearing was started at conclusion of transport. Consolidation of docking site was monitored by serial antero posterior and lateral X-rays. Bone grafting was done in Ten cases when it was found callus formation was not adequate at docking site. Full weight bearing was advised when three distinct and complete cortices of regenerate were evident on serial X-ray.

**Table 1: Details of patients**

Age (in years)	Gender	Etiology	Bone gap (cm)	Duration of treatment	Complications	ASAMI
18	Male	Open fracture	3.5	07	None	Excellent
42.5	Male	Infected NU	7.0	06	None	Excellent
28	Female	Open fracture	5.2	11	Pintract infection	Good
24	Male	Open fracture	3.4	09	None	Excellent
33	Male	Open fracture	3.7	14	Pintract infection	Fair
37	Male	Infected nonunion	5.4	09	None	Good
40	Female	Infected nonunion	5.1	06	None	Excellent
25	Female	Open fracture	6.4	06	None	Good
33	Male	Infected nonunion	3.9	08	None	Good
41	Male	Infected nonunion	5.6	12	None	Good
24	Male	Open fracture	7.5	07	None	Excellent
31	Male	Open fracture	4.5	06	None	Good
20	Male	open fracture	6.5	05	None	Excellent
28	Male	Infected nonunion	3.5	11	None	Excellent
30	Male	Infected nonunion	5.0	12	Pintract infection	Fair
44	Male	Infected nonunion	4.5	7	None	Excellent
36.5	Male	Infected nonunion	6.7	10	None	Excellent
21	Male	Open fracture	5.1	10	None	Good
36	Male	Infected nonunion	3.5	08	None	Good
17	Male	Open fracture	4.0	10	None	Excellent

### III. Results

Average duration of rail fixator application was 9 months (range 6-14 months). Partial weight bearing on operated limb was started as soon the distraction complete and full weight bearing was done after complete union. Pin loosening was the only complication in three cases. We removed loosened pin in one case as it was not compromising with stability of fixator. In other two pins were inserted again. Loss of range of motion in nearby joint was more in patients with pins close to joint surface, but returned to normal in 80% of cases. Average follow up period was 12 months (range 12-14 months). The result was excellent to good in 85% cases as per ASAMI score [Table 2 and 3].

**Table 2: ASAMI Score**

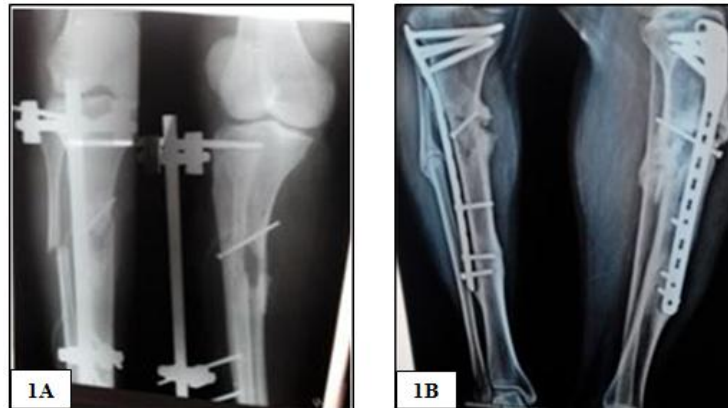
EXCELLENT	
Bone Union	Ability to perform previous activities of daily living
No infection	No pain or mild pain, no limp, no soft tissue sympathetic dystrophy
Deformity $\leq 7^\circ$	Knee or ankle joint contracture $\leq 5^\circ$
Limb length discrepancy $\leq 2.5$ cms	Loss of ankle /knee motion $\leq 15^\circ$
GOOD	
Bone union	Almost all ADL with minimal difficulty
Failure to meet one of the above criteria	No pain or mild pain
	Failure to meet one of the other criteria
FAIR	
Bone union	Most ADL with minimal difficulty
Failure to meet two of other criteria	No pain or mild pain
	Failure to meet two of other criteria
POOR	
Non union or refracture	Significantly limited ADL
Failure to meet three of other criteria	Significant pain requiring narcotics
	Failure to meet three of other criteria

**Table 3: Results according to ASAMI Score**

Results	No. of cases	Percentage of age
Excellent	10	45.00
Good	8	40.00

Fair	2	10.00
------	---	-------

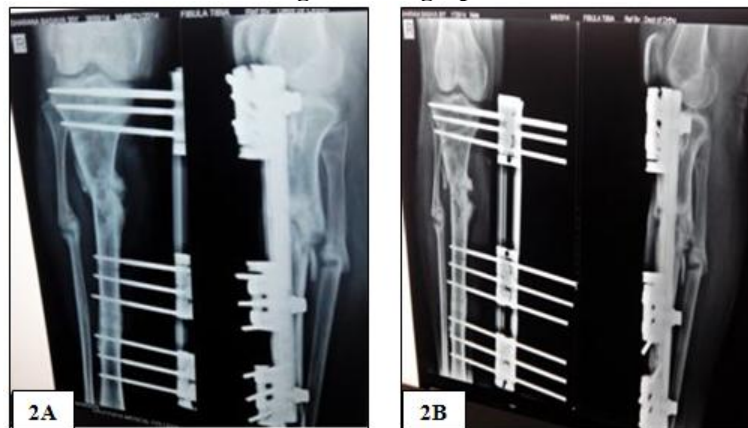**Fig. 1: Radiographs**



**Fig 1A:** X ray of right leg anteroposterior and lateral view showing compound fracture both bone leg with loss of butterfly fragment of tibia with External fixator insitu.

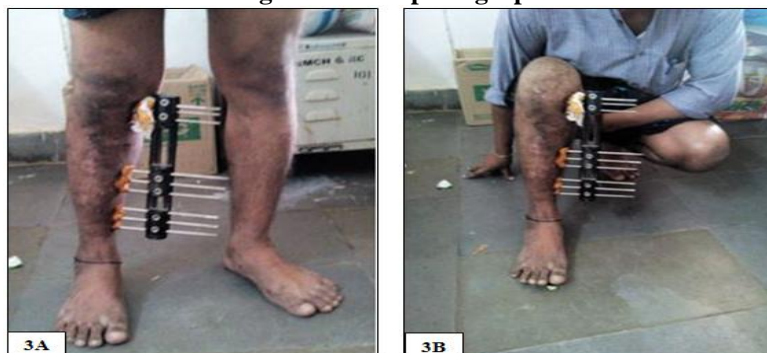**Fig 1B:** X ray of right leg anteroposterior and lateral view showing definitive secondary procedure open reduction internal fixation with plating and bone grafting.

**Fig. 2: Radiographs**



**Fig 2:** X ray anteroposterior and lateral view of right leg showing (2A) immediate post operative with rail fixation (2B) 3<sup>rd</sup> month post op showing regenerate consolidation and docking.

**Fig. 3: Clinical photographs**



**Fig 3:** Clinical photographs showing (3A) Tibia postoperative with rail fixator with full weight bearing (3B) range of motion at knee and ankle with rail fixator.

#### IV. Discussion

Iizarov since 1951 has studied the effect of fracture stabilization and subsequent reconstruction of injured limb by using ring fixator,<sup>5</sup> a circular device that is fixed to the limb with combination of wires and half pins. He studied the effects of gradual stretching of tissue by distraction and its effect on stimulation of tissue

growth and regeneration. Based on this basic principle, he developed the concept of Distraction Histogenesis.<sup>6</sup>

For last so many years Ilizarov ring fixator is being used in patients with bone loss and infected nonunion to help achieving union, correction of deformities, reestablishment of limb length and at the same time maintaining limb function.<sup>7</sup> The successful results achieved by Ilizarov ring fixator bear a testimony to the success of this system. However, due to certain complications<sup>8</sup> such as heavy apparatus, persistent pain, deformity of joints and discomfort caused by Ilizarov ring fixator inspired the development of monolateral frame devices. Rail Fixator<sup>9,10</sup> is one such device. The rail fixator is relatively simple to apply and patient compliance is very good when compared with Ilizarov fixator.

The Rail Fixation System is designed primarily for bone transport for reconstructing bone loss following open fracture and sequestrectomy following osteomyelitis. This system provides correction in these situations through the techniques of bone transport, compression-distraction and bifocal lengthening. Majority of patients in our study were in the age group of 17-44 year, as they have more active lifestyle and outdoor activities, hence more prone to injuries. The age group matches as in other series. Most commonly involved bone was tibia, as it is more prone to injury due to its subcutaneous location. Most of series mentioned in literature about distraction histogenesis are on tibia.<sup>4,8,11,13</sup> Loss of range of motion was more in cases where pins were close to joint surface. But range of motion returned to normal in most of cases after proper physiotherapy.<sup>12,14</sup> Pin loosening was the only complication seen in three cases due to pin track infection necessitating removal of infected pin. After removal of pin, it was found that the other two pins were giving sufficient stability so we did not reinsert pin. Pin loosening mainly occurred in patients with scarred skin which was used as insertion site. Despite many obstacles, rail fixator provided a reliable method to treat bone gap and achieve union. But filling of bone gap and union does not guarantee good functional result. The functional result is affected by condition of the nerve, muscles, vessels, joints, and lesser degree to bone. Functional results of the limb were assessed at end of completion of procedure using ASAMI score<sup>14</sup> [Table 2]. We were able to achieve 85% excellent to good result. Our result was comparable to studies quoted in literature for bone transport using rail<sup>10,11</sup> and Ilizarov circular ring fixator.<sup>15-18</sup>

## V. Conclusion

In cases with bone loss due to open fracture and infected nonunion, rail fixator is a good option to achieve union and to restore limb length and function. Rail fixator was well tolerated by all patients proving it to be a good alternative to ilizarov. However, patient education for compliance is must before deciding to go ahead with this procedure, as it may take several months to achieve the desired results.

## References

- [1]. TOLÓN-BECERRA A, LASTRA-BRAVO X, FLORES-PARRA I. NATIONAL AND REGIONAL ANALYSIS OF ROAD ACCIDENTS IN SPAIN. *TRAFFIC INJ PREV* 2013;14:486-95.
- [2]. Wani N, Baba A, Kangoo K, Mir M. Role of early Ilizarov ring fixator in the definitive management of type II, IIIA and IIIB open tibial shaft fractures. *Int Orthop* 2011;35:915-23.
- [3]. Dinh P, Hutchinson BK, Zalavras C, Stevanovic MV. Reconstruction of osteomyelitis defects. *Semin Plast Surg* 2009;23:108-18.
- [4]. Ashman O, Phillips AM. Treatment of non-unions with bone defects: Which option and why? *Injury* 2013;44 Suppl 1:S43-5.
- [5]. Pemberton C, Swanepoel S. Ilizarov fixation. *Br J Theatre Nurs* 1993;3:4-5.
- [6]. Catagni MA, Guerreschi F, Holman JA, Cattaneo R. Distraction osteogenesis in the treatment of stiff hypertrophic nonunions using the Ilizarov apparatus. *Clin Orthop Relat Res* 1994;301:159-63.
- [7]. Saleh M, Royston S. Management of nonunion of fractures by distraction with correction of angulation and shortening. *J Bone Joint Surg Br* 1996;78:105-9.
- [8]. Ramos T, Karlsson J, Eriksson BI, Nistor L. Treatment of distal tibial fractures with the Ilizarov external fixator – A prospective observational study in 39 consecutive patients. *BMC Musculoskelet Disord* 2013;14:30.
- [9]. Noonan KJ, Leyes M, Forriol F, Cañadell J. Distraction osteogenesis of the lower extremity with use of monolateral external fixation. A study of two hundred and sixty-one femora and tibiae. *J Bone Joint Surg Am* 1998;80:793-806.
- [10]. Sangkaew C. Distraction osteogenesis of the femur using conventional monolateral external fixator. *Arch Orthop Trauma Surg* 2008;128:889-99.
- [11]. Wang XG, Wang W, Wang XY, Lü L, Wang GQ, Ma QS, et al. One stage treatment of infected tibial defects combined with skin defects with Ilizarov technique. *Zhongguo Gu Shang* 2010;23:422-5.
- [12]. Barker KL, Lamb SE, Simpson AH. Functional recovery in patients with nonunion treated with the Ilizarov technique. *J Bone Joint Surg Br* 2004;86:81-5.
- [13]. Farmanullah, Khan MS, Awais SM. Evaluation of management of tibial non-union defect with Ilizarov fixator. *J Ayub Med Coll Abbottabad* 2007;19:34-6.
- [14]. Barker KL, Lamb SE, Simpson HR. Recovery of muscle strength and power after limb-lengthening surgery. *Arch Phys Med Rehabil* 2010;91:384-8.
- [15]. Shahid M, Hussain A, Bridgeman P, Bose D. Clinical outcome of the Ilizarov method after an infected tibial non union. *Arch Trauma Res* 2013;2:71-5.
- [16]. Madhusudhan TR, Ramesh B, Manjunath K, Shah HM, Sundaresh DC, Krishnappa N. Outcomes of Ilizarov ring fixation in recalcitrant infected tibial non-unions-a prospective study. *J Trauma Manag Outcomes* 2008;2:6.
- [17]. Chaddha M, Gulati D, Singh AP, Singh AP, Maini L. Management of massive posttraumatic bone defects in the lower limb with the Ilizarov technique. *Acta Orthop Belg* 2010;76:811-20.
- [18]. Lakhani A, Singh D, Singh R. Outcome of rail fixator system in reconstructing bone gap. *Indian Journal of Orthopaedics*, November 2014, vol 48, issue 6, 612-616.