

Primary Pulmonary Hypoplasia Masquerading As Cystic Bronchiectasis In An Adult

Dr K.Venkata Ramana

I. Introduction:

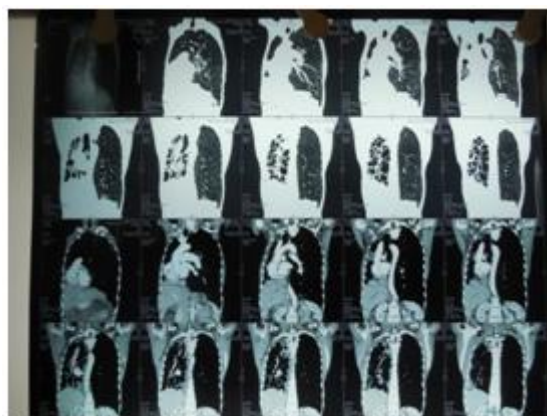A rare development anomaly, characterized by under development of lower respiratory tract resulting in fibrosis and malfunctioning of lung. Thoracic congenital malformations may go unnoticed until adulthood. The developmental anomalies of lung at the 4th and 24th weeks may cause Broncho Pulmonary Foregut abnormalities. Congenital anomalies are increasingly diagnosed in the adulthood, as they mimic other thoracic pathologies or asymptomatic in the childhood. This article presents a case of primary pulmonary hypoplasia which masqueraded as cystic bronchiectasis, hence misdiagnosed for several years.

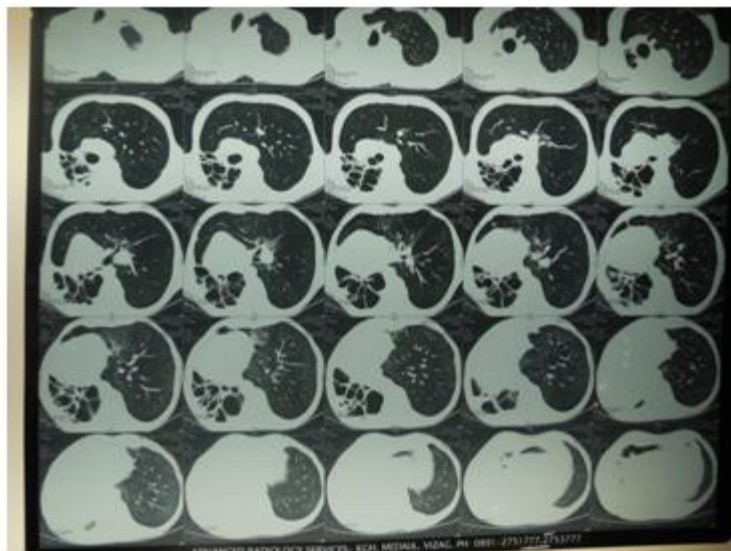
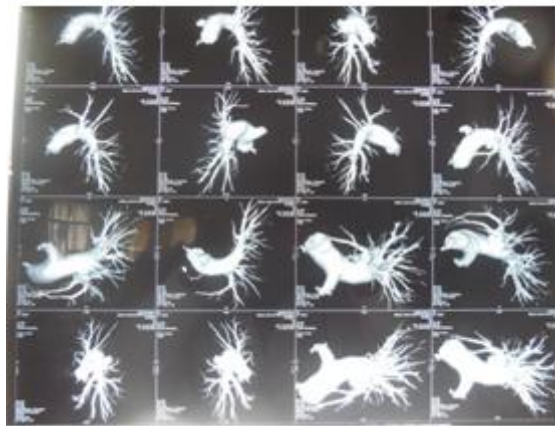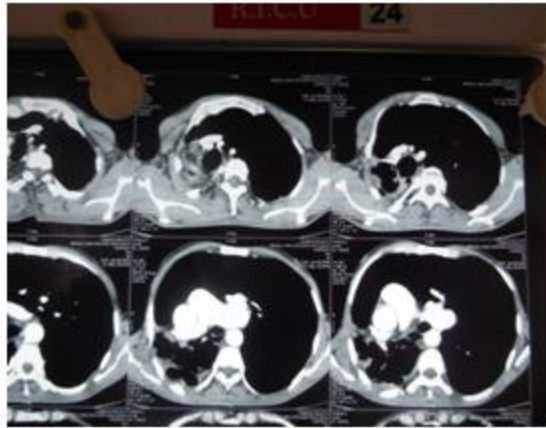
II. Case Report:

A 30 year old, nonsmoker, male patient presented with complaints cough, expectoration which is more in left lateral position, shortness of breath and right side chest pain since 1 month. He had similar complaints since 16 years and being treated under the provisional diagnosis of right total lung cystic bronchiectasis of congenital etiology.

On examination, there is grade-I clubbing of the fingers, right sided tracheal and mediastinal shift with gross loss of lung volume. Apex beat is located half an inch medial to midclavicular line on the right side. Breath sounds are diminished and coarse crepitations are heard on the right side of the chest.

Chest X-ray revealed cystic changes on the right side with ipsilateral mediastinal and tracheal and tracheal shift with compensatory hyperinflation on the left side. Spirometry was suggestive of severe obstructive and restrictive abnormality, HRCT Chest revealed right lung volume loss with multiple thin and thick walled intercommunicating cystic areas connected to lobar bronchus with no evidence of identifiable lung parenchyma. There is decreased caliber of lobar bronchi on right side with herniation of left upper lobe parenchyma into right hemithorax. 2DEcho was done which is suggestive of situs solitus with Dextroposition of heart with mild PAH and mild TR. As the HRCT chest findings suggestive of right pulmonary hypoplasia, we proceeded further for bronchoscopy. It revealed multiple blind pouches or diverticulae at the distal end of right main bronchus with narrowing of lumen of lobar bronchi. Finally, CTPA was done which revealed small caliber of right main pulmonary artery [16mm], lobar and segmental arteries than left side.





Primary Pulmonary Hypoplasia Masquerading As Cystic Bronchiectasis In An Adult

- Hilar & Cx. appear @
 - 2 main = large central pulmonary arteries are reduced in caliber & subsegmental arteries = hypoplastic
 - Segmental arteries also appear reduced in caliber
 - 2x main pulmonary (that are ~~normal~~ smaller in caliber than that of the Cx. but to contrast with normal @
 - The segmental arteries also appear decreased in caliber
 - hypoplastic pulmonary arteries & subsegmental arteries present throughout along the hilum
 - No poloidal lobular chest wall
 - No Cx. effusion or Cx. Ate. @
 - 3x ventral appear @
 - Imaging features are Cx -
 - hyperinflated & hyperlucent lung parenchyma with hyperlucent areas @ the base
 - hyperlucent lung parenchyma with poor vascular markings @ the base

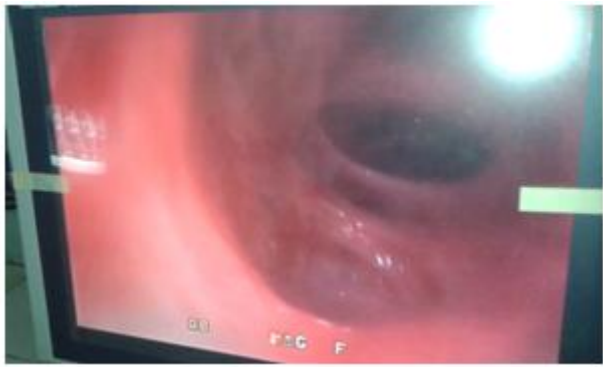DEPARTMENT OF CHEST DISEASES, ANHRA MEDICAL COLLEGE
 GOVERNMENT GENERAL HOSPITAL AND COMMUNICABLE DISEASES
 VILUPPATTURAM

NAME: S. Sridharan
 AGE: 45
 SEX: Male
 OCCUPATION: Teacher
 DATE: 10/10/19
 REF: 10/10/19

HISTORY: Cough, Sp. 20 days
 SIGNS:
 TENDERS:
 PULSES:
 HEART:
 LUNGS:
 ABDOMEN:
 GENITURINARY:
 NEUROLOGICAL:

PREVIOUS RADIOLOGY REPORTS:
 CXR:
 CT:
 MRI:

FINDINGS:
 - Normal Cx. @, lung & expansion @, no pleural @
 - 2x main bronchi @, separate bronchi @, normal, right @, normal and white middle bronchi @, lower lobe @
 - bronchi are present in the Cx. @ and seen the lower bronchi @
 - 2x main bronchi @, lower and upper bronchi @, normal and normal @
 - 2x long hypoplastic @, normal @



III. Discussion:

Pulmonary hypoplasia was first defined by Depozzi in 1673. Although there is variation in severity and type of changes between different cases, most consistent finding is decrease in number of airway generations ranging from 50-75% of normal with decreased number and size of alveoli up to 1/3rd normal.

Monaldi divided maldevelopment of lung into 4 groups.

Group-I No bifurcation of trachea

Group-II Only rudimentary main bronchus

Group-III Incomplete development of division of main bronchus

Group-IV Incomplete development of sub-segmental bronchi and small segment of corresponding lobe.

Here, this patient comes under group-III maldevelopment of lung.

Boyden classified maldevelopment of lung into 3 degrees.

1. **Agenesis:** Complete absence lung tissue

2. **Aplasia:** Rudimentary bronchus is present but no lung tissue

3. **Hypoplasia:** All the normal pulmonary tissues are present but are underdeveloped

Here, this patient comes under Hypoplasia. Hypoplasia of lung is classified as primary[idiopathic] and secondary.

Primary pulmonary hypoplasia is an intrinsic defect in the process of lung development with an incidence of 1-2 cases per 122000 live births. Etiology not completely known but vitamin A deficiency, viral agents or genetic factors are described.

In Secondary pulmonary hypoplasia, several mechanisms like decreased hemithoracic volume, decreased pulmonary vascular perfusion, decreased fetal movements and decreased lung fields are implicated. Most common cause is space occupying mass like congenital diaphragmatic hernia. This condition is frequently associated with other congenital anomalies which involve urogenital, CVS, CNS, musculoskeletal anomalies of thoracic cage. Most frequent syndrome associated include potter's syndrome [Renal agenesis, Abnormal facies, limb abnormalities and pulmonary hypoplasia]. Bilateral hypoplasia is associated with Thoracic dystrophies and oligohydramnios.

Clinical features depend on degree of pulmonary abnormality and presence of other congenital malformations. Usually however patient is symptomatic, physical examination reveals asymmetry of two sides of thorax, diminished respiratory movements and absence of air entry on affected side. Radiological findings in case of hypoplasia include decreased volume of hemithorax indicated by approximation of ribs, elevation of ipsilateral hemidiaphragm, shift of mediastinum and absence of aerated lung on the affected side. This is associated with over inflation and herniation of contra lateral lung along the anterior mediastinum into the involved hemithorax. Bronchi may form normal bronchial tree but it ends in cavities without alveoli. CECT may be refined to determine existence of carina to distinguish agenesis from aplasia. FOB is very useful to observe the bronchial tree and to discriminate agenesis, aplasia, and hypoplasia. CTPA is useful to know associated vascular abnormality.

Differential diagnosis include Atelectasis due to other causes, Severe bronchiectasis with collapse, Advanced fibrothorax, Swyer James Syndrome [an uncommon abnormality characterized radiologically by a hyperlucent lobe or lung and functionally by air trapping during expiration].

Although the pathological diagnosis of pulmonary hypoplasia can be made on formalin inflated routinely processed lungs on the basis of combination of fresh lung weight, fixed lung volume, Radial alveolar count and estimates of tissue maturity, precise characterization of morphological changes is best performed by morphometric measurement after inflation of lungs to a known transpulmonary pressure.

Treatment of hypoplasia is in the form of medical as well as surgical care both before and after delivery. Before delivery, the patient is treated medically with repeated amniocentesis with or without tocolytics, antibiotics and steroids. After delivery, Respiratory support is given ranging from oxygen to mechanical ventilation including ECMO and dialysis.

Treatment in adults consists of control of recurrent infections, symptomatic treatment in the form of expectorants, bronchodilators and management of other complications. Prophylaxis for Respiratory syncytial virus, pneumococcus and influenza are recommended, mortality rate is 71-95% in newborn period. Prognosis in such cases depend on integrity of remaining lung as well as upon presence of associated anomalies.

IV. Conclusion:

Though hypoplasia is common among the anomalies affecting the lung and airways, it is often missed unless it is seen with high index of suspicion. Once thought, it would be easy to diagnose with a battery of investigations available and through follow-ups. With the best modality of treatment, it would give reasonable quality of life to the patients affected with this anomaly. If surgical option is not contemplated, medical management with the available modalities would comfort the patient most of the times since cure is not a reality.