

## Desmoid Tumor in a Scar from Inguinal Hernia Repair: A Case Report

Ansuman Pradhan<sup>1</sup>, Debananda Tudu<sup>2</sup>, Madhusmita Nayak<sup>3</sup>, Mamata Soren<sup>4</sup>

1. Postgraduate Trainee, Department of General Surgery, Veer Surendra Sai Institute of Sciences and Research, Burla, Sambalpur, 768017, Odisha, India.

2. Associate Professor, Department of General Surgery, Veer Surendra Sai Institute of Sciences and Research, Burla, Sambalpur, 768017, Odisha, India.

3. Postgraduate Trainee, Department of Pathology, Veer Surendra Sai Institute of Sciences and Research, Burla, Sambalpur, 768017, Odisha, India.

4. Associate Professor, Department of Obstetrics and Gynecology, Veer Surendra Sai Institute of Sciences and Research, Burla, Sambalpur, 768017, Odisha, India.

**Abstract:** Cicatricial fibromatosis, a form of desmoid tumor, is benign in nature. The incidence of desmoid tumor is about 0.03% of all cancers. Cicatricial fibromatosis is more commonly associated with abdominal fibromatosis. Though benign, these tumors are locally invasive and known for recurrence to the tune of 20-30%. It is usually seen in adults and is rare in children. In this article we present a case of desmoid tumor (cicatricial fibromatosis) in a post surgical scar from inguinal hernia repair at the inguinal region on the right side of a young boy.

**Keywords:** Desmoid tumor, Cicatricial fibromatosis, Familial adenomatous polyposis.

### I. Introduction

Desmoid tumors, also known as aggressive fibromatosis are benign clonal fibroblastic proliferations that arise as firm, non-tender masses from muscular aponeuroses and tend to invade the muscle, corresponds to 0.03% of all cancers and less than 3% of all soft tissue tumors [1]. The term 'desmoid' originates from the Greek word 'desmos', meaning band or tendon like, and was first applied in 1838[2]. Despite the benign histology, desmoid tumors are locally invasive, with high recurrence rate even after surgical resection, but are unable to generate metastases [3]. Approximately half of these tumors arise in the extremities; the remaining lesions are located on the trunk or in the retroperitoneum. Abdominal wall desmoids are associated with pregnancy and are thought to be the result of hormonal influence.

### II. Case Report

A 14 year old boy presented to the outdoor with a growth over the inguinal region on the right side since last one and half year, gradually increasing in size and not associated with pain. There was no associated inguinal lymphadenopathy. There was no family history of any hereditary cancer syndromes. There was history of prior surgery for inguinal hernia at the same site two years back. On physical Examination, two non-tender, nodular masses of size 5cm×2cm and 2cm×2cm, firm in consistency, striated surface are found in the inguinal region on the right side (figure-1, 2).



Fig. 1

Fig. 2

### III. Discussion

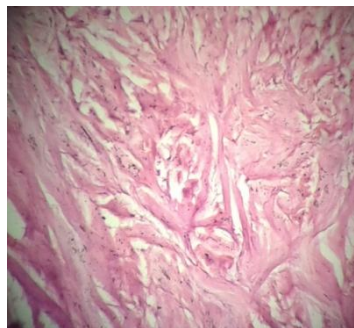
Desmoid tumors (DT) are, a group of deep fibromatoses, of mesenchymal origin, forming a heterogeneous group of pathologic entities resulting from the proliferation of well-differentiated fibroblasts [4, 5]. Desmoid tumors usually arise sporadically but may be associated with Familial adenomatous polyposis

(FAP), with female predominance and incidence is more between 10 to 40 years of age. DTs can arise at any site of the body but abdominal wall and soft tissues of the extremities, shoulder, neck and chest wall are the common sites. DTs are multifactorial in origin. Genetic, endocrine, and physical factors play a role in its etiogenesis. DTs can develop in 10%-15% of patients of FAP and associated with mutation in APC gene. Sporadic DTs are associated with mutation in either APC gene or beta-catenin gene [6, 7]. DTs can be subdivided into three categories (i) Abdominal type, (ii) Extra-abdominal type, (iii) Intra abdominal type.

Abdominal wall desmoid tumors arise from musculoaponeurotic structures of the abdominal wall, especially the rectus and internal oblique muscles and their fascial coverings. Less commonly, they originate from the external oblique muscle and the fascia transversalis [8]. Abdominal fibromatosis occurs in young, gravid, or parous women during gestation or, more frequently, during the first year following childbirth. Rare examples have been reported in children of both genders (especially boys) and adult men [9]. In our case, it developed from the fascial covering of external oblique muscle of a 14 year old boy.

Desmoid tumor arising in a surgical scar is well known as cicatricial fibromatosis [10]. Cicatricial fibromatosis usually occur in the anterior abdominal wall or the extremities [11]. They are extremely rare in the scalp and soft tissue of the neck after surgery. Extra abdominal fibromatosis most frequently occurs in the limbs, followed by the head and neck region [8]. Intra abdominal fibromatoses constitute a group having similar histologic pictures but can be differentiated from one another by clinical settings and location. According to a study by Reitamo et al. [12] abdominal fibromatoses (49%) exceeded the extra-abdominal (43%) and mesenteric (8%) fibromatoses.

Most tumors measure 3 to 10 cm in greatest dimension [9], our excised specimen constitutes two gray colored masses, and one measuring 5cm×2cm × 2 cm and another mass measuring 2cm×1cm × 2 cm. Those are composed of poorly circumscribed bundles of uniform spindle cells which resemble fibroblasts or myofibroblasts surrounded by abundant collagen with extensive hyalinization. The nuclei are small, regular, and pale staining, with a variable mitotic rate and some of the cells having minute nucleoli. The lesions frequently infiltrate adjacent striated muscle, entrapping atrophic muscle fibers (figure-3).



**Fig. 3**

Treatment is indicated in patients, when the tumor poses any complication to surrounding structure or cosmetic concern, with the aim of achieving local control while preserving proper function and providing with an adequate cosmetic result [13]. Wide Surgical excision with negative microscopic margins is one of the mainstays of therapy. Local recurrences do occur even after complete surgical excision. Recurrence is 20% to 30% and usually becomes evident within six months after excision or in connection with subsequent gestations or deliveries in case of abdominal desmoid tumors [9]. As some of the DTs regresses after menopause, they may be kept under observation. Radiation therapy, chemotherapy (i.e. imatinib mesylate, sorafenib) and hormonal therapy like anti-estrogens are indicated if surgery fails or the tumor is inoperable. In our case wide local excision is done and no sign of recurrence is evident till four and half months of postoperative period.

#### **IV. Conclusion**

Cicatricial fibromatosis a rare clinical entity with a distinctive behavior of developing from the surgical scars. Based on the size and location of the tumor, post operative morbidity and high rates of local recurrence the DTs can be treated in a multifaceted way. Though, different modalities of treatment like radiation therapy, chemotherapy, hormonal therapy and observation are available, surgical excision remained the mainstay of treatment.

### References

- [1]. Wanjeri, JK, Opeya CJO. A massive abdominal wall desmoid tumor occurring in a laparotomy scar: a case report. *J Surg Oncol* 2011; 9:35-8.
- [2]. Muller J. U ber den feinen Bau und die Formen der krankhaften Geschwulste. Berlin, Germany: G Reimer 1838; 581–583.
- [3]. Kasper B, Ströbel P, Hohenberger P. Desmoid tumors: clinical features and treatment options for advanced disease. *Oncologist* 2011; 16:682-93. DOI: <http://dx.doi.org/10.1634/theoncologist.2010-0281>
- [4]. Moslein G, Dozois RR: Desmoid tumors associated with familial adenomatous polyposis. *Perspectives in Colon and Rectal Surgery* 1998, 10:109-126.
- [5]. Sagar PM, Moslein G, Dozois RR: Management of desmoid tumors in patients after ileal-pouch-anal anastomosis for familial adenomatous polyposis. *Diseases of the colon and rectum* 1998, 41:1350-1355.
- [6]. Tejpar S, Nollet F, Li C et al. Predominance of beta-catenin mutations and betacatenin dysregulation in sporadic aggressive fibromatosis (desmoid tumor). *Oncogene* 1999; 18: 6615–6620.
- [7]. Wallis YL, Morton DG, McKeown CM et al. Molecular analysis of the APC gene in 205 families: extended genotype-phenotype correlations in FAP and evidence for the role of APC amino acid changes in colorectal cancer predisposition. *J Med Genet* 1999; 36: 14–20.
- [8]. Casillas J, Sais GJ, Greve JL, Iparraguirre MC, Morillo G: Imaging of intra and extra abdominal desmoid tumors. *Radiographics* 1991, 11:959-968.
- [9]. John R. Goldblum, Andrew L. Folpe, Sharon W. Weiss, Enzinger and Weiss's soft tissue tumors 6th ed..Philadelphia: Elsevier Saunders; 2014. PP. 294-299.
- [10]. Kyriakos M. Pathology of selected soft tissue tumors of the head and neck. In: Thawley SE, Panje WR, eds. *Comprehensive Management of Head and Neck Tumors*. Philadelphia: Saunders; 1987; 2:1241–1297.
- [11]. Allen PW. The fibromatoses: a clinicopathologic classification based on 140 cases. *Am J Surg Pathol* 1977; 1:255–270.
- [12]. Reitamo JJ, Scheinin TM, Häyry P. The desmoid syndrome. New aspects in the cause, pathogenesis and treatment of the desmoid tumor. *Am J Surg* 1986; 151(2):230–7.
- [13]. Hosalkar HS, Fox EJ, Delaney T, Torbert JT, Ogilvie CM, Lackman RD: Desmoid tumors and current status of management. *Orthop Clin North Am* 2006, 37:53-6.