

A Distinctive Case Report of a Coalesced Hypercementosed Mandibular First Molar

Dr. Surabhi Rairam¹, Dr. Soumya Allurkar², Dr. Siva Prakash Reddy³,
Dr. Veerendra Patil⁴, Dr. U M Joshi⁵, Dr. Veena Saraf⁶

^{1,4} (Reader, Department Of Conservative Dentistry & Endodontics, HKES S. Nijalingappa Institute of Dental Sciences & Research, Karnataka, India)

² (Senior Lecturer, Department of Oral & Maxillofacial Surgery, HKES S. Nijalingappa Institute of Dental Sciences & Research, Karnataka, India)

³ (Postgraduate Student, Department Of Conservative Dentistry & Endodontics, HKES S. Nijalingappa Institute of Dental Sciences & Research, Karnataka, India)

⁵ (Professor & HOD, Department of Oral & Maxillofacial Surgery, HKES S. Nijalingappa Institute of Dental Sciences & Research, Karnataka, India)

⁶ (Reader, Department Of Prosthodontics, Rural Dental College, Loani, Maharastra, India)

Abstract: Hypercementosis is characterized by excessive deposition of secondary cementum on the root of a tooth. This paper reports a distinctive case on successful management of a coalesced hypercementosed mandibular first molar tooth. A 45-year-old woman reported to the department with severe lancinating pain, with a non contributory medical history. The radiographic examination revealed a diffuse radiopaque mass attached to the mesial & distal root of the right mandibular first molar tooth forming a coalasence, surrounded by a thin radiolucent halo. The differential diagnosis made was hypercementosis, cementoma (true cementoblastoma) & condensing osteitis. Considering the radiographic presentations of no well circumscribed radiopaque mass and no cortical bony expansion a final diagnosis of coalescing hypercementosis was made. Since it was grossly destructed extraction of the involved tooth was planned. A full thickness mucoperiosteal trapezoidal flap was raised from the buccal aspect, since there was an increased resistance encountered while luxation due to grossly carious lesion involving the furcation area & a bulbous mass both on mesial & distal root showing coalescence, osteotomy was done & the tooth along with the mass was extracted followed by placement of sutures. Histopathological report confirmed the final diagnosis of hypercementosis.

Keywords: Hypercementosis, coalescence, radiograph.

I. Introduction

Hypercementosis is an adaptive change in the periodontal ligament characterized by increased cementum thickness on the root surface above and beyond the extent necessary to fulfill its normal functions, resulting in abnormal thickening with macroscopic changes in shape.¹ Hypercementosis induces acceleration in the deposition of new layers of cementum by cementoblasts. Cementum thickening occurs by a rhythmic process: After deposition, each new layer of cementum is mineralized by the previous layer. The last layer, a non-mineralized layer, can also be called precementum. When deposition takes place prior to tooth eruption the cementum can be classified as primary. After eruption, the cementum can be defined as secondary and is formed in response to functional demands.²

According to medical dictionary **hy·per·ce·men·to·sis** (hī'pēr-sē'men-tō'sis) is defined as excessive deposition of secondary cementum on the root of a tooth, which may be caused by localized trauma or inflammation, excessive tooth eruption, or osteitis deformans, or may occur idiopathically. **Hypercementosis** is also defined as an idiopathic, non-neoplastic condition characterized by excessive buildup of normal cementum (calcified tissue) on the roots of one or more teeth.^[3] A thicker layer of cementum can give the tooth an enlarged appearance, which mainly occurs at the apex or apices of the tooth.

II. Case Report

A 45-year-old woman was referred to the department of conservative dentistry & endodontics by district hospital, her dentist had identified a radiopaque mass in the periapical area on left first lower molar. The lesion was symptomatic with severe lancinating pain. The medical history was non contributory. The radiographic examination revealed a diffuse radiopaque mass attached to the mesial & distal root of the right first mandibular molar tooth, surrounded by a thin radiolucent halo. The radiopaque mass was also extending in the inter radicular area. At this point the differential diagnosis made was hypercementosis, cementoma (true cementoblastoma) & condensing osteitis.

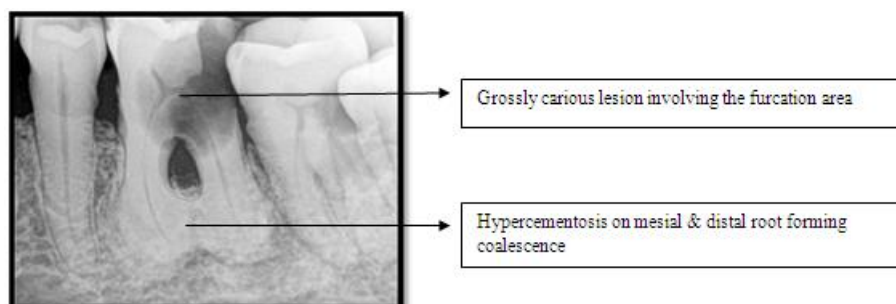


Fig 1: Preoperative radiograph of tooth no#36 demonstrating hypercementosis on mesial & distal root forming coalescence.

As there was no well circumscribed radiopaque mass and no cortical bony expansion we arrived at a final diagnosis of hypercementosis. As the tooth had a grossly carious lesion involving furcation area endodontic treatment had poor prognosis hence extraction of the involved tooth was planned.

The surgical team decided to remove the mass with the related tooth. As the tooth was bulbous open extraction was planned. A full thickness mucoperiosteal trapezoidal flap was raised from the buccal aspect, since there was an increased resistance encountered while luxation due to grossly carious lesion involving the furcation area & a bulbous mass both on mesial & distal root showing coalescence, osteotomy was done & the tooth along with the mass was extracted followed by placement of sutures. The post-operative period was uneventful. The material was sent to histopathological examination and the slides showed tooth fragments displaying features of pulpal necrosis and dentin, attached to a calcified mass of cementum with few small marrow spaces, without proliferative cementoblasts at the periphery. The definitive diagnosis was hypercementosis. The follow-up radiograph after 1 year showed normal bone healing.

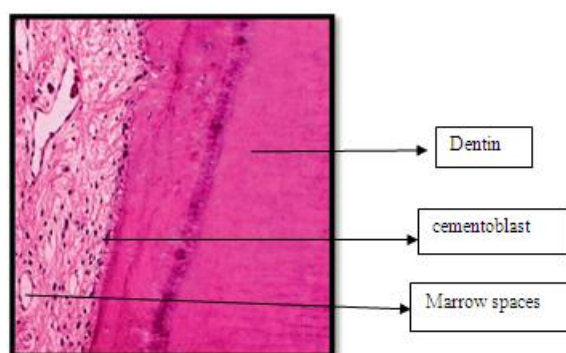


Fig 2: Histopathological Slide of the lesion

Hypercementosis is a non-neoplastic condition in which excessive cementum is deposited in continuation with the normal radicular cementum.^{4,5} It is widely accepted as an age-related phenomenon. Hypercementosis may be evident on the entire root or only parts of a root. In multirrooted teeth, it may be confined to one root or may be present on more than one.^{3,4} It presents with no clinical signs or symptoms. However this case reports severe pain in associated teeth which was related to the carious lesion involving the pulp causing pulpal necrosis & periapical pathosis. Apart from the idiopathic nature of hypercementosis, this condition is associated with several local factors, more commonly periapical pathosis and systemic factors in which a generalized pattern of the condition is seen.^{6,7} Radiographically, an altered root structure caused by the excessive build up of cementum around all or part of the root is evident. The affected teeth demonstrate a thickening of the root surrounded by a radiolucent periodontal ligament space with an adjacent intact lamina dura.⁵ Radiographically, hypercementosis is an occasional finding. The radiolucent shadow of the periodontal membrane and the radiopaque lamina dura are always seen on the outer border of hypercementosis, enveloping it as seen in normal cementum.⁴

Cementoblastoma or true cementoma is a benign odontogenic tumour that arises from cementoblast⁸ comprising 1% to 6.2% of all odontogenic tumours. This neoplasm of functional cementoblasts forms a large mass of cementum or cementum-like tissue on the tooth root.⁹ This tumour occurs more often in males, generally in patients under 25 years of age, producing swelling that can deform bony cortices.¹⁰ The mandible is more involved than the maxilla, principally in the molar and premolar area.¹¹ Radiographically, the calcified mass is attached to the tooth root, with loss of root contour due to root resorption and fusion with the tumour.¹⁰ Histologically, the tumour presents sheets of cementum-like tissue, which may contain a large number

of reversal lines^{11 12} with active cementoblasts. The irregularly mineralized trabeculae of cementum are fused to the root of the tooth. A band of fibrous connective tissue at the periphery resembling capsule may be present.^{14,15} The cementoblastoma exhibits a slow growth and may provoke cortical expansion or perforation.¹¹ Pain may be associated with the lesions.

Cementoblastoma and hypercementosis are lesions associated with tooth roots that may in some circumstances challenge the clinician on their diagnosis. Although hypercementosis and cementoblastoma are typical conditions with distinct clinical evolution, atypical cases may present diagnostic difficulties. Because cementoblastoma is a neoplasm with unlimited growth potential, the usual treatment is complete surgical removal,^{9,13} while a conservative treatment is recommended for hypercementosis. The case reported here showed atypical cementum deposition, mimicking radiographic aspects of a cementoblastoma but there was no well circumscribed radio-opaque mass with no cortical perforation or expansion a diagnosis of atypical hypercementosis was done.

The thin radiolucent zone of uniform width observed at the radiographic examination also supported the diagnosis of hypercementosis, but a thinner radiolucent zone surrounding the calcified mass may also be found in cementoblastoma when the lesion matures. Considering this point together with the calcified mass attached to the mesial & distal root, causing colascence of the roots, we decided to extract the tooth together with the surgical mass. The histopathological examination showed a disproportional acellular cementum deposit attached to the mesial & distal root of the right mandibular first molar associated with a thin connective tissue without cementoblasts. A final diagnosis of atypical hypercementosis was made.

In conclusion, because of similarities between atypical hypercementosis and cementoblastoma, hypercementosis must be included in the differential diagnosis when a huge radiopaque mass is found fused with a root tooth.

References

- [1]. Consolaro, Renata B. Consolaro, Leda A. "Franciscone Cementum, apical morphology and hypercementosis: A probable adaptive response of the periodontal support tissues and potential orthodontic implications " *Alberto Dental Press J Orthod* **21** 2012 Jan-Feb;17(1):21-30
- [2]. Mjör IA, Fejerskov O. O periodonto. In: Mjör I A, Fejerskov O, "Embriologia e histologia oral humana. São Paulo: Panamericana" 1990. p. 131-76.
- [3]. L Napier Souza, S Monteiro Lima Júnior FJ Garcia Santos Pimenta, AC Rodrigues Antunes Souza and R Santiago Gomez. "Atypical hypercementosis versus cementoblastoma". *dmfr.birjournals.org*. Retrieved 2009-09-08.
- [4]. Monahan R. Periapical and localized radiopacities. *Dent Clin North Am* 1994; 38: 113–136.
- [5]. Neville BW, Damm DD, Allen CM, Bouquot JE. Abnormalities of teeth. In: Neville BW, Damm DD, Allen CM, Bouquot JE (editors). *Oral & Maxillofacial Pathology* (2nd edn). Philadelphia: WB Saunders; 2002, pp 49–106
- [6]. Humerfelt A, Reitan K. Effects of hypercementosis on the movability of teeth during orthodontic treatment. *Angle Orthod* 1966; 36: 179–189.
- [7]. Leider AS, Garbarino VE. Generalized hypercementosis. *Oral Surg Oral Med Oral Pathol* 1987; 63: 375–380.
- [8]. Slootweg PJ. Cementoblastoma and osteoblastoma: a comparison of histologic features. *J Oral Pathol Med* 1992; 21: 385–389.
- [9]. Larsson A, Forsberg O, Sjogren S. Benign cementoblastoma – cementum analogue of benign osteoblastoma? *J Oral Surg* 1978; 36: 299–303.
- [10]. Brannon RB, Fowler CB, Carpenter WM, Corio RL. Cementoblastoma: an innocuous neoplasm? A clinicopathologic study of 44 cases and review of the literature with special emphasis on recurrence. *Oral Surg Oral Med Oral Pathol Oral Radiol Endod* 2002; 93: 311–320.
- [11]. Esguep A, Belvederessi M, Alfaro C. Benign cementoblastoma (report of an atypical case). *J Oral Med* 1983; 38: 99–102.
- [12]. Jelic JS, Loftus MJ, Miller AS, Cleveland DB. Benign cementoblastoma: report of an unusual case and analysis of 14 additional cases. *J Oral Maxillofac Surg* 1993; 51: 1033–1037.
- [13]. Ulmanky M, Hjorting-Hansen E, Praetorius F, Haque MF. Benign cementoblastoma. A review and five new cases. *Oral Surg Oral Med Oral Pathol* 1994; 77: 48–55
- [14]. Berwick JE, Maymi GF, Berkland ME. Benign cementoblastoma: a case report. *J Oral Maxillofac Surg* 1990; 48: 208–211.
- [15]. MacDonal-Jankowski DS, Wu PC. Cementoblastoma in Hong Kong Chinese. A report of four cases. *Oral Surg Oral Med Oral Pathol* 1992;73: 760-764.