

## A Study of Prevalence of Different species of Malassezia Causing Pityriasis Versicolor and Seasonal Variation as Predisposing Factor in a Tertiary Care Hospital in Kolkata

Sampurna Biswas Pramanik<sup>1</sup>, Atreyi Chakraborty<sup>2</sup>, Anita Nandi (Mitra)<sup>3</sup>,  
Maitrayee Banerjee<sup>4</sup>, Rina Ghosh<sup>5</sup>, Manas Bandopadhyay<sup>6</sup>.

1,2, Demonstrator, dept. of microbiology, Medical college & hospital, kolkata

3 Assistant professor, dept. of microbiology, Medical college & hospital, kolkata

4 Associate professor, dept. of microbiology, R. G. Kar medical college & hospital, kolkata

5 Assistant professor, dept. of microbiology, R. G. Kar medical college & hospital, kolkata

6 Professor, dept. of microbiology, R. G. Kar medical college & hospital, kolkata.

**Abstract:** Pityriasis versicolor is a chronic superficial skin disease involving the stratum corneum of skin and the sebaceous glands. The main complain of the patients being cosmetic and itchiness on profuse sweating. Most common causative agent is Malassezia species.

**Materials And Methods:** Skin scrapings were collected from 88 consecutive patients from Dermatology OPD, RGKMCH. Most samples were available during summer and rainy season. Speciation done in Microbiology laboratory, RGKMCH. Direct smear preparation with 10% KOH and culture inoculation primarily in SDA and MDA was done, followed by LCB mount and biochemical tests for speciation.

**Observation:** In the present study, higher incidence was found during the month of April to September and the most common species being Malassezia furfur.

**Conclusion:** Pityriasis versicolor is most prevalent during summer and rainy season. M. furfur to be the most prevalent species, followed by M. globosa, M. restricta and M. sympodialis.

**Keywords:** Seasonal variation, Malassezia sp, Pityriasis versicolor.

### I. Introduction

Pityriasis versicolor is a mild, chronic infection of the skin caused by Malassezia yeasts and characterized by discrete or confluent, scaly, discoloured or depigmented areas, mainly on the upper trunk [1]. The characteristic changes include hyperkeratosis, parakeratosis, acanthosis and a mild inflammatory infiltrate. They are discrete or conrescent and appear as discoloured or depigmented areas of the skin. Margins of the macules are sharply delineated. Lesions tend to be discrete in the beginning, but may fuse to give a serpiginous border as they enlarge.

The lesions start as tiny, multiple, macular spots that soon scale and enlarge. The lesions have often been present for more than a year when the patient is seen by a physician. Patients who seek medical attention do so for cosmetic reasons, but upto a third will have noted slight itching or burning in the area of the lesions, particularly when sweating. The expression of infection is promoted by heat and humidity [2]. Left untreated, the infection waxes and wanes for months and years.

A common observation in reviewing a series of cases of pityriasis versicolor is that both hypo and hyperpigmented lesions occur, sometimes on the same patient.

Members of the genus Malassezia are opportunistic yeasts of increasing importance, due in large part to advances in detection and culture methodology which have been allowed their investigation and revealed their importance in human and animal diseases [3,4]. The lipid-dependent genus Malassezia is considered as the causative organism of pityriasis versicolor. Of which *M. furfur*, *M. globosa*, *M. sympodialis*, *M. slooffiae*, *M. obtusa* are considered to be the most common aetiologic agents. *M. furfur* is responsible for pityriasis versicolor mainly under tropical climate [5]. The differences in frequencies of Malassezia species among different studies may be attributed to different culture media (MDA / LNA) and perhaps to ethnic and geographic factors [6].

In temperate climates, the onset of disease seems to be more common from May to September [7]. Although the morphologic characteristics (colony & microscopic examination) for Malassezia is used for primary identification, but they don't provide sufficient information for specific identification of isolates. So, to avoid confusion, physiological tests should be carried out. Two simple preliminary tests for this purpose are, the subculture on SDA (at 37°C) and the catalase reaction. All lipid-dependent species except *M. restricta* exhibit a catalase positive reaction.

## II. Materials & Methods

The study was conducted at the department of Microbiology in collaboration with the Department of Dermatology, R.G.Kar Medical College & Hospital, Kolkata-700004, during the period of July 2011 to June 2012. Patients from Kolkata and adjoining districts attending Dermatology OPD with hypo- or hyperpigmented macular lesions were taken into consideration. Skin scrapings were collected from 88 consecutive patients from Dermatology OPD, RGKMCH. The study was prospective, cross-sectional, tertiary care hospital based. For each patient following protocol was followed:

**Clinical Assessment:** Patients attending Dermatology OPD, RGKMCH with hypo/hyperpigmented macular lesions during July 2011 to June 2012 were examined for pityriasis versicolor. Detailed history regarding socioeconomic condition, any precipitating and aggravating factors, duration of the illness, associated itchiness were taken. Any drug intake history was also enquired about.

**Specimen Collection:** Skin scrapings collected from the junction of active lesion and healthy and normal skin with the help of cellotape and sterile scalpel blade.

**Sample Processing:** All the samples were examined by 10% KOH under direct microscopy. Three skin samples were inoculated in SDCA with olive oil overlay, MDA and BA. Cultures were incubated at 37°C and 25 °C on D3/D7 for any fungal growth. Fungal growth further processed by gram staining, LCB mount and biochemical tests for species identification such as catalase and urease test, glycine assimilation and tween (20,40,60,80) utilization.

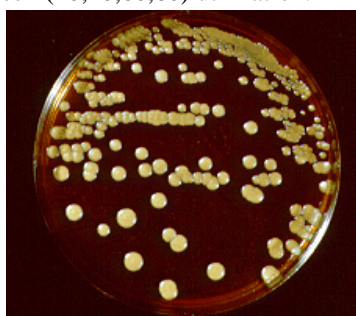

Fig 1: LCB mount

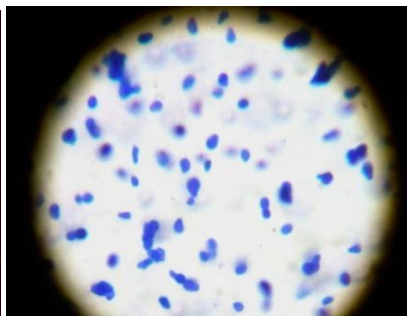


Fig 2: Colonies of Malassezia furfur in MDA.

## III. Results

The study was carried out in the Department of Microbiology in collaboration with the Department of Dermatology, R.G.Kar Medical College and Hospital. Cases included both hypo- and hyperpigmented macular rashes, clinically suspected as pityriasis versicolor. Samples were collected from 98 individuals attending Dermatology OPD. Out of 98 clinically suspected cases, 88 were found to be suggestive for pityriasis versicolor all of which also showed growth of Malassezia on cultivation. Remaining 10 did not show any positive finding either in KOH preparation or culture.

Fig I: Monthwise Distribution Of Pityriasis Versicolor Cases.

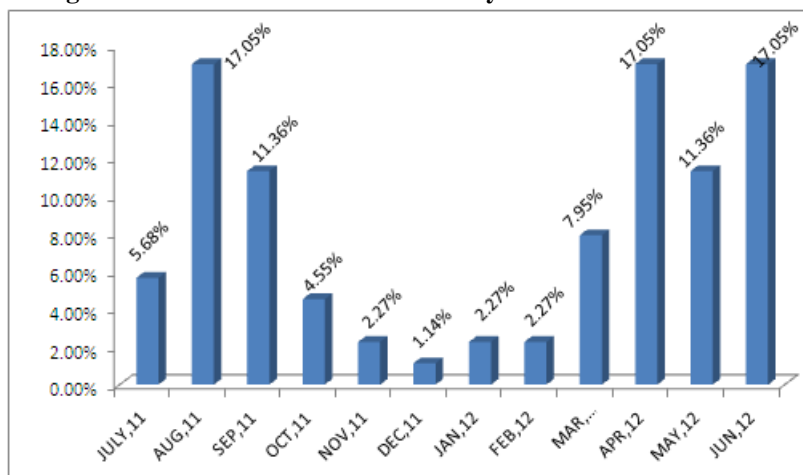
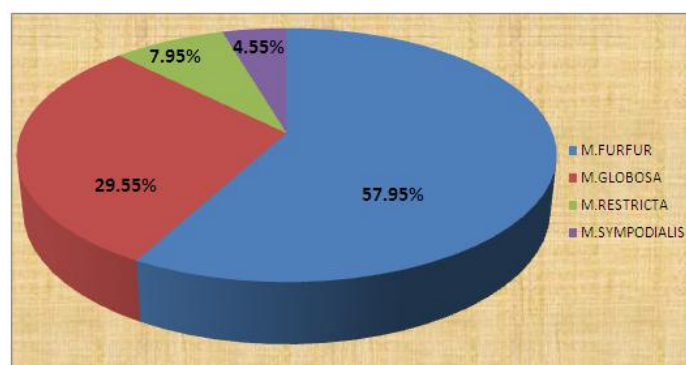


Figure 1 depicts month wise distribution of PV isolates showing monthwise variations. Higher occurrence was seen during April to September (17.05% in April'12, June'12, August,'11.36% in May'12 and September'11), while during the months of October to March the distribution of cases was very low (2.27% in November'11, January'12, February'12 ,1.14% in December'11 and 4.55% in October'11).

**Table I: Prevalence Of Different Malassezia Species Among The Total Culture Positive Cases:**

TOTAL NO. OF CULTURE POSITIVE CASES	88
<i>M. furfur</i>	51(57.95%)
<i>M. globosa</i>	26(29.55%)
<i>M. restricta</i>	7(7.95%)
<i>M. sympodialis</i>	4(4.55%)

Table I demonstrating the prevalence of four malassezia species among 88 culture positive isolates. *M. furfur* isolates are highest (57.95%) in number followed by *M. globosa* (29.55%), *M. restricta* (7.95%) and *M. sympodialis* (4.55%). This configuration is also depicted through a pie diagram.



#### IV. Discussion

Pityriasis versicolor is a mild, chronic infection of skin caused by malassezia yeasts and characterized by discrete confluent, scaly, discoloured or depigmented areas. The characteristic changes include hyperkeratosis, parakeratosis, acanthosis and a mild inflammatory infiltrate. The organism can be seen in the upper layers of the stratum corneum and electron microscopy shows the presence of organisms intercellularly. Increased cell turnover is found in affected cells.

The study was conducted on patients attending Dermatology OPD. The study was carried out in the department of Microbiology in collaboration with the Dermatology department. R.G.Kar Medical College and Hospital, during the midway of July, 2011 to June, 2012.

Both hypo- and hyper-pigmented macular rashes, clinically suspected as pityriasis versicolor were included in the study population. Samples were collected from 98 individuals attending Dermatology OPD. Out of 98 clinically suspected cases, 88 were found to be suggestive for pityriasis versicolor, all of which also showed growth of malassezia on cultivation. Remaining 10 did not show any positive finding either in KOH preparation or culture.

Pityriasis versicolor is known to affect mainly young adults [8,9,10]. The commonest age group affected is 25-30 years in males and 20-25 years in females but it may occur in children [11,12,13] and in the aged. This may be due to varying geographical and environmental conditions. In temperate climates, the onset of disease seems to be more common from May to September. Among the 50 Korean patients studied by Kim & Suh, 66% reported an onset between June and August. All systemic infections due to *M. furfur* or *M. pachydermatis* have been reported in patients (sply, in neonates) who were receiving IV lipid hyperalimentation [14,15,16]. *M. furfur* has not been isolated as a saprophyte from nature or from domestic or wild animals, whereas *M. pachydermatis* has been found more commonly in animals than in humans [17,18]. The association of PV with malnutrition, Cushing's disease, diabetes, oral contraceptives, immunosuppression and pregnancy was frequently mentioned [19,20] but in the present study we didn't find any such association. There is also some evidence of genetically determined susceptibility. In a study it was observed that more than one sibling in a family could get the infection. A positive family history of approximately 17% was noted in more than one study [21,22]. While in spite of long intimate contact between the parents, infection found to be restricted to one of them. Workers found no higher frequency of the disease in married couples than in the general population. The present study also didn't find any familial association in the study population.

The present study conducted among 98 clinically suspected pityriasis versicolor cases revealed prevalence of four malassezia species whereas in various studies most commonly isolated species are seven in number. Chowdhury et al,[9] isolated 12 malassezia species of which *M. globosa*, *M. sympodialis*, *M. furfur* were of clinically significant. Present study also documented this fact. It revealed *M. furfur* to be the most prevalent species among the 88 culture positive cases. It is supported by a few studies conducted under the tropical climate[23,24]. Next in frequency was *M. globosa* followed by *M. restricta* and *M. sympodialis*. This findings are contradictory to the studies by Aspiroz et al[25], Nakabayashi et al[7] and Crespo Erchiga et al[26] who isolated *M. globosa* as the most common species at the frequencies of 58.2%, 55% and 55% respectively.

In two similar studies have been done in South India by Kindo et al, revealed that *M. sympodialis* is the commonest agent (58.3%) followed by *M. globosa* (39.6%).

Another study from North-Central India, conducted by Dutta et al, revealed that 54% of isolates belonged to *M. globosa* and the next common species being *M. furfur* (30%).

Of the previous 17 studies, 11 showed *M. globosa* to be the most common species isolated. Its pathogenicity might be explained by high lipolytic activity[26]. A few studies have found *M. sympodialis* to be the most common species.

## V. Conclusion

Thus malassezia species were found to be the causative organism of pityriasis versicolor. Both hypo- or hyper-pigmented macular rashes were seen to be clinically significant.

The lesion is most prevalent during April to September. This implicates the seasonal association and predominance during summer and rainy season. The present study also suggests *M. furfur* to be the most prevalent species, followed by *M. globosa*, *M. restricta* and *M. sympodialis*. Pityriasis versicolor is a superficial skin disease involving up to the stratum corneum layer of the skin and the sebaceous glands. The main complaint of the patients being cosmetic and itchiness on profuse sweating.

## Acknowledgement

I express my gratitude to Dr. Manas Bandopadhyay, who was my guide in performing this research work as dissertation during my post graduate trainee period. I have been supported by the Microbiology laboratory of RG Kar Medical & Hospital where I completed my MD in Microbiology. The expenses of the research work was carried out partly by government and partly by myself.

## References

- [1]. Bigby, M. and Casulo, C. Pityriasis versicolor... In: Burns, T., Breathnach, S., Cox, N. and Griffiths, C. (Eds.) Rook's textbook of dermatology. Oxford: Blackwell Science. 2008; 8th edn. vol 2:36.10-36.14.
- [2]. Harrison's Principles of Internal Medicine. Tinea Versicolor. 18<sup>th</sup> edition, vol 1, chapter 52, page 402.
- [3]. Midgley, G., Gue'ho, E. and Guillot, J. Diseases caused by Malassezia In: Topley and Wilson's Microbiology and Microbial Infections (Ajello, L. and Hay, R.J., Eds.). 1998; Vol. 4, pp. 201-211.
- [4]. Crespo-Erchiga, V. and Gue'ho, E. Superficial diseases caused by Malassezia species. In: Topley and Wilson's Microbiology and Microbial Infections, Mycology (Hay, R. and Merz, W., Eds.), Arnold, London, UK. 2005. Vol. 5, 10th edn.
- [5]. Midgley G. The lipophilic yeasts: State of the art and prospects. Med Mycol 2000; 38 Suppl 1:9-16.
- [6]. Crespo Erchiga V, Ojeda Martos A, Vera Casano A, Crespo Erchiga A, Sanchez Fajardo F. Malassezia globosa as the causative agent of Pityriasis Versicolor. Br J Dermatol. 2000; 143: 799-803.
- [7]. Roberts S.O.B.: Pityriasis: a clinical and mycological investigation. Br. J. Dermatol., 1969; 81: 315-326.
- [8]. Choudhary R, Singh S, Banerjee T, Tilak R. Prevalence of different Malassezia species in Pityriasis Versicolor in Central India. Indian Journal of Dermatology Venereology Leprology. 2010; Vol 76(2): 159-164.
- [9]. Shams M, Raseae MJ, Moosvi M, et al: Identification of Malassezia species in patients with Pityriasis Versicolor a study in Tehran. Iranian Biomed J. 2001; 5: 121-126.
- [10]. Sugita T, Takashima M, Kodama M, Tsuboi R, Nishikawa A. Description of a new yeast species, Malassezia japonica, and its detection in patients with atopic dermatitis and healthy subjects. J. Clin. Microbiol. 2003; 41: 4695-4699.
- [11]. El-Hefnawi H, El-Gothamy F, Regai M. Studies on Pityriasis Versicolor in Egypt: I. Incidence. Mycosen. 1971; 14(5): 225-231.
- [12]. Michalowski R, Rodziewicz H. Pityriasis Versicolor in children. Brit J Dermatol. 1963; 75: 397-400.
- [13]. Miskeen AK, Kelkar SS, Shroff J. Pityriasis Versicolor in children. Indian Journal of Dermatology Venereology Leprology. 1984; 50: 144-146.
- [14]. Larocco, M., et al.: Recovery of Malassezia pachydermatis from eight infants in a neonatal intensive care nursery: clinical and laboratory features. Pediatr. Infect. Dis., 1988; 7: 398-401.
- [15]. Long, J.G., and Keyserling, H.L.: Catheter-related infection in infants due to an unusual lipophilic yeast- Malassezia furfur. Pediatrics, 1985; 76: 896-900.
- [16]. Redline, R.W., et al.: Systemic Malassezia furfur infections in patients receiving intralipid therapy. Hum. Pathol., 1985; 16: 815-822.
- [17]. Salkin, I.F., Gordon, M.A., and Stone, W.B.: Pityrosporum pachydermatis in a black bear (Ursus americanus). Sabouraudia, 1978; 16: 35-38.
- [18]. Yarrow, D., and Ahearn, D.G.: Malassezia Baillon. In The Yeast: A taxonomic Study. Edited by N. J.W. Kreger-van Rij. Amsterdam, Elsevier Science Publishers, 1984; 3<sup>rd</sup> Ed. :pp. 1-44.

- [19]. Burke RC. Tinea Versicolor : Susceptibility factors and experimental in104. Faergemann J. Epidemiology and ecology of Pityriasis Versicolor in Europe: Treatment and prophylaxis. In: Meinhof W, editor. Oral therapy in dermatomycosis: a step forward. Proceeding of a symposium. Frankfurt, Feb 1985. Oxford: The Medicine Publishing Foundation; 1985;89-95.
- [20]. Faergemann J. Tinea Versicolor (Pityriasis Versicolor). In : Demis D, editors. Clinical Dermatology. Philadelphia: Lippincott-Raven; 1995; 1-11.
- [21]. Faergemann J, Fredriksson T. Tinea Versicolor with regard to seborrhoeic dermatitis: an epidemiologic investigation. Arch Dermatol. 1979;115: 966-968.
- [22]. Krisanty RI, Bramono K, Made Wisnu I. Identification of Malassezia species from Pityriasis Versicolor in Indonesia and its relationship with clinical charecteristics. Mycoses. 2009;52: 257-262.
- [23]. Miranda KC, de Araeyo CR, Soares AJ, de Aquino Lemos J, Souza LK, do Rosario Rodrigues, Silva M. Identification of Malassezia species in patients with Pityriasis Versicolor in Gviania-GO. Rev. Soc Bras Med Trop. 2006; 39: 582-583.
- [24]. Aspiroz C, Ara M, Varea M, Rezusta A, Rubio C. Isolation of Malassezia globosa and Malassezia sympodialis from patients with Pityriasis Versicolor in Spain. Mycopathologia. 2002; 154:111-117.
- [25]. Crespo Erchiga V, Ojeda Martos A, Vera Casano A, Crespo Erchiga A, Sanchez Fazardo F, Guheo E. Mycology of Pityriasis versicolor. J Mycol Med . 1999;9: 143-148.
- [26]. Dutta S, Bajaj AK, Basu S, Dikshit A. Pityriasis Versicolor: Socio-economic and clinico-mycologic study in India. Int J Dermatol. 2002; 41:823-824.