

## Pleomorphic Adenoma of Parapharyngeal Space – A Rare Case Presentation

Jyotirmoy Phookan<sup>1</sup>, Taufeequl Islam<sup>2</sup>, Jayanta Kr Das<sup>3</sup>, Daizy Brahma<sup>4</sup>,  
Dipjyoti Barman<sup>5</sup>

(1 –Associate professor and corresponding author, Department of ORL& HNS Gauhati Medical college & hospital, India .2&5 – Registrar, department of ORL&HNS Gauhati Medical college & Hospital, India .3&4 – Post Graduate student, Department of ORL&HNS ,Gauhati Medical College & Hospital, India)

**Abstract:** Pleomorphic adenoma de novo in the parapharyngeal space is a rare occurrence. Sometimes there may be a continuation of the deep lobe parotid linked by a thin continuation. But when it is de novo it is mostly from minor salivary gland and it is very much less in frequency [1]. Here with we are presenting a case of pleomorphic adenoma of parapharyngeal space presented with obstructed sleep apnoea and difficulty in swallowing.

**Keywords:** pleomorphic, Parapharynx, adenoma, parotid, minor salivary tumour.

---

### I. Introduction

Parapharyngeal tumours constitute just 0.5% of total head neck tumours. These tumours are challenging as per the management is concerned. The anatomy of the parapharyngeal space is complex and can give rise to wide variety of tumours. The complex anatomy and wide variety of pathology make the management of these tumours very challenging. In the prestyloid compartment of parapharyngeal space the commonest tumour are from deep lobe parotid. Minor salivary gland tumour is a rare entity .It forms around 6% of total salivary tumours of which more than 60% are pleomorphic adenoma.

### II. Case Report

A 45 years old female presented with a progressive painless swelling in the throat since 7 years. She complained of difficulty in swallowing and change of voice for 5 years. The attendant of the patient complained of severe snoring with air hunger at night. There was no history of weight loss, fever, bleeding from nose or symptoms like earache.

On physical examination there was a huge smooth firm bulge seen involving the soft palate touching the tongue base and extending from one tonsillar fossa to other. On the right side the lower extent was found much below the lower pole of tonsil pressing the tongue sufficiently. On the left side of the oropharynx breathing space was found to be optimum. The swelling was palpable in neck as non tender firm swelling with ill defined margin. But it was minimally mobile. Remainder of the examination including the cranial nerves was unremarkable. A contrast enhanced MRI was decided to do as there was restricted movement to rule out the possibility of intracranial extension. The MRI scan showed a large lobulated well defined T1 hypointense and heterogenous T2 hyperintense mass lesion measuring 5.70 x 6.50 x 5.60 cm involving the right prestyloid space compressing and displacing lateral wall of oropharynx causing significant luminal compromise. The mass cranially causing effacement of the palatoglossus and palatopharyngeus muscles to abut the soft palate. The mass also compress the nasopharyngeal musculature, Eustachian tube opening, torus tubaris, fossa of rosenmuller. No intracranial extension was found. There was widening of the pterygoid plates. Posterlaterally the mass reaches the post-styloid area and abuts the carotid artery, deep lobe of parotid and condyler process of the mandible. Posteriorly it compresses the prevertebral muscles. Medially the mass abuts the contralateral torus tubaris , CCA .Caudally the mass compress the tongue base. FNAC was not done as the MRI was diagnostic about the tumours benignity and extent.

Because of the large size and involvement of the post-styloid space we approached the tumour through a trans-cervical trans mandibular approach. We used a chin sparing lip splitting incision. Stepped mandibulotomy was done. Identifying the structures and sparing them well the tumour was excised. Hemostasis was secured. We controlled the pterygoid plexus bleeding by identifying the pterygoid muscle and passing catgut sutures all around. A romovac suction drain was used. Post operative tracheostomy was purposefully not done as we achieved a water tight closure so as an adequate space for breathing. On gross examination the

dimension of the tumour was 8x6x5 cm with a greyish white lobulated appearance and smooth greyish white cut surface. Histologically suggest it to be pleomorphic adenoma.

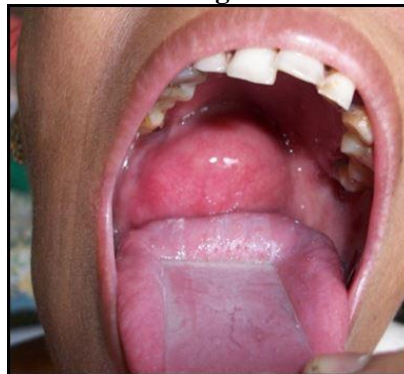Post operative period- the patient had an orocutaneous fistula on tenth day which was subsequently healed 2 weeks following repeated dressing.

### **III. Discussion**

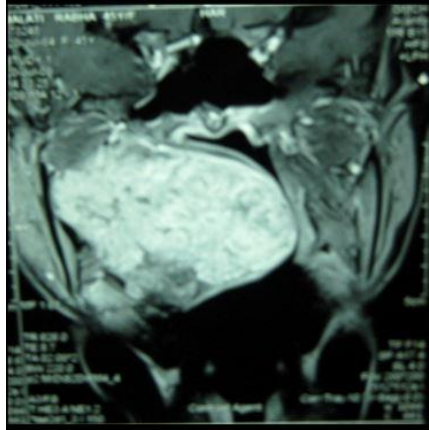
Minor salivary gland constitutes around 10% of total salivary tumour, out of which 40 % are malignant [2].The common sites of minor salivary gland tumour are from palate,lip, buccal mucosa, floor of oral cavity , tongue, tonsil, pharynx, retromolar area and nasal cavity [3, 4, 5]. The fascia of the tensor veli palatini muscle runs through the parapharyngeal space from the styloid process to its insertion on the lateral pterygoid plates. This separate pre and post styloid [6]. Any swelling arising from the pre styloid area stays unnoticed till it grows to a substantial size to cause discomfort in the oral cavity or breathing difficulty i.e. mostly sleep apnoea and swallowing difficulty [ 1] as it was with our patient. Pre-operative evaluation i.e.very important for any size parapharyngeal tumour. One should emphasize on the possibilities of cranial nerve neuropathies. A proper history of palpitation , flushing and uncontrolled pressure has to be evaluated to rule out pheochromocytoma [7].Radiological evaluation is the key for diagnosis and surgical planning. Prof Myers [1] in their series of 157 parapharyngeal tumours commented that the absence of pain and neuropathy and absence of bone erosion rules out the possibility of malignancy .He used CT scan or MRI as a substitute for biopsy. A thin line of fibrofatty tissue in between the deep lobe of parotid and the tumour can differentiate it as a de novo tumour in the prestyloid area [8].Histopathologically pleomorphic adenoma is a epithelial tumour of epithelial and myoepithelial elements with epithelial ducts and chondromyxoid stroma. There is also formation of a false capsule by the compressed salivary parenchyma [8].

There are varieties of surgical approaches for parapharyngeal spaces. Those are namely – Trans oral, Trans cervical, Submaxillary, Trans mandibular, Trans parotid & Infratemporal. Trans-oral approach can be used for excision of prestyloid parapharyngeal tumour [9]. But there is risk of contamination and seedling in the palate. More over there cannot be good control of anatomical complexity. Trans cervical alone or combined with mandibular approach gives a good access if it not big enough to deliver the tumour. The division of stylomandibular ligament and anterior dislocation of the mandible can increase the exposure by 50 % [10].But for a very big tumour like the one which described her in this paper need s a trans mandibular approach as it was reaching up to skull base with a radiological size of about 7 cm and extending from one torus to the other and compressing pre vertebral muscles up to the skull base. It is very important to have very good view of the great vessels both side in such a big tumour apart from the nerves to avoid and catastrophe and recurrence as well.

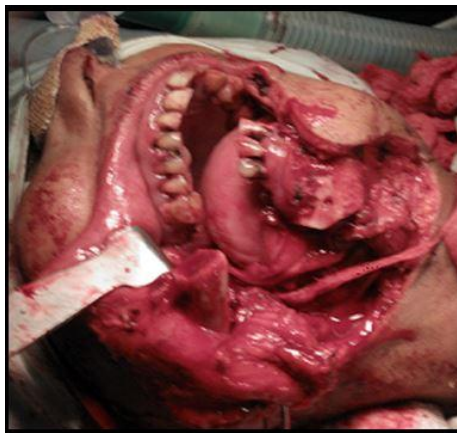### **IV. Figure**



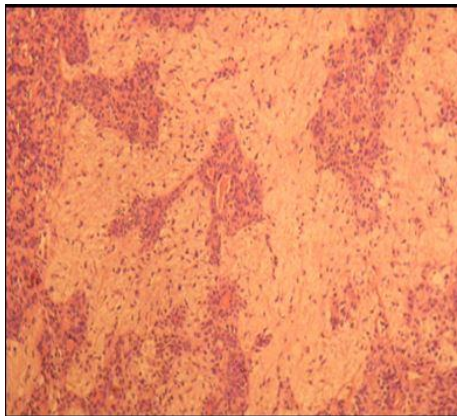
**Fig 1. Pre operative photograph showing soft tissue bulge**



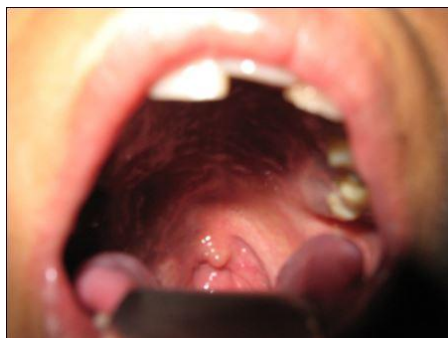**Fig 2. CT scan showing extent of the disease**



**Fig 3. Intra operative photograph .**



**Fig 4 . Micro photograph showing epithelial ducts in chondromyxoid stroma.**



**Fig 5. Post operative photographs.**

## **V. Conclusion**

De novo pleomorphic adenoma in para pharyngeal space is a very rare minor salivary gland tumour. It needs proper pre operative clinical and radiological evaluation to understand the pathology of the disease and to have a proper understanding of anatomical occupancy . An optimum but generous approach is mandatory to avoid any form of risk.

## **Acknowledgements**

We are thankful to the Principal and Superintendent of Gauhati Medical College , Guwahati , Assam , India for allowing us to use and publish the Hospital data.

## **References**

- [1]. Eugene M Myers. Management of parapharyngeal tumour , editor chris de souza , head and neck surgery. Vol -2 , chapter 78,( Jaypee brothers medical publishers private ltd. 2009) , page 1131-1141
- [2]. Patrick J. Bradely . General epidemiology and statistics In a defined UK population , in McGurk M, Renehan (Ed), Controversies in the management of salivary gland disease ,( Oxford University Press, Oxford, 2001) Chapter 1, 3-12.
- [3]. Waldron Ca, El Mofty Sk, Knepp Dr. Tumours of the intra oral salivary glands.a demographic & histologic study of 426 cases. Oral surgery oral med oral pathol. ; 66: 1988 , 323-333.
- [4]. Eveson J W, Cawson RA. Tumour of the minor salivary glands demographic study of 336 cases . J oral pathol. 1985; 14:500-509.
- [5]. Cohen MA. pleomorphic adenoma of the cheek. INT J. Oral maxillofac surg. ; 15, 1986 , 777-779.
- [6]. Som P.M, Biller H F, Lawson W, Sacher M, Lanzieri C F. Parapharyngeal space masses. An updated protocol based upon 104 cases. Radiology ; 153(1): 1984 , 149-156.
- [7]. Myers EN, Jhonson JT, Curtin HD. Tumours of the parapharyngeal space. In myers EN , sien JY : cancer of the head and neck. 4<sup>th</sup> Edition. New York: W B Saunders 2003; 523 -524.
- [8]. Heeneman H. Parapharyngeal space tumours. In Kerr AG (Ed). Scott brown s otolaryngology 5<sup>th</sup> Edition. ( Butterworth & co ltd; 1987). 380- 391 .
- [9]. Goodwin W J JR, Chandler JR. Trans oral excision of lateral pharyngeal space tumour presenting intra orally. Laryngoscope ;98(3) :1988 , 266-269.
- [10]. Cohen SM, Buckley BB, Netterville JL. Surgical management of parapharyngeal masses , Head neck ; 27: 2005 , 669-675.