

Giant Cell Tumour of the Talus: A Rare Case Report

Dr. Soumyajit Mondal¹, Dr. Rajeeb Banik², Dr. Amitava Sarkar³,
Dr. Bastab Saha⁴

¹,Senior Resident, 2.RMO,3&4. Post Graduate Trainee,Department of Orthopaedics North Bengal Medical College, Sushrutanagar, Darjeeling, West Bengal, India.

Abstract: Giant cell tumour (GCT) is a benign but locally aggressive tumour. It commonly involves the epiphyseometaphyseal end of long bones. GCT rarely involves small bones of hand and foot. GCT of talus bone is a rare entity and very few cases were reported in literature so far. We report about one 20 year old male presented with pain right ankle for one year and swelling of right ankle for nine month with restriction of movement of right ankle and subtalar joint. Plain radiographs and computerized tomography scan (CT) and biopsy of talus bone suggested a diagnosis of giant cell tumour.

Keywords: Giant cell tumour, bone neoplasm, talus, biopsy.

I. Introduction

Giant cell tumour (GCT) is described as neoplasm of undifferentiated mesenchymal stromal cells neoplasm with presence of abundant, multi-nucleated giant cells. GCT is basically a benign but locally aggressive¹ tumour which involves the epiphyseometaphyseal end of long bones. It is commonly seen in the distal femur, proximal tibia, distal radius and proximal humerus in descending order of frequency.² GCT is uncommon in the small bones of hands and feet. Very few cases of GCT talus are reported.³ It commonly found in third decade of life. GCT of small bone of hands and feet occur in slightly younger age group with higher incidence of multicentricity.⁴

Histopathology shows osteoclasts like multinucleated giant cells. There is no correlation between histological appearance and biological behavior.³ GCT is known for high local recurrence⁵ and undergoes malignant transformation in only three percent cases.⁶

II. Case Report

A 20 years old male presented with pain in ankle joint for last one year and gradual swelling (Fig 1) over the antero-medial aspect of right ankle joint since last nine month. There was no history of trauma, fever, cough, haemoptasis. Examination revealed swelling was diffuse and bony hard in consistency and 7cm×3cm in dimension in anteromedial aspect of right ankle. Patient had mild tenderness over swelling on deep pressure without any sign of inflammation or infection such as erythema, induration or local raise of temperature. There was restriction of movements of ankle and subtalar joints. He had antalgic gait.

Routine blood examinations and chest X-ray are within normal limits. Plain radiograph (Fig 2, 3) of right ankle shows multiple osteolytic lesions with thin cortical outline in some part of talus and narrowing of joint space of ankle and sub-talar joints. CT scan (Fig 4, 5) of right ankle reveals generalized osteopenia with extensile lytic lesion involving whole of the talus with deficient antero-superior cortical margin. General survey and a chest radiograph (Fig 6) were performed to rule out multicentric disease and pulmonary metastasis. Histopathology (Fig 7,8) report showed a neoplastic lesion composed of spindle shaped stromal cell and evenly distributed giant cell.

III. Discussion

GCT is a benign but locally aggressive neoplasm with high tendency of local recurrence. This tumour are very commonly encountered in long bone in clinical practice, lesion involving talus is very uncommon. Goldenberg et al, in their series of 218 cases found only one case involving talus.⁷ In the series of 208 cases by Sung et al, one case reported.⁸ as the lesions affecting small bone of hand and feet are often multicentric in nature, a comprehensive investigation for other lesions is emphasized.⁴

In long tubular bones radiological differential diagnosis include aneurismal bone cyst, non-ossifying fibroma and chondroblastoma. The conventional radiographs of long bone GCT demonstrate a lytic lesion centered in the epiphysis but involves the metaphysis and extending at least in a part to the adjacent articular cortex. The tumour usually bulges beyond the confines of the cortex which undergoes varying degree of resorption. Apart from a thin shell of periosteal new bone outlining the outer surface of tumour, no periosteal reaction is appreciated unless a fracture is present. However the radiographic features of giant cell tumour at sites other than long bones are nonspecific and they are not unlike other osteolytic processes.³

Giant cells in histopathology are also commonly found in other lesions, the so-called variants of giant cell tumours. These lesions include non-ossifying fibroma, unicameral bone cyst, localized osteitis fibrosa, aneurysmal bone cyst, chondromyxoid fibroma, benign chondroblastoma and the “brown tumour” of hyperparathyroidism.⁹

Reference

- [1]. Jaffe HL, Lichtenstein L, Partis RB. Giant cell tumour of bone: Its pathological appearance, grading, supposed variants and treatment. Arch Path 1940 30: 993-1031.
- [2]. Stoker DJ; Bone tumours: General characteristics benign lesions. In Grainger RG, Allison DJ editors; Diagnostic Radiology: a Textbook of Medical Imaging. 3rd edition, New York: Churchill Livingstone, 1997: 629-1660.
- [3]. Campanacci M, Baldini N, Boriani S, Sudanese A; Giant cell tumour of bone. J Bone Joint Surg Am., 1987; 69(1): 106-114.
- [4]. Wold LE, Swee RG. Giant cell tumour of the small bones of the hand and feet. Semin Diagn Pathol 1984 1: 173-184.
- [5]. Carrasco CH, Murray JA. Giant cell tumours. OrthopClin North Am., 1989; 20(3): 395-405.
- [6]. Malawer MM, Bickels J, Meller I, Buch RG, Henshaw RM, Kollender Y. Cryosurgery in the treatment of giant cell tumour. A long-term followup study. Clin Orthop Rel Res 1999 359:176188.
- [7]. Goldenberg RR, Campbell CJ, Bonfiglio M: Giant cell tumour: an analysis of 218 cases. JBJS 1970 52A: 619-664.
- [8]. Sung HW, Kuo DP, Shu WP, Chai YB, Liu CC, Li SM: Giant cell tumour: an analysis of 208 cases in Chinese patients. JBJS 1982 64A: 755-761.
- [9]. Turek SL. Tumours of Bone. Orthopaedic Principles and their Applications. 4th edition. Philadelphia, Lippincott, 1998.

Photo in next pages

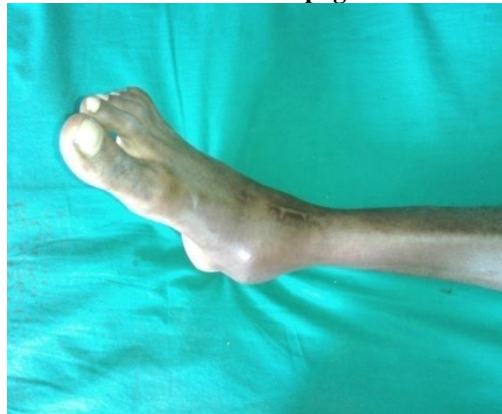

Fig 1: Swelling of anteromedial aspect of right ankle with surgical incision mark of biopsy

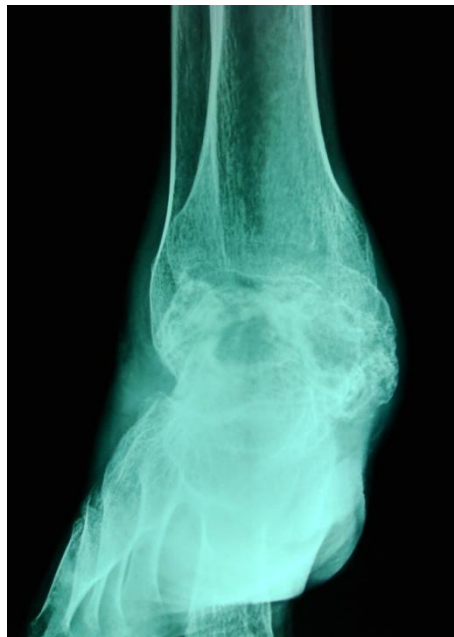

Fig 2: AP view of right ankle

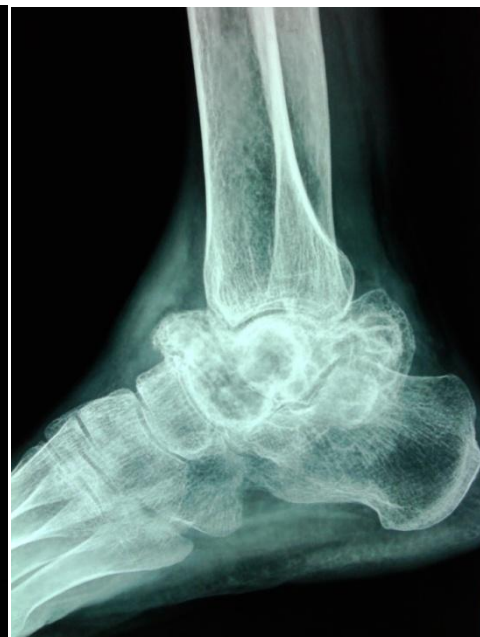

Fig 3: Lateral view of right ankle

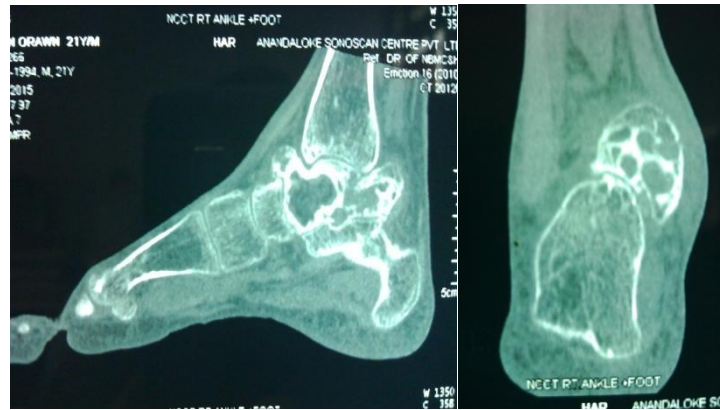

Fig 4, 5: Computerized tomography scan (CT) of right ankle

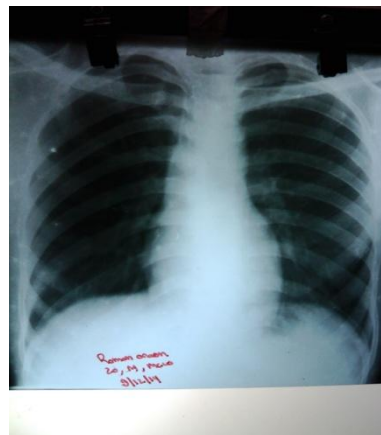


Fig 6: Chest radiograph shows no pulmonary metastasis

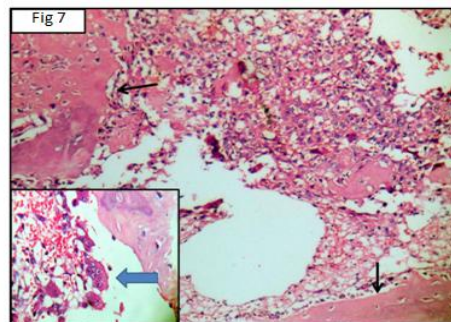


Fig 7: Microphotograph showing the expansile growth composed of stromal cells and giant cells between the bony trabeculae(black arrows). Inset shows osteoclast-like giant cells (blue arrow) in close approximation with the trabeculae.(H&E; X100).

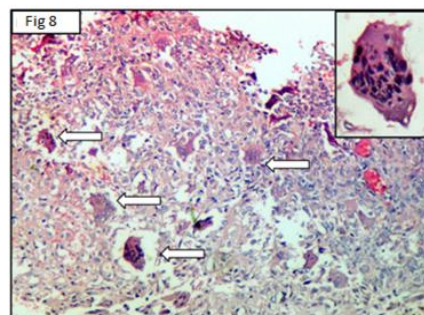


Fig 8: Microphotograph showing the regular and uniform distribution of large, multinucleated osteoclast-like giant cells(white arrows) within the bland looking stromal cells(H&E; X100) Inset shows one such giant cell in higher magnification H&E; X400)