

Giant Retroperitoneal Cystic Lymphangioma- A Case Report with Review of Literature

Dr. Rajarshi Gayen¹ Dr. Manisha Mahata² Dr. Sambit Dasgupta*³

Dr. Jayita Dasgupta (Ghosh)⁴

MS (General Surgery) Medical College and Hospital, Kolkata.

MD (Pathology) R.G Kar Medical College, Kolkata.

MD (Pathology) Calcutta National Medical College, Kolkata.

M.D. (Biochemistry) Nilratan Sircar Medical College, Kolkata.

Abstract: Abdominal lymphangiomas are uncommon benign cystic tumors of the lymphatic system. Retroperitoneal lymphangiomas are even rarer accounting for 1% of all lymphangiomas. They can cause diagnostic dilemmas with other retroperitoneal cystic masses. This report describes a rare case of retroperitoneal mass in a 16-year-old male patient who presented with acute abdomen. Imaging revealed a large multiloculated cystic mass with enhancing septations occupying the retroperitoneum. Extirpation of tumor mass was done successfully. Histopathology revealed a benign cystic lymphangioma.

Keywords: Retroperitoneum, Giant Cystic Lymphangioma

I. Introduction

Abdominal cystic lymphangiomas are rare benign congenital malformations of the lymphatic system with uncertain etiology, predominantly occurring in children.^[1] Approximately 50% of lymphangiomas are present at birth, and almost 90% are diagnosed before the age of 2 years. Retroperitoneal lymphangiomas account for nearly 1% of all lymphangiomas. Preoperative diagnosis is often difficult due to variable clinical presentations. They are easily confused with other retroperitoneal cystic tumors on imaging studies [2]. We report a case of giant retroperitoneal cystic lymphangioma in a 16-year male who presented with acute pain abdomen in the emergency.

II. Case Report

A 16-year-old male presented to the emergency with acute left lower abdominal pain for 5 days and non-passage of stool for 2 days, associated high-grade fever and nausea. Abdomen was mildly distended; however a tender lump was palpated in the left lower quadrant. Bowel sounds were diminished but per rectal examination was unremarkable. He had no history of passage of blood-stained or mucoid stools, dysuria or vomiting. Abdominal symptoms improved after 24 hours of conservative management. X-ray abdomen was non-contributory. A computed tomography (CT) scan of abdomen and pelvis (**Figure 1A, 1B, 1C**) showed a large 20.9 × 15.7 × 9-cm variegated mass with cystic spaces and enhancing septations occupying the retroperitoneum. No obvious calcification or haemorrhage was evident. Percutaneous biopsy of the lesion was avoided due to the possibility of malignant seeding if the lesion was neoplastic. Laboratory investigations showed mild anaemia and moderate leucocytosis (16000/μl). Alfa-fetoprotein and beta human chorionic gonadotrophin levels were normal.

Exploratory laparotomy revealed a huge lobulated mass near the root of the small bowel mesentery (**Figure 2A**). The sigmoid mesocolon and a short segment of sigmoid colon were strongly adherent to the mass which had to be resected along with it. The mass was dissected off from its retroperitoneal attachments and the jejunal mesentery avoiding injury to the superior mesenteric vessels. The patient had an uneventful postoperative course.

Grossly, the resected specimen measured 23cm x 16cm x 9cm, with smooth lobulated outer surface (**Figure 2B**). The cut surface was multicystic with honeycomb appearance. Histological sections showed variable-sized cystic spaces lined by flattened endothelium. The intervening stroma comprised of fibro-adipose tissue, smooth muscle fibres and infiltrated by inflammatory cells. The cystic spaces contained homogeneous eosinophilic material (**Figure 3A, 3B, 3C, 3D**). Thus, the diagnosis of a retroperitoneal multilocular-cystic lymphangioma with inflammation was confirmed. Gram stain of the cyst fluid and culture did not show any micro-organism.

III. Discussion

Cystic lymphangiomas are rare benign malformations of the lymphatic system. Generally, they are common in children and more frequent in boys (M/F ratio, 5:2)[1]. The most frequently affected sites are the neck (75%) and axilla (20%). Approximately 5% of the lymphangiomas are intra-abdominal arising from the mesentery or retroperitoneum (nearly 1%)[2,3]. However they can occur in any location where lymphatics are normally encountered.

It is speculated that lymphangiomas develop due to sequestrations of lymphatic tissue that fail to communicate normally with the lymphatic system, or from abnormal budding of the lymphatic endothelium[4,5]. Other potential causes are thought to include abdominal trauma, localized lymphatic degeneration, radiation and lymphatic obstruction[6].

Most retroperitoneal lymphangiomas remain asymptomatic and therefore grow to large proportions[7]. Symptoms of these tumors may mimic a wide spectrum of diseases. Infrequent presentations include intestinal obstruction, ascites, bleeding, rupture, ureteric obstruction, haematuria or clotting disorders[8,9].

Differential diagnosis of cystic retroperitoneal lymphangiomas include benign lesions such as cysts of urothelial and foregut origin, microcystic pancreatic adenoma, retroperitoneal hematoma, abscesses, duplication cysts, ovarian cysts and pancreatic pseudocysts, malignant tumors such as cystic mesothelioma, cystic teratoma, undifferentiated sarcoma, cystic metastases (especially from ovarian or gastric primaries), lymphangiosarcoma and malignant mesenchymoma[10].

A contrast CT can demonstrate 'water density' fluid within unilocular or multilocular cysts while MRI may delineate additional lesions[11]. Preoperative imaging may be suggestive but cannot provide a single definitive diagnosis. Image guided biopsy is better avoided due to potential risk of dissemination of malignancy.

Intra-abdominal lymphangiomas are of four types. Type I, the pedicled type, enlarge rapidly and cause torsion. Type II, the sessile type, is located within the mesentery of the bowel. Type III, the retroperitoneal type, involves the retroperitoneal structures, such as the mesenteric root, the aorta and the vena cava. The type IV multicentric type extensively involves the intra-abdominal and retroperitoneal organs[6].

The treatment of choice is complete surgical resection in order to avoid recurrences or complications[12]. Aspiration and injection of sclerosing agents may be used for symptomatic diffuse lesions which are unresectable due to involvement of vital structures [13]. In selected cases laparoscopic approach may be used[14]. Histopathology remains the key to definitive diagnosis, sometimes supported by immunohistochemistry. Characteristic finding is dilated lymph vessels lined by endothelial cells along with connective tissue and smooth muscle fibres forming the intervening stroma. The presence of smooth muscle and lymphatic spaces in the wall of the cyst differentiates it from a chylolymphatic cyst. Immunohistochemically, lymphatic endothelium is positive for CD31, CD34 and D2-40, Factor VIII related antigen, endothelial receptor-1, vascular endothelial growth factor-3, prox-1 expression and negative for cytokeratins[15,16]. Calretinin and HMB-45 can differentiate lymphangiomas from multi-cystic mesothelioma and lymphangiomyoma respectively[17]. Histologically lymphangiomas are classified into three types; capillary (or simple), cavernous and cystic[9]. Simple lymphangiomas consist of small, thin-walled, lymphatic channels. Cavernous types are composed of dilated lymphatic channels. Cystic type contains lymphatic spaces with smooth muscle fibres in the stroma but no connection with the normal adjacent lymphatics. Intra-abdominal and retroperitoneal lymphangiomas are generally of the cystic type[10]. In conclusion, retroperitoneal lymphangiomas are exceedingly rare benign neoplasms which may present as a diagnostic dilemma. Definitive preoperative diagnosis may not be possible. However optimal surgical management can result in remarkably good prognosis.

References

- [1]. Konen O, Rathaus V, Dlugy E, Freud E, Kessler A, Shapiro M, et al. Childhood abdominal cystic lymphangioma. *Pediatr Radiol* 2002;32:88-94.
- [2]. Bhavsar T, Saeed-Vafa D, Harbison S, Inniss S. Retroperitoneal cystic lymphangioma in an adult: A case report and review of the literature. *World J Gastrointest Pathophysiol* 2010; 1(5):171-176.
- [3]. Hauser H, Mischinger HJ, Beham A, Berger A, Cerwenka H, Razmara J, Fruhwirth H, Werkgartner G. Cystic retroperitoneal lymphangiomas in adults. *Eur J Surg Oncol* 1997; 23:322-326.
- [4]. Enzinger FM, Weiss SW. Tumors of lymph vessels. In: *Soft Tissue Tumors*. St. Louis: Mosby-Years Book, 1995: 679-700.
- [5]. Ho M, Lee CC, Lin TY. Prenatal diagnosis of abdominal lymphangioma. *Ultrasound Obstet Gynecol* 2002; 20: 205-206
- [6]. Losanoff JE, Richmann BW, El-Sherif A, Rider KD, Jones JW. Mesenteric cystic lymphangioma. *J Am Coll Surg* 2003;196:598-603.
- [7]. Chan IYF, Khoo J. Retroperitoneal lymphangioma in an adult. *J HK Coll Radiol* 2003; 6: 94-96.
- [8]. Roisman I, Manny J, Fields S, Shiloni E. Intra-abdominal lymphangioma. *Br J Surg* 1989; 76: 485-489.
- [9]. Thomas AM, Leung A, Lynn J. Abdominal cystic lymphangiomatosis: report of a case and review of the literature. *Br J Radiol* 1985; 58: 467-469.
- [10]. Bonhomme A, Broeders A, Oyen RH, Stas M, De Wever I, Baert AL. Cystic lymphangioma of the retroperitoneum. *Clin Radiol* 2001; 56: 156-158.
- [11]. Cutillo DP, Swayne LC, Cucco J, Dougan H. CT and MR imaging in cystic abdominal lymphangiomatosis. *J Comput Assist Tomogr* 1989; 13: 534-536.
- [12]. Burkett JS, Pickleman J. The rationale for surgical treatment of mesenteric and retroperitoneal cysts. *Am Surg* 1994; 60:432-435.

- [13]. Tsukada H, Takaori K, Ishiguro S, Tsuda T, Ota S, Yamamoto T. Giant cystic lymphangioma of the small bowel mesentery: report of a case. *Surg Today* 2002;32:734-7.
- [14]. E. N. Trindade, M. R. Trindade, J. C. Boza, V. Von Die-men , R. B. Ilgenfritz. Laparoscopic excision of a retroperitoneal cystic lymphangioma in an elderly patient. *Minerva Chirurgica*, 2007; 62(2) :145-147.
- [15]. Hornick JL, Fletcher CD. Intraabdominal cystic lymphangiomas obscured by marked superimposed reactive changes: clinicopathological analysis of a series. *Hum Pathol* 2005; 36(4):426-32.
- [16]. Yang DM, Jung DH, Kim H, Kang JH, Kim SH, Kim JH, Hwang HY. Retroperitoneal cystic masses: CT, clinical, and pathologic findings and literature review. *Radiographics* 2004; 24(5):1353-1365.
- [17]. WorapopSuthiwartnarueput, SiriphutKiatipunsodsai, AmolchayaKwankua, and UtairatChaumrattanakul. Lymphangioma of the small bowel mesentery: A case report and review of the literature. *World J Gastroenterol*. Nov 21, 2012; 18(43): 6328–6332.

Figure 1

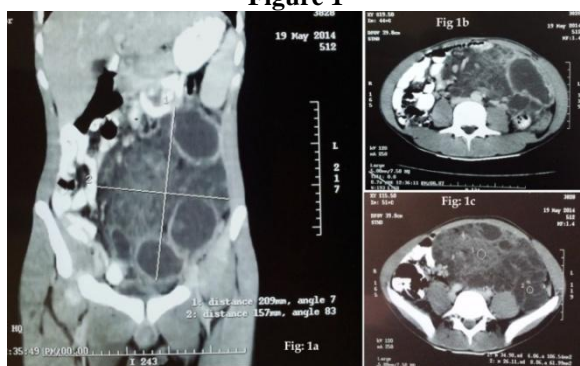

Figure 2

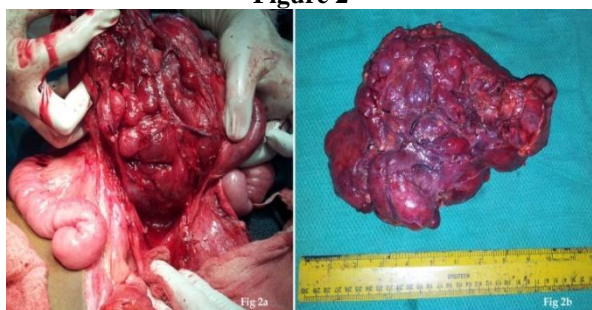
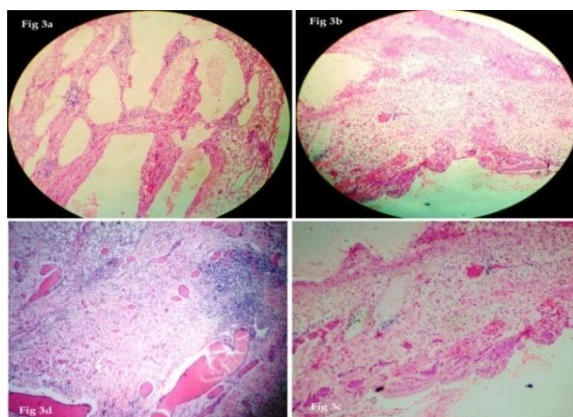


Figure 3



Legend To Figures

Fig.1A, 1B, 1C:CECT abdomen showing a giant retroperitoneal variegated multicystic mass.

Fig.2A: Intraoperative image of the mass being dissected off its retroperitoneal attachments.

Fig.2B: Gross specimen showing a huge multilocular cystic mass.

Fig. 3A: Photomicrograph showing variable-sized cystic spaces lined by flattened endothelium (H&E X40).

Fig. 3B& 3C: Cyst wall lined by fattened endothelial cells and comprised of smooth muscle and aggregates of lymphocytes (H&E X100).

Fig. 3D: Intervening stroma comprised of fibroadipose tissue, smooth muscle fibres and small lymphatic spaces (H&E X100).