

A Study of Prostatic Lesions With Reference To FNAC Evaluation and Histopathology

Dr. Dhanamjaya Rao Teeda MD (Path) DCP¹ Dr. Sreelatha Vengala
MD (Anesthesiology) DGO² Dr. Hareesh Kumar A
Associate Professor, Dept of Pathology, Siddhartha medical college,
Assistant professor of anesthesiology, Siddhartha Medical College.

Abstract: Prostate represents the major organ for most of the surgical problems in the field of urology. Knowledge about the embryology, anatomy, histology and physiology is essential for understanding the etiopathology of the prostatic diseases. Investigations like digital per rectal examination, transurethral cystoscopy, fine needle aspiration cytology, core needle biopsy, transrectal ultra sound examination and serum enzyme estimations are available. The present study is to evaluate the effectiveness of FNAC and to correlate with the biopsy of prostatic lesions. A total of 50 cases of prostatic lesions were studied by aspiration cytology and core biopsy through per rectal route in the same sitting. A lumbar puncture needle of 22 gauge with a 10 ml disposable syringe was used for aspiration and a true cut needle was used for biopsy. The results were correlated analyzed and compared with those of other authors. Fine needle aspiration cytology is the best investigation of choice for pre operative diagnosis, cytological grading of tumors. Recognizing tumor recurrence and also to study the effects of radiotherapy and hormone therapy. It is very useful, simple, cheap, repeatable technique in diagnosing the prostatic lesions.

Keywords: Adenocarcinoma Benign prostatic hyperplasia, Corebiopsy, FNAC, Prostate

I. Introduction

The prostate gland is located between the base of the bladder and the rectum and surrounds the proximal part of the urethra. The two ejaculatory ducts transit through the glands. Anatomically the prostate may be divided into five poorly defined lobes namely the anterior, median, posterior and two lateral lobes. The functional concept of the prostate permitted Mc NEAL to distinguish a central and a peripheral zone in the gland since it reflects a difference in response to hormonal environment. Most carcinoma arise in the peripheral zone of the prostate where as benign hyperplasia exclusively involves the central zone of the prostate.

Prostate represents the major organ for most of the surgical problems in the field of urology. It is the favored site for neoplastic growths and infections. For understanding the etiopathology of the prostatic diseases knowledge about the embryology anatomy, histology and physiology is essential. For proper management of the prostate diseases many investigations like per rectal examination, transurethral cystoscopy, fine needle aspiration cytology, corebiopsy, serum enzyme estimations like prostate specific antigen, prostate associated antigen, acid phosphatase and transrectal ultrasound examination are available. Among all the above investigations tissue diagnosis obtained by aspiration cytology and truecut biopsy by transrectal route are very important to plan the management. The purpose of FNAC is to obtain diagnostic material for cytological study. Initially FNAC was used to diagnose only palpable lesions.

The first attempt at cytological diagnosis of prostate was by transperineal approach by Ferguson in 1930. The technique of FNAC of prostate was introduced by Franzen, Gietz and Zajicek in 1960. Later it was replaced by trans rectal route and popularized by Franzen instrumentation. The simple instruments designed by Franzen made trans rectal biopsy of any palpable abnormality in the prostate or elsewhere in the pelvis relatively easy. In a male patient with a disseminated malignancy of unknown origin FNA of the prostate is a simple method of investigation useful in the search of primary malignancy.

It is a safe, simple, easy to perform as outpatient procedure and causes less discomfort to the patient, the risk of complications is also very low and the patient was not subjected to radiological exposure. This procedure has a high diagnostic accuracy as many studies revealed that it allows prostatic core biopsy to be obtained in arrange of 66-97% of accuracy. Hence transrectal is very valuable procedure in the evaluation of prostatic lesions. With this concept in mind the present study was undertaken to evaluate the effectiveness of aspiration cytology and to correlate with core needle biopsy of prostatic lesions.

II. Methodology

Study design:- Prospective, crosssectional and observational

Study period:- 2 years

Study material:- Fine needle aspirate and core biopsy of the prostate through per rectal route

Inclusion:- All the prostatic lesions patients during study period

Exclusion:- Specimens other than prostate after study period.

III. Results

In the present study 50 patients with prostatic lesions were studied by transrectal FNAC and core needle biopsy
Adequacy: Out of 50 cases, in 41 cases (82%) material obtained is satisfactory to give an opinion. In 9 cases (18%) of cases the material is inadequate. The reasons for inadequacy may be uncooperative patient local rectal pathology or a faulty technique. The cytological results are correlated with histopathology and analyzed.

Nodular hyperplasia

Cytological picture :- In the present study the majority of the lesions, 31 out of 50 cases (62%) are diagnosed as nodular hyperplasia. All these patients presented with chronic retention or acute or chronic retention of urine. On per rectal examination the prostate is found to be showing nodular as well as diffuse enlargement. Some presented with pain and backache. Most of these lesions yielded gray white milky/watery aspirate. In 15 out of 31 cases the smears are highly cellular and showed many benign appearing epithelial cells with honeycomb pattern and distinct cell membranes with centrally placed nuclei. The majority showed intra cytoplasmic granularity. In the remaining 16 cases smears are moderately cellular and showed features of nodular hyperplasia

Histopathology:- The transrectal core needle biopsy also yielded adequate material to diagnose as nodular hyperplasia in all 35 cases. Out of these 35 cases of BPH 6 are associated with chronic prostatitis And one case showed squamous metaplasia. Most of the cases of BPH showed prostatic glands of variable sizes with epithelial stratification with intraluminal corpora amylacea and the stroma is highly cellular

Prostatic carcinoma

10 out of 50 prostatic lesions (20%) studied are diagnosed as malignant in cytology as well as histopathology. 8 out of 10 cases are diagnosed as adenocarcinoma in histopathology which are labeled as suspicious malignancy in cytology. All the patients are elderly men and belong to the age group of 70 -90 years which is the commonest age group for prostatic carcinoma. Most of the patients presented with retention of urine and nonspecific symptoms like backache etc.. On per rectal examination there is a palpable nodularity and the nodules being hard. FNAC is directed mainly to these nodules at multiple sites which yielded adequate material in all 10 cases.

Microscopy picture

Cytology :- Showed moderately cellular smears with decreased cell cohesion and variable isolated cells. There is nuclear crowding with micro glandular patterns. There are indistinct cell membranes with high n/c ratio. Nuclei and nucleoli showed enlargement with lack of intracytoplasmic granularity. Some FNA smears showed sheets of benign glandular epithelial cells along with aggregates of malignant cells. This is possibly due to diffuse growth pattern of prostatic cancer, nuclear pleomorphism and chromatin abnormalities are obvious in less well differentiated carcinomas but may be subtle in grade 1 carcinoma. In a patient with high level of serum PSA even a small numbers of cytologically malignant cells may be taken as confirmative evidence of cancer

Histopathology :- Out of 11 cases reported as carcinoma in biopsy , 8 cases are reported as adenocarcinoma. In two cases which are suspicious of malignancy in FNA are confirmed as adenocarcinoma in HPE. 1 case diagnosed as nodular hyperplasia in cytology was reported as adenocarcinoma on histopathology(false negative).

Most of the cases are of well differentiated and small acinar type. Poorly differentiated cases were not observed in the present study

The reliability of FNAC diagnosis is calculated with comparison to the HPE results.

Definitions in the evaluation of accuracy of FNAC:

True positive (TP) - diagnosed cytologically and histologically as malignant.

True negative (TN) - diagnosed cytologically and histologically as benign.

False positive (FP) - diagnosed cytologically as malignant and histologically as benign.

False negative (FN) -diagnosed cytologically as benign and histologically as malignant.

Sensitivity :- Fraction of histologically proven malignant cases diagnosed by FNAC as malignant.

$$\text{sensitivity} = \frac{\text{TP}}{(\text{TP} + \text{FN})}$$

Specificity :- Probability that a histologically proven benign case having a negative FNAC

$$\text{Specificity} = \frac{\text{TN}}{(\text{TN} + \text{FP})}$$

$$\text{Diagnostic accuracy :- } \frac{\text{TP} + \text{TN}}{(\text{TP} + \text{FP} + \text{TN} + \text{FN})}$$

5 cases diagnosed as BPH in histopathology showed scant cellularity in FNAC

4 cases are not diagnosable in FNAC and biopsy due to poor cellularity

True positive = 8 False positive = 0

True negative = 31 False negative = 1

Sensitivity: -

$$\frac{\text{TP} (8) \times 100}{\text{TP} (8) + \text{FN} (1)} = 88.89\%$$

Specificity: -

$$\frac{\text{TN} (31) \times 100}{\text{TN} (31) + \text{FP} (0)} = 100\%$$

Diagnostic accuracy: -

$$\frac{\text{TP} (8) + \text{TN} (31) \times 100}{\text{TP} (8) + \text{FP} (0) + \text{TN} (31) + \text{FN} (1)} = 97.50 \%$$

IV. Tables And Photographs

Table 1

Cytology report	No of cases	Biopsy report	No of cases
Benign nodular hyperplasia	31	BPH	35
Carcinoma	8	Carcinoma	11
Suspicious malignancy	2	----	--
Scanty cellularity	9	Scanty cellularity	4
Total	50	Total	50

Table 1 showing the results of the present study

Table 2

Cytology	No of cases	Biopsy	No of cases
Carcinoma	8	Carcinoma	8
Suspicious malignancy	2	Carcinoma	2
Nodular hyperplasia	1	Carcinoma	1
Total	11	Total	11

Table 2 showing the cases as prostatic cancer

Table 3

S.No	Author	Cytological diagnosis			Histopathological diagnosis		
		BPH	Carcinoma	Scanty	BPH	Carcinoma	Scanty
1.	Esposti et al	140	210	--	131	214	5
2.	Epstein et al	77	12	11	73	9	--
3.	Nandana Mishra et al	14	1	--	13	2	--
4.	Present study	31	10	9	35	11	4

Table 3 showing the comparative analysis of cytology and histopathology with other authors

Table 4

S.No	Author	Benign	Malignant	Overall accuracy
1.	Esposti et al	93%	97%	96%
2.	Epstein et al	85.6%	86.6%	95.8%
3.	Aryya et al	--	--	99%
4.	Neeta singh et al	98.33%	81.81%	89.50%
5.	Present study	100%	88.89%	95.7%

Table 4 showing the comparative analysis of diagnostic accuracy by FNAC

Photographs

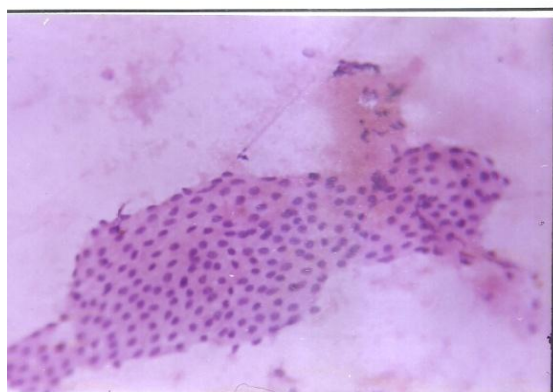


FIG.2 - FNAC 1191/01. CYTOLOGY OF BPH SHOWING HONEYCOMB PATTERN 400X H&E

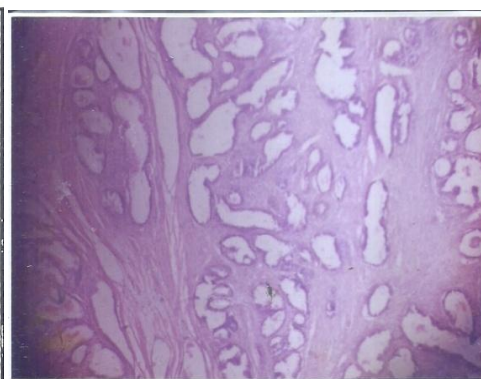
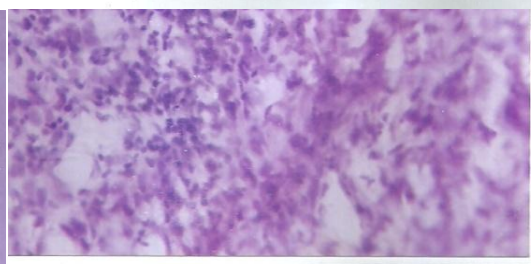
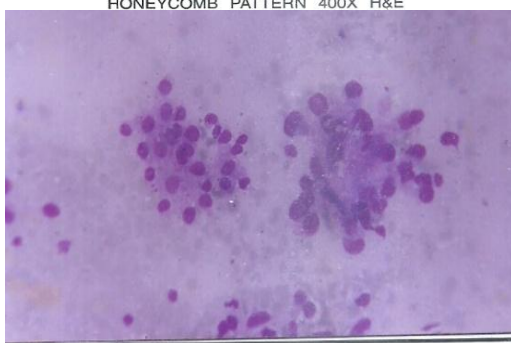


FIG.11 - BIOPSY 1391/01. BENIGN PROSTATIC HYPERPLASIA SCAN VIEW H&E



1. ADENOCARCINOMA OF PROSTATE, POWER VIEW H&E

Cytological picture of adenocarcinoma

V. Discussion

Digital rectal examination (DRE) is a valuable clinical method to diagnose the prostatic abnormality, but differentiation between benign and malignant lesions by DRE alone cannot be made accurately. The accuracy of digital examination of prostatic nodules is only 50%. The serious limitation is lack of sensitivity i.e., false negative results. Hence all palpable nodules of prostate should be followed by cytological or tissue diagnosis. FNAC not only determines the etiology of prostatomegaly but also facilitates the detection of small cancer nodules which can be completely cured by surgery.

In the present study in 41 out of 50 cases (82%) an adequate diagnostic material is obtained with a definitive diagnosis. In the remaining 18% the material is inadequate to give an opinion. 4 out of 9 cases with scanty cellularity yielded adequate material in truecut biopsy and all are diagnosed as BPH.

Similarly in the study conducted by Neeta Singh et al out of 100 cases studied by cytology, adequate material is obtained in 89 cases with insufficient material in 11 cases the usual causes for inadequate material are non-cooperative patient, local rectal pathology or faulty technique. There are no significant complications following these procedures except transient haematuria and local pain.

In general cases of BPH show less yield of material than those of carcinoma. In order to assess the accuracy of the FNAC, confirmative evidence must be obtained either by tissue sample or long-term follow-up. Tissue sampling is more reliable than long-term follow-up.

In the present study out of 50 cases 31 are diagnosed as BPH by cytology, the commonest lesion in the present study. Similarly in the study conducted by Neeta Singh et al, 73% BPH and 9% as carcinoma.

Whereas in the study conducted by Esposito et al, 140 out of 350 cases are diagnosed as BPH and 210 are carcinomas making carcinoma the commonest lesion. The reason may be due to the selection of patients for the study.

In our present study 30 out of 31 are nodular hyperplasia confirmed by histopathology, whereas 1 case diagnosed as BPH cytologically was found to be adenocarcinoma in histopathology (false negative). The reason may be due to sampling error. 8 out of 50 cases are diagnosed as adenocarcinoma by Neeta Singh et al. Whereas in the western studies carcinoma of prostate is more common than nodular hyperplasia.

Similarly in the present study 35 out of 50 cases are diagnosed as BPH and 10 cases as adenocarcinoma making BPH more prevalent and more frequently occurring lesion than carcinoma. 1 case reported as BPH turned out to be carcinoma on histopathology.

Epstein studied 118 prostatic lesions and correlated the findings of aspiration cytology with those of needle biopsy. The study showed a diagnostic accuracy of 86.6% by cytology and 85.6% by histopathology with overall diagnostic accuracy of 95.8%. In the present study the diagnostic accuracy for BPH by FNAC is 100% while it is 88.89% for malignancy with an overall accuracy of 97.5% which is comparable with other studies in table no 4. So it is inferred that the diagnostic accuracy of present study is well comparable to the other authors and within the usual range. In experienced hands a positive diagnosis of carcinoma on aspiration is as reliable as a tissue diagnosis. Many cytologically negative cases may not undergo surgery and are lost without follow up. Many patients are old and may die from other causes before cancer becomes clinically manifest. An unknown number of false negative cytological diagnosis may therefore remain undetected. Due to the above reasons a confident cytological diagnosis is possible in the range of 66-97% of prostatic carcinomas

VI. Conclusions

Benign nodular hyperplasia is the commonest lesion in the present study. There are 8 true positive cases 31 true negative cases 1 false negative case with specificity of 96.6% and sensitivity of 100 %. 82% of cases yielded an adequate diagnostic material by aspiration. There are no significant complications in FNAC and needle biopsy of the prostate. It is clearly evident from present study that FNAC is the best investigation of choice for preoperative diagnosis, grading of the tumor, recognizing the recurrence and also for the study of effects of radiotherapy and hormonal therapy. FNAC is a very useful, simple, cheap, repeatable technique in diagnosing accurately the prostatic lesions and can avoid an open biopsy in many cases reducing patient morbidity and increasing cost effectiveness of the treatment

References

- [1]. Campbell's urology, 5th edition by Patrick-C Walsh M.D. (volume 1 & 2).
- [2]. Robbins' pathologic basis of disease, edited by Ramzi, S.Cotran, M.D. 8th edition.
- [3]. Cytologically diagnosis of prostatic tumors by transrectal aspiration biopsy. A preliminary report by Franzen et al (British journal of urology 1960, 32,193-1966).
- [4]. Cytologic malignancy grading of prostatic carcinoma by transrectal aspiration biopsy by P L Esposi (Scandinavian journal of nephrology 5:199-209, 1971).
- [5]. ACTA Cytologica 10,182-186-1966 by Pier-Luigi Esposi M.D.
- [6]. Cytological versus histological examination of needle biopsy specimens in the diagnosis of prostatic cancer. Hours EK Man, Kerti,Hedberg and P.Sigvard person.
- [7]. The urology clinics of North America volume 18 edition Gerald L Andriole and William J Catalona:M.D.
- [8]. Anderson pathology volume 2.
- [9]. Cancer profile in AndhraPradesh IX A.P. state chapter conference of Indian association.
- [10]. The urologic clinics of North America volume 17 August 1988 by Herbert Lepor M.D. and Patrick C Walsh M.D.
- [11]. Arun R.Chitale proceedings of 40th annual conference of the Indian association of pathologists and microbiologists
- [12]. Symmers text book of pathology volume 3
- [13]. Atlas of FNAC –Orell
- [14]. The Indian journal of pathology of microbiology volume 40-4
- [15]. Juan Rosai and Ackerman's surgical pathology volume 2