

Bilateral Renal Dysplasia in a Male Foetus-A Rare Occurrence

Dr G Sudhakar¹, Dr J Rajendra Prasad², Dr G Jigeesha³, Dr K Narasimhulu⁴

¹(Assistant Professor, Department of Pathology, Siddhartha Medical College, Vijayawada, Andhra Pradesh, India)

²(Associate Professor, Department of Pathology, Siddhartha Medical College, Vijayawada, Andhra Pradesh, India)

^{3,4}(Post graduate, Department of Pathology, Siddhartha Medical College, Vijayawada, Andhra Pradesh, India).

Abstract: Renal dysplasia or multicystic dysplastic kidney is one of the commonly observed congenital urinary tract abnormality found in 2% of paediatric autopsies. Unilateral dysplasia is more common and compatible with extra uterine life. Bilateral renal dysplasia is very rare and incompatible with extra uterine life. It is seen in 1:10000 births and frequently in female foetus. Here we report a rare occurrence of bilateral renal dysplasia in a male foetus.

Keywords: Bilateral renal dysplasia, incompatible with life, male foetus.

I. Introduction

Multicystic dysplastic kidney is the most common variant of renal dysplasia in the new born[1,2]. It was first described by Scharz in 1963. Incidence ranges from 1 in 4300 live births and unilateral cases are more common than bilateral cases[1,2]. Bilateral cases are very rare and they are incompatible with life.

II. Case Report

A female patient aged 28 years with 32 weeks of gestation came to obstetrics and gynaecology department. She was sent to radiology department for routine investigation. Ultra sound examination revealed a single live foetus with breech presentation. Amniotic fluid index was inadequate.

Foetal scan shows abdomen was distended with mild ascitis. Evaluation of Foetal abdomen shows both kidneys are symmetrically enlarged and showing hyper echoic shadows. Cysts of varies sizes were noticed. Urinary bladder was not visible There were no growth retardation or other anomaly noticed. Probable diagnosis of bilateral multiple cystic kidney disease was given. After explaining the prognosis and outcome of foetus patient has undergone hysterectomy. A male live foetus with grossly distended abdomen was delivered. Foetus survived less than 10 minutes and dead foetus sent for pathological autopsy.

On gross examination gross distension of foetal abdomen was noticed. Foetus weighed about 2.5 kgs. Other foetal parameters were noted as crown rump length 34.8cm, Crown heel length 47.3cm, head circumference 36.5, thoracic circumference 24cm and abdominal circumference was 48 cm. On opening of foetal body thoracic organs were pushed up and pulmonary structures appear hypo plastic. Abdominal cavity shows 500ml of ascetic fluid. Both kidneys were grossly enlarged with loss of reniform shape(Fio 1). Cut section shows tiny cysts with clear fluid. The renal blood vessels and ureter were rudimentary. Other organs are hypo plastic and seen in normal position

Microscopic examination, Kidneys show multiple cysts of various sizes and obscuring renal parenchyma. Cysts are lined by low cuboidal epithelium and surrounded by immature stromal elements(Fig 2). There are also primitive tubules, glomerular structures, islands of dysplastic mesenchyme along with fibrous elements seen. Brain shows oedema and lymphocytic infiltration, Lungs show congestion, oedema and haemorrhage. Other organs were histologically normal.

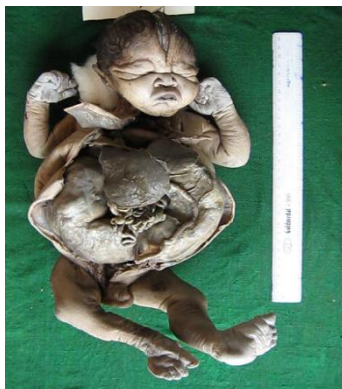

Figure 1: Grossly enlarged kidneys with loss of reniform shape.

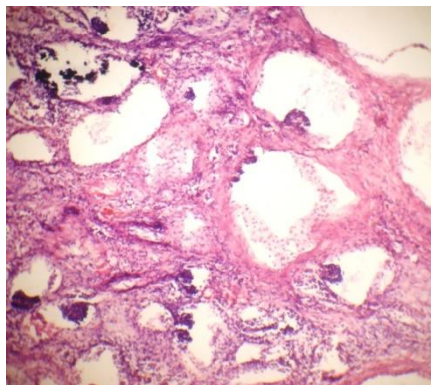


Figure 2: multiple cysts of various sizes lined by low cuboidal epithelium and surrounded by immature stromal elements

III. Discussion

Paediatric renal malformation are the common congenital anomalies and they affect fewer than 10% of all births[1]. Multicystic dysplastic kidney is the most common variant of renal dysplasia and is a common form of cystic disease in the new born[2,3]. Multicystic kidney was first described by Schartz in 1963[4,5]. Nomenclature of various cystic diseases of kidney was given by Parkkulainen et al[4,5].

Incidence ranges from 1 in 4300 live births and unilateral cases are more common than bilateral cases[1,2]. MCKD most commonly seen in boys (2.4:1) with left side unilateral involvement[1]. Unilateral cases are usually accompanied by normal amniotic fluid with favourable prognosis and compatible with life[2,6,7]. So many cases of unilateral MCKD were described in literature but bilateral renal dysplasia were rarely described [1,4,5]. Bilateral cases are more rare with an incidence of 1:10000 births and mostly seen in female foetus [1,2,3,4,6,7]. Bilateral cases are accompanied by oligohydramnios, absence of bladder and pulmonary hypoplasia and incompatible with life[4,6,7]

Multicystic renal dysplasia (MCKD) also known as multicystic kidney is an abnormality of the embryonic development in which the renal parenchyma is substituted by non functioning renal tissue made up of cysts which do not communicate with each other[8]. In all the cases the ureters and renal blood vessels were rudimentary[4]

Primary etiological factors is early obstruction of the foetal urinary tract during the first trimester of pregnancy[1,8]. Other etiological factors like teratogens and certain medications also plays important role in causation[1,2,8] MCKD is usually sporadic in nature, but may present with a familial history[6, 7]. Genetic factors with autosomal dominant inheritance and chromosomal defects like trisomies or chromosomal deletions, different syndromes such as dandy walker, Meckel, Saldino-noonan, Apert etc have shown association with MCKD. The estimated risk of occurrence ranges between 3% and 5% [5, 7]

The antenatal diagnosis of foetal anomalies has improved largely due to the availability of high resolution ultrasound equipment.[3,7,9] MCKD is most commonly an incidental finding on prenatal ultrasound examination[3,7,9]. Ultra sound is able to demonstrate the foetal bladder shortly after the 11th week of gestation when the kidneys start production of urine and it is possible to document the changes of nephrogenesis which continue until 38th week of gestation[3,7,9] Its early diagnosis allows for predicting the probable evolution of pregnancy and its possible complications as well as its perinatal management[7,9]

Dysplastic kidney can be of any size ranging from massive kidneys with multiple large cysts to small hypogenic kidneys [10,11]. The main differential diagnosis is hydronephrosis where there is a large central cystic structure surrounded by dilated calyces [11]. Foetal autopsy including histopathological examination is important to arrive at definitive diagnosis[10,12]. Histopathology shows cystically dilated spaces lined by flattened to cuboidal lining epithelium with intervening stroma showing entrapped, dilated, narrowed immature tubules with surrounding smooth muscle cuffing. Glomerular structures, nerve bundles, cartilage and congested blood vessels are also present[2,10,12].

IV. Conclusion

Though unilateral MCKD is a frequently encountered congenital abnormality, bilateral MCKD in a male foetus is a very rare occurrence and very few cases were described in literature. Ultrasound is an effective diagnostic modality for early diagnosis but foetal autopsy is important to arrive to a definitive diagnosis. We highlight this case for its rarity and also suggest attention should be given for early ultrasonographic diagnosis so that medical termination of pregnancy can be planned.

References

- [1] Robson WL, Leung AK, Thomason MA. Multicystic dysplasia of the kidney. *Clin Pediatr (Phila)*. Jan 1995;34(1):32-40
- [2] Rukmangadha N, Chowhan AK, Patnayak R, Radhika K, Phaneendra BV, Lakshmi AY, Reddy MK. Multicystic dysplastic kidney - a retrospective study with clinicopathological correlation. *J Clin Sci Res* 2013;2:88-93.
- [3] Borade A, Prabhu AS, Prabhu GS, Prabhu SR, Chandramohan S: Antenatal diagnosis of bilateral multicystic dysplastic kidney. *Amrita J Med*, 2010;6(1):36-37
- [4] Ahuja, P., Kapoor, K.K.: Bilateral renal dysplasia (case report). *Int. Urol. Nephrol.*, 10: 89–92, 1978
- [5] Wacksman J, Phipps L. Report of the Multicystic Kidney Registry: preliminary findings. *J Urol*. Dec 1993;150(6):1870-2.
- [6] Hsu PY, Yu CH, Lin K, Cheng YC, Chang CH, Chang FM. Prenatal diagnosis of fetal multicystic dysplastic kidney in the era of three-dimensional ultrasound: 10-year experience. *Taiwan J Obstet Gynecol*. Dec 2012;51(4):596-602.
- [7] Al Naimi, Ammar, Jan- Eric Baumüller, Stephan Spahn, and Franz Bahlmann. Prenatal diagnosis of multicystic dysplastic kidney disease in the second trimester screening. *Prenatal diagnosis*, 2013;33(8): 726-731.
- [8] Saxen L, Sariola H. Early organogenesis of the kidney. *Pediatr Nephrol*. Jul 1987;1(3):385-92..
- [9] Avni EF, Thoua Y, Lalmand B, et al. Multicystic dysplastic kidney: natural history from in utero diagnosis and postnatal followup. *J Urol*. Dec 1987;138(6):1420-4.
- [10] Kumari, N., M. Pradhan, V. H. Shankar, N. Krishnani, and S. R. Phadke. Post-mortem examination of prenatally diagnosed fatal renal malformation. *Journal of perinatology: official journal of the California Perinatal Association*, 2008;28(11):736-742.
- [11] Hussain S, Begum N. Multicystic dysplastic disease of kidney in fetus. *J Ayub Med Coll Abbottabad*. 2007;19:68-9.
- [12] Gipson TG, Anderson EE, Bradford WD. Multicystic renal dysplasia. Pathologic and clinical observations in 22 cases. *Clin Pediatr (Phila)*. Oct 1976;15(10):896-900.