

Efficacy of Fresh Amniotic Membrane Graft Vs conjunctival Auto graft with Stem Cell Transplantation in Management of Pterygium

1. Dr. M.V.D.L. Sathyanarayana M.S, 2. Dr M.V.Sailaja M.D

Assistant professor of Ophthalmology R.I.M.S Kadapa-A.P.,

Assistant professor of Physiology R.I.M.S Kadapa Dr.G.Sree lakshmi MBBS

Abstract:

Aim: To study the efficacy and to evaluate the outcome of fresh amniotic membrane graft vs conjunctival auto graft with stem cell transplantation in the management of pterygium.

Methods: In an interventional case series, 30 patients with pterygium underwent surgical excision with transplantation of fresh amniotic membrane onto bare sclera and 30 patients with pterygium underwent surgical excision with conjunctival auto graft with stem cell transplantation on to bare sclera at Rajiv Gandhi Institute of Medical Sciences, kadapa .Patients were followed for 6 months and results were evaluated in terms of recurrent growth and other postoperative complications.

Results: 60 eyes of 60 patients including 32 males and 28 females of mean age of 40 ± 8 years were operated. The pterygia extended onto cornea for 4 ± 1 mm. Only three eyes with fresh amniotic membrane (10%) and one eye with conjunctival auto graft with stem cell transplantation(3.3%) demonstrated recurrent pterygium growth.

Conclusion: Short term results suggest that pterygium excision with fresh amniotic membrane graft is as good as conjunctival auto grafting and stem cell transplantation and is safe and effective method. But recurrent growth is less with auto grafting and stem cell transplantation and cosmetic appearance also better with auto grafting and stem cell transplantation A larger randomised clinical trial with longer follow up period is however recommended.

Keywords: Fresh Amniotic Membrane graft, pterygium, auto grafting stem cell transplantation, Recurrence.

I. Introduction

Pterygium is a benign condition characterised by a wedge like fibro vascular growth of actinically damaged conjunctiva encroaching across limbus and invading the cornea.

It is a common external eye condition, affecting different populations especially in tropical and subtropical regions .The primary indication for surgical removal of pterygium is decreased visual acuity, which can be the result of encroachment of the lesion onto the visual axis, induced irregular astigmatism, or breakup of precorneal tear film. Other indications for surgical intervention include discomfort and irritation unresponsive to conservative therapy, restricted ocular motility, difficulty with contact lens wear, anticipated keratorefractive surgery and for cosmetic reason.

Major adjuncts for prevention of pterygium recurrence are conjunctival or limbal auto grafts, amniotic membrane grafts, application of Mitomycin C, post operative beta irradiation, postoperative Thiotepe application, buccal mucous membrane grafting etc. .Although many other therapeutic modalities have been proposed, further studies on their efficacy and safety are required.

De Roth in 1940 was the first to describe the use of live placental membranes to repair conjunctival defects. Human amniotic membrane has been advocated for the management of many ocular surface disorders, such as persistent corneal epithelial defects, ocular surface reconstruction for conjunctival neoplasms or scarring, chemical or thermal burns, coverage of conjunctival defects after pterygium excision, Stevens-Johnson syndrome, corneal scarring following excimer laser photocoagulation.

The purpose of the current study is to compare the efficacy and outcome of pterygium excision with fresh amniotic membrane vs conjunctival auto graft with stem cell transplantation in terms of recurrence and complications.

II. Materials And Methods

This interventional case series was conducted from November 2013 to 2014 at Rajiv Gandhi Institute of Medical sciences, Kadapa and included a consecutive series 60 eyes of 60 patients with pterygium extending at least 3mm on to cornea.

Data was collected in standardised proformas from all the patients who are willing to participate in study including taking history, physical and ocular examination and relevant investigations both preoperative and postoperative like visual acuity, slit lamp bio microscopy, Intraocular pressure measurement. Patients were followed for 6 months postoperatively.

Inclusion Criteria:

- 1) All patients > 18 yrs age with pterygium, willing to participate in the study & given informed consent.
- 2) Ability to attend follow ups
- 3) Grade 2-3 pterygium(3mm or more than 3mm onto cornea)

Exclusion Criteria:

- Age < 18 yrs
- Pseudo pterygium
- Grade 1 pterygium
- Lid abnormalities(trichiasis,entropion)
- Sac infection
- Chronic conjunctivitis
- Bell's palsy
- Dry eye syndrome
- Patients with recurrent epithelial erosions

Amniotic Membrane Preparation:

Before procurement of Amniotic membrane, criteria for selection of donors is,

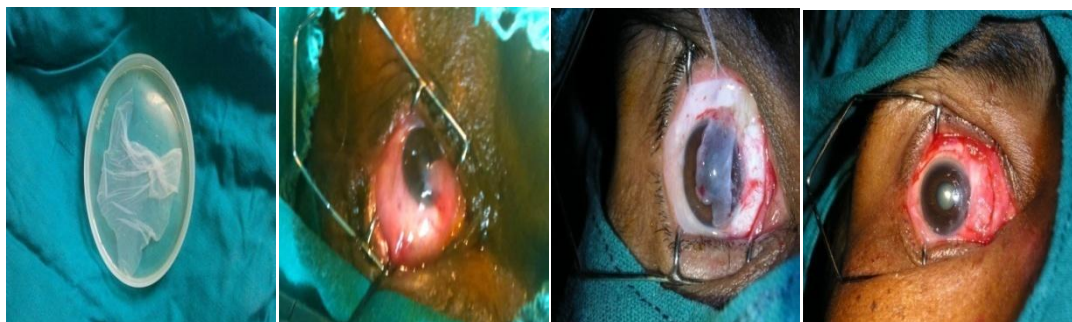- 1) In elective caesarean sections
- 2) Donors to be seronegative for HIV, HBsAg, syphilis, Hepatitis C
- 3) Meconium stained membranes are not to be taken.
- 4) No history of Jaundice, premature rupture of membranes, endometritis and venereal disease.

Under sterile conditions, placenta was washed free of blood clots. Section of membrane was obtained and amnion was separated from chorion. Amnion separated was spread on back of sterile kidney tray and rinsed with Normal saline using moist gauge till blood, mucus, debris was washed. Then it was profusely irrigated with 2l of normal saline and stored in normal saline with 50 ug/ml penicillin, 50 ug/ml streptomycin and Amphoterecin b 50ug/ml in a sterile Petri dish.

When stored at 4 degree celcius, it can be used for 2 weeks.

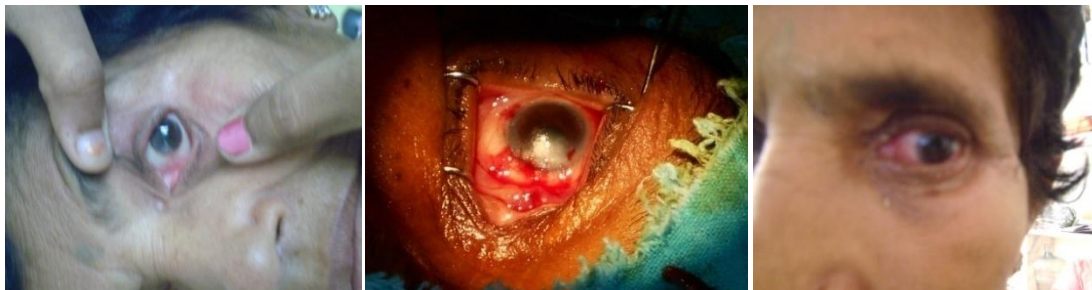III. Surgical Procedure

Anaesthesia: Two point Per bulbar Infiltration anaesthesia. Under aseptic conditions, eye is draped & speculum is inserted. Head of pterygium was first separated at limbus and dissected towards central cornea. After excising head, most of body and subconjunctival fibrovascular tissue is separated from overlying conjunctiva and excised. While excising medially, be caution not to damage Medial rectus. Residual fibro vascular tissue over cornea was detached using toothed forceps or by gentle scraping with # 15 surgical blade. Conjunctiva above and below was trimmed to create a rectangular area of bare sclera. Then that area is covered with freshly prepared Amniotic membrane with basement membrane side up. Then Amniotic membrane is sutured through episcleral tissue to edge of conjunctiva along bare scleral border with 10-0 nylon suture material. About 4-5 sutures were applied. Antibiotic eye ointment is applied in lower fornix. Eye is patched for 24 hrs.



Conjunctival auto graft with stem cell transplantation: after excision of pterygium as above, the eye is turned down and to approach the superior bulbar conjunctiva. The area of corresponding size is measured with calipers and exact dimensions marked with marker pen. These marks are included with in the graft tissue

margins,during the excision of the donor tissue to facilitate its reorientation in the recipient site. The graft is thinnely dissected, avoiding Tenon's tissue and episclera and stem cell gently separated at the limbus.After freeing, the graft, is transferred to the recipient bed and secured to adjacent conjunctiva and episclera with about 5-6 interrupted sutures of 8-0 vicryl or 10-0 nylon on the sclera bed and at corneal margin 10-0 nylon sutures applied..Antibiotic eye ointment applied in lower fornix and pad and bandage applied for 24 hrs.



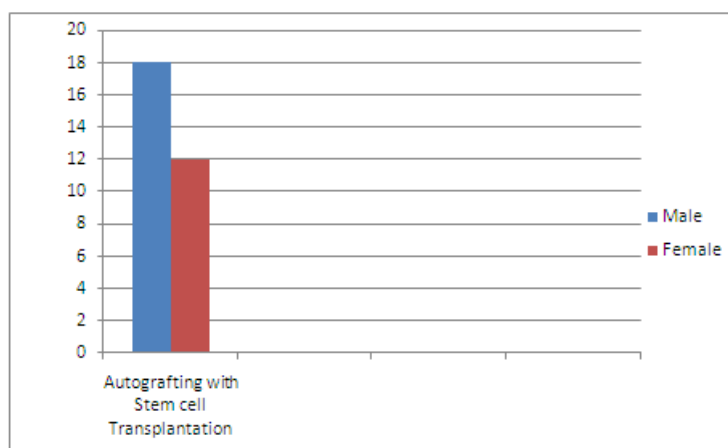
Postoperatively, Ciprofloxacin-Dexamethasone eye drops were given 6 times/day for 1week. Later Dexamethsone eye drops 4 times/day for one month, 2times/day for 10 days in both groups..

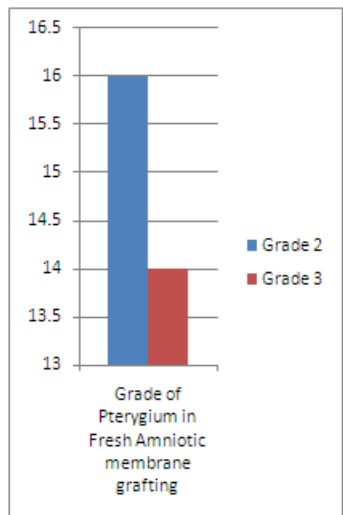
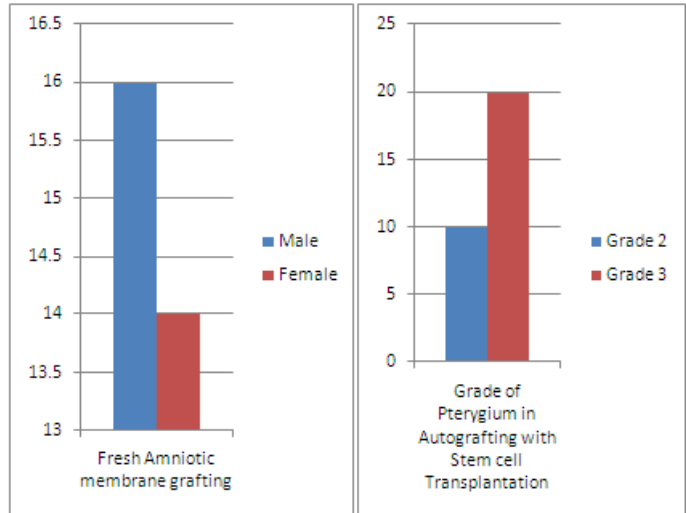
Post op follow up was done at 1st postoperative day,1 wk,4 wk,6 wk, 12wk,6M post operatively. After 1 week, suture removed .At each visit, complaints are enquired,looked for any complications.Slit lamp examination to monitor graft bed integrity & development of other complications.

IV. Results

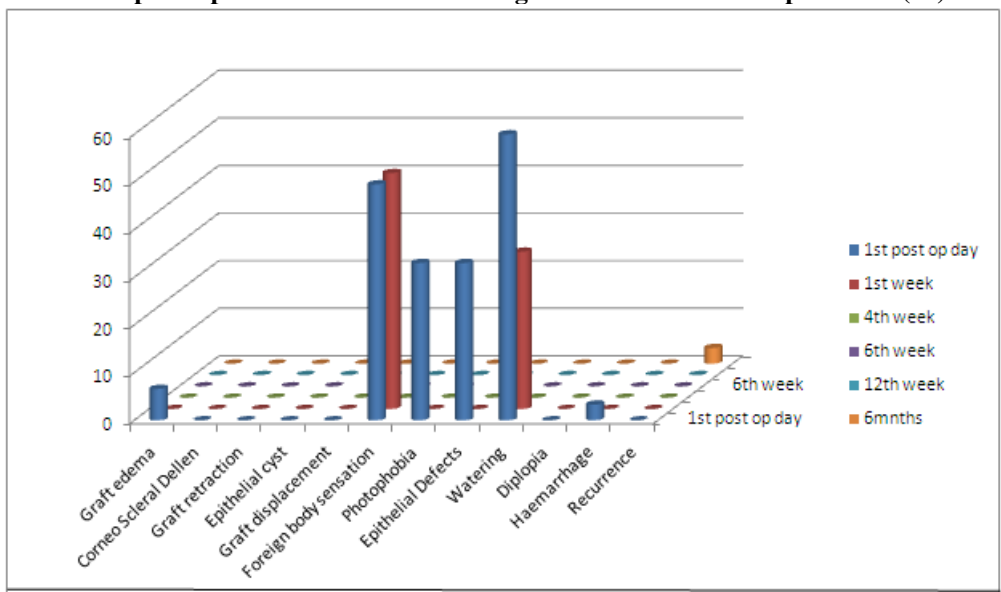
60 eyes with pterygia of 60 patients including 32 males and 28 females with mean age of 40±8 years were operated. The extent of pterygium invasion beyond limbus ranged from 3-5.5mm.

On the first postoperative day, all patients had corneal epithelial defects .By one week, all epithelial defects healed completely and there was no corneal staining with fluorescein in both groups.. Minor post operative complaints like watering, foreign body sensation are noted in few people in both groups which relieved after suture removal..two patients out of 30 in conjunctival auto grafting with stem cell trans plantation developed graft edema(6.6%) and none with fresh amniotic membrane graft. One patient with conjunctival auto grafting developed haemorrhage (3.3%)and three patients with amniotic membrane developed haemorrhage (10%).Only in three patients (3 Out of 30) pterygium recurrence is noted in amniotic membrane graft group (10%). In one patient (1 out of 30) pterygium recurrence was noted in autografting with stem cell transplantation group (3.3%).Recurrence may be due to use of very thin conjunctival graft devoid of tenons tissue No other adverse effects or complications occurs throughout the study period in both groups. Commonest complaints made by both groups are foreign body sensation and watering. .No significant change in visual acuity or intraocular pressure is noted postoperatively in both groups.

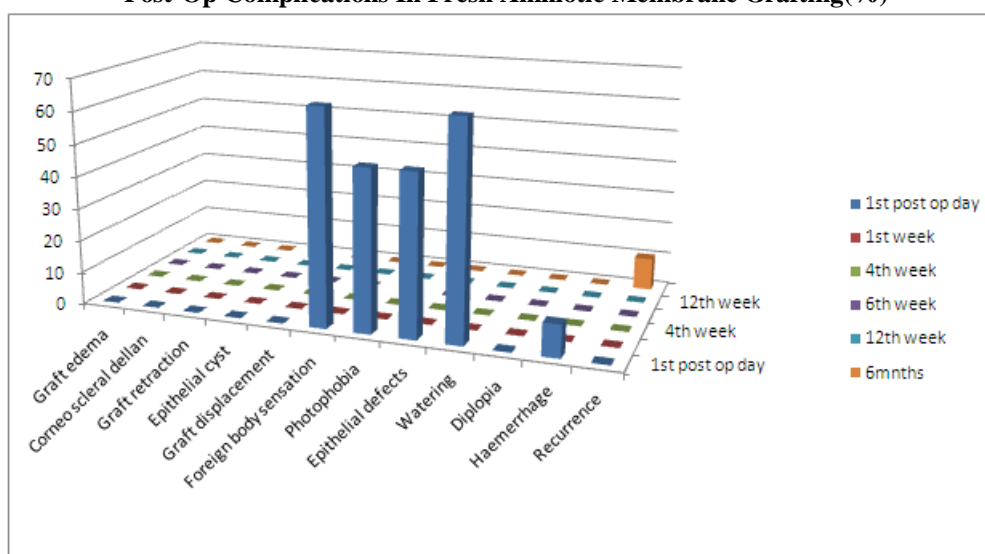




Post-Op Complications In Auto Grafting With Stem Cell Transplantation(%)



Post-Op Complications In Fresh Amniotic Membrane Grafting(%)



V. Discussion

A pterygium is a multifactorial degenerative disorder. Different procedures have been proposed for treatment of Pterygium. However, the main complication common to all is recurrent disease which is more difficult to control. The mechanism of pterygium recurrence has been attributed to surgical trauma, post-operative inflammation, proliferation of fibroblasts and deposition of extracellular matrix.

Recurrence rates are as high as 40% and 16.7% have been observed in the bare sclera and primary closure techniques, respectively. To reduce this recurrence rate, adjunctive

conjunctival auto graft with stem cell transplantation or Amniotic membrane graft or topical Mitomycin C could be used. Following pterygium excision with conjunctival auto graft recurrence rate of 7% have been reported. Topical mitomycin C has been used as a method of reducing recurrence. However, it has a recurrence rate of 38% which is comparatively high. Moreover, some vision threatening side effects such as scleral ulceration, cataract formation and glaucoma have been reported.

Ocular surface describes the entire epithelial surface of the external eye encompassing the corneal epithelium as well as the bulbar and palpalbral conjunctival epithelium, Initially considered as only an anatomic classification that organised the physical continuity of stratified non keratanising epithelium of the conjunctiva, limbus, and cornea, the clinical and research insights of Friedenwald, Thoft and colleagues, and many others have offered compelling evidence of important functional relationships with in this anatomic continuum. Crucial notion of the ocular surface as the functional unit has stimulated a complete reorganisation of our approaches to the pathogenetic concept and the clinical management of ocular surface disease. Although the conjunctiva and especially the limbus perform several functions, their contributions to the proper maintenance and integrity of the corneal epithelium are critical.

Because corneal epithelium is highly differentiated cell type with rapid self renewal abilities, its stem cells should be readily available. Davanger and Evensen were possibly the first to postulate that limbal papillary structure serves as the generative organ for corneal epithelial cells. Kenyon and Tseng ultimately postulated that the stem cells are the most qualified cell to differentiate into normal corneal epithelium.

This stem cell hypothesis also has been extended to a pathogenetic concept of pterygium, where by the pterygium can be considered the consequence of "local stem cell deficiency". In particular, where as normal limbal tissue acts as a barrier between conjunctiva and cornea and thus prevents the invasion of subconjunctival tissue onto cornea. When this barrier function damaged by various insults like .UV radiation or mechanical injuries, sub conjunctival cell are allowed to stream onto adjacent cornea, resulting in pterygium formation. Re-establishing normal barrier function by transplanting healthy limbal tissue may prevent this process. Based on this concept limbal autocrat transplantation has recently been performed in cases with recurrent and advanced pterygia.

De Roth in 1940 was the first to describe the use of live placental membranes to repair conjunctival defects . Being a natural basement membrane, the amniotic membrane contains various matrix proteins which promote the adherence, migration and differentiation of epithelial cells and prevent their apoptosis. It is thought that the major mechanisms by which amniotic membrane reduces recurrence of pterygium are promotion of conjunctival epithelial wound healing, suppression of fibroblasts and reduced extracellular matrix production. This biomaterial may be considered as an alternative to conjunctival grafting in the treatment of pterygium.

In this study, a recurrence rate of 8% was recorded. This is lower than the findings in other studies done by Kucukerdonmez et al., and Luanratanakorn et al(10,12). Which reported recurrence rates of 7.9%,and 28.1% respectively. Even though similar in that these cohorts comprised both primary and recurrent pterygia these studies differed in study design, sample size and follow up period. While this study evaluated 30 eyes with primary pterygia who had pterygium excision with adjunctive amniotic membrane transplant, Kucukerdonmez et al] and Luanratanakorn et al studied 38 and 287 eyes respectively. Kucukerdonmez et al followed up their patients for 13.4 months (mean period) while follow-up period of this study was for 6 months.

Nakamura et al(13) recorded no recurrence in their series. However this study had a longer mean follow-up period of 13.9±6 months.

In the present study, only the minor post-operative Complications like transient graft odema, haemorrhage were reported. No significant sight-threatening complications were recorded. The low recurrence rate and favourable safety profile of pterygium excision with Amniotic membrane graft in the current study attest to the efficacy of this treatment modality and It's results can be compared (though recurrence is more) favorably with results of conjunctival autograft and superior to that of bare sclera. The main advantages of fresh amniotic membrane are easily obtainable, nearly unlimited availability, Lower cost,, for patients with glaucoma who require intact conjunctiva for future glaucoma procedures and to cover large excised areas.

VI. Conclusion

No major post-operative complications following amniotic membrane graft with pterygium excision in the present study agree with other reports that this procedure is effective and safe. However the recurrence rate with fresh amniotic membrane is unacceptably higher than conjunctival auto grafting with stem cell transplantation. Based on results of our study we agree that auto grafting with stem cell transplantation will give less recurrence and better cosmetic appearance than amniotic membrane graft. But, due to the study's small sample size and a short period of follow-up, the findings should be interpreted with caution. A larger randomized controlled study will be required to confirm our findings.

References

- [1]. Okoye O, NC Oguego, Chuka okosa C M ,Ghanta M, Short term results of pterygium surgery with adjunctive amniotic membrane graft. *Niger J Clin Pract* 2013;16:356-9.
- [2]. Hussain A Alhammami ,Amniotic membrane transplantation for primary pterygium surgery, *Medical J Of Babylon*, 2012 vol 9 no.4,734-738.
- [3]. Sangwan VS, Burman S, Tejaswani S, mahesh SP, Murthy R, Amniotic membrane transplantation, A Review of current Indications in management of ophthalmic disorders, *Indian J Ophthal* 2007; 55:251-60.
- [4]. Zhao F, et al clinical observation on fresh amniotic membrane transplantation for treatment of recurrent pterygium, article in *chinese* 2002 Dec;18(4):220-2
- [5]. Goldberg L, David R. Pterygium and its relationship to the dry eye in Bantu. *Br J Ophthalmol* 1976;60:720-1.
- [6]. Alemworie M, Abebe B, Menen A. Prevalence of pterygium in a rural community of Meskan District, Southern Ethiopia. *Ethio J Health Dev* 2008;22:191-4.
- [7]. Asokan R, Venkatasubbu RS, Velumuri L, Lingam V, George R. Prevalence and associated factors for pterygium and pingecula in South Indian Population. *Ophthalmic Physiol Opt* 2012;32:39-44.
- [8]. Hirst LW. The treatment of pterygium. *Surv Ophthalmol* 2003;48:145-177
- [9]. Fernandes M, Sangwan VS, Gangopadhyay N, Sridhar MS, Garg P, Aasuri MK, et al. Outcome of pterygium surgery: Analysis over 14 years. *Eye*, 2005;19:1182-90.
- [10]. Kucukerdonmez C, Akova YA, Altinors DD. Comparison of conjunctival autograft with amniotic membrane transplantation for pterygium surgery: Surgical and cosmetic outcome. *Cornea* 2007;26:407.
- [11]. Allan BD, Short P, Crawford GJ, Barret GD, Constable IJ. Pterygium excision with conjunctival autografting: An effective and safe technique. *Br J Ophthalmol* 1993;77:698-701.
- [12]. Luanratanakorn P, Ratanapakrm T, Suwan-Apichon D, Chuck RS. Randomised controlled study of conjunctival autograft versus amniotic membrane graft in pterygium excision. *Br J Ophthalmol* 2006;90:1476-80.
- [13]. Nakamura T, Inatomi T, Sekiyama C, Ang LP, Yokoi N, Kinoshita S. Clinical application of sterilized freeze-dried amniotic membrane to treat patients with pterygium. *Acta Ophthalmol Scand* 2006;84:401-5.
- [14]. Ma DH, See LC, Liau SB, Tsai RJ. Amniotic membrane graft for pterygium. *Br J Ophthalmol* 2000;84:973-8.
- [15]. Mastropasqua L, Carpineto P, Ciancaglini M, Enrico Gallenga P. Long term results of intraoperative mitomycin C in the treatment of recurrent pterygium. *Br J Ophthalmol* 1996;80:288-91.
- [16]. Buratto L, Phillips R L, Carito G. Pterygium surgery. NJ:SLACK: Slack Incorporated; 2000
- [17]. Prabhasawat P, Barton K, Burkett G. Comparison of conjunctival autograft, amniotic membrane grafts, and primary closure for pterygium excision. *Ophthalmology* 1997;104:974-985
- [18]. Prabhasawat P, Barton K, Burkett G. Comparison of conjunctival autograft, amniotic membrane grafts, and primary closure for pterygium excision. *Ophthalmology* 1997;104:974-985.51-77.
- [19]. Baradaran-Rafii AR, Aghayan HR, Arjmand B, Javadi MA. Amniotic membrane transplantation. *Iran J Ophthalmic Res* 2007;2:58-75.
- [20]. Essex RW, Snibson GR, Daniell M, Tote DM. Amniotic membrane grafting in the surgical management of primary pterygium. *Clin Experiment Ophthalmol* 2004;32:1-4.

- [21]. Ozer A, Yildirim N, Erol N, Yurdakul S. Long-term results of bare sclera, limbal- conjunctival autograft and amniotic membrane graft techniques in primary pterygium excisions. *Ophthalmol* 2009;223:269-73.
- [22]. Mutulu FM, Sobaci G, Tatar T, Yildirim E. A comparative study of recurrent pterygium surgery. *Ophthalmology* 1999;106:817-821.
- [23]. Lin CP, Shih MH, Tsai MC. Clinical experiences of infectious sclera ulceration: A complication of pterygium operation. *Br J Ophthalmol* 1997;81:980-3.
- [24]. Katircioglu YA, Altiparmak UE, Duman S. Comparison of three methods for the treatment of pterygium: Amniotic membrane graft, conjunctival autograft and conjunctival autograft plus mitomycin C. *Orbit* 2007;26:5-13.
- [25]. Fernandes M, Sangwan VS, Gangopadhyay N, Sridhar MS, Garg P, Aasuri MK, et al. Outcome of pterygium surgery: Analysis over 14 years. *Eye*,2005;19:1182-90.