

## A clinical study of infantile hypertrophic pyloric stenosis.

Irom Keshorjit Singh<sup>1</sup>, Khuraijam Gojen Singh<sup>2</sup>, Ramesh Singh Laishram<sup>3</sup>,  
Langpoklakpam Chaoba Singh<sup>4</sup>.

<sup>1</sup>Assistant Professor, Pediatric Surgery, Regional Institute of Medical Sciences, Imphal

<sup>2</sup>Assistant Professor, General Surgery, Regional Institute of Medical Sciences, Imphal

<sup>3</sup>Associate Professor, General Surgery, Regional Institute of Medical Sciences, Imphal

<sup>4</sup>Assistant Professor, Anaesthesiology, Regional Institute of Medical Sciences, Imphal

**Abstract:** Infantile hypertrophic pyloric stenosis (IHPS) is the most common gastrointestinal disease occurring in the first few weeks of life presenting as gastric outlet obstruction. IHPS occurs much more frequently in males than in females. In the present study, we retrospectively analysed 44 infants with IHPS comprising 36 males and 8 females (4.5:1). Majority (61.36 %) were diagnosed in the 5<sup>th</sup> and 6<sup>th</sup> week, even though 65.9 % had the initial symptom onset in the 2<sup>nd</sup> and 3<sup>rd</sup> week with mean delay in diagnosis of 22 days. The mean age at presentation was of 40.18 ± 11.68 days. Most patients had acid base imbalance and electrolyte imbalance; elevated bicarbonate level ( $\text{HCO}_3 > 25 \text{ mmol/L}$ ) was observed in 27 patients (81.8 %), pH was above 7.45 in 26 of 33 patients (78.79 %), hypochloreaemia ( $\text{Cl} < 95 \text{ mmol/L}$ ) was found in 31 of 44 (77.27 %), hyponatraemia ( $< 135 \text{ mmol/L}$ ) was observed in 23 patients (52.27 %), and 27 patients (61.36 %) displaying hypokalemia ( $< 3.5 \text{ mmol/L}$ ). All infants underwent successful open pyloromyotomy.

**Keywords:** Infantile hypertrophic pyloric stenosis, pyloromyotomy, electrolyte imbalance, acid-base imbalance.

### I. Introduction

Infantile hypertrophic pyloric stenosis (IHPS) is a gastric outlet obstruction of infancy resulting from hypertrophy and thickening of the circular muscle of the pylorus. IHPS occurs much more frequently in males than in females [1,2]. Caucasians are more frequently affected than the Afro-Caribbeans and Asians [2]. Even though its etiology is still unclear, environmental and genetic components seem to play a major factor [3]; its incidence has been reported as 0.9 to 5.1/1,000 live births [4]. Infants with IHPS typically present with projectile, non-bilious vomiting occurring at 2 – 8 weeks, 10 – 30 minutes following feeds, and which may progress to dehydration, progressive weight loss, and characteristic hypochloreaemic and hypokalaemic metabolic alkalosis [1,4-6]. Pyloric stenosis is treated by pyloromyotomy with excellent prognosis [6]. The average age of presentation was 5 weeks with an average weight of 4 kilograms [4]. Although diagnosis can be made by palpation of an olive-shaped mass in the right upper quadrant, abdominal ultrasonography and barium studies are usually necessary for establishing the diagnosis [7]. In the present study, the clinical features, the biochemical changes and the outcome of children with IHPS are analysed.

### II. Materials And Methods

It is a retrospective analysis of infants diagnosed and treated in the last 5 years and 10 months from January 2010 till October 2015 by the same surgical team. All infants with confirmed diagnosis of IHPS by ultrasonography and treated with open pyloromyotomy were included. The diagnosis were made by clinical features, palpable lump (olive) and the ultrasonographic findings of the pylorus by using the criteria of pyloric muscle thickness of  $> 4 \text{ mm}$ , pyloric length of  $> 16 \text{ mm}$ .

Detailed clinical data including sex, age of onset, clinical features, palpable lump (olive), other coexisting congenital defects, birth order, gestational age, weight, ultrasonographic findings, serum electrolytes concentration, pyloric circular muscle thickness, pyloric channel length and arterial blood gas were collected. The data was expressed using frequencies, percentages or mean and standard deviation (SD). Analysis of data was done by using Statistical Package for the Social Sciences (SPSS version 20.0; SPSS Inc, Chicago, US).

### III. Results

There were 44 patients with IHPS during the past 5-years and 10 months period. There were 36 boys and 8 girls with the ratio of 4.5:1. All infants had classic projectile, and persistent non-bilious vomiting. Visible peristalsis was observed in 28 patients (63.64 %). Palpable mass (Olive) was felt in 32 patients (72.72 %). The age of symptom onset ranged between 5 and 42 days, with the mean of 17.98 ± 9.78 days (Median = 15.5 days). The age of the patients at diagnosis ranged from 25 – 75 days with the mean of 40.18 ± 11.68 days (Median = 37.5 days) [Fig. 1]. Maximum number of patients were diagnosed in the 5<sup>th</sup> and 6<sup>th</sup> week (61.36 %, 27 of 44

patients), even though 29 patients (65.9 %) had symptom onset in the 2<sup>nd</sup> and 3<sup>rd</sup> week. The mean duration from first onset of symptoms to diagnosis was  $22.2 \pm 4.7$  days (range 14 – 40 days) (Median = 22 days). Forty patients (90.9 %) were full-term infants and the remaining four (9.09 %) were preterm babies with gestational age ranging from 34 to 36 weeks. The mean weight at presentation was  $3.77 \pm 0.37$  kilograms (range from 3.2 to 4.8 kilograms). The firstborn child was noted in 72.72 % (32/44) of the cases, the second was 27.27 % (12/44). There were 5 infants (11.36 %) with associated congenital malformations. There were 2 cases of inguinal hernia, 2 cases of patent ductus arteriosus and 1 case of umbilical hernia.

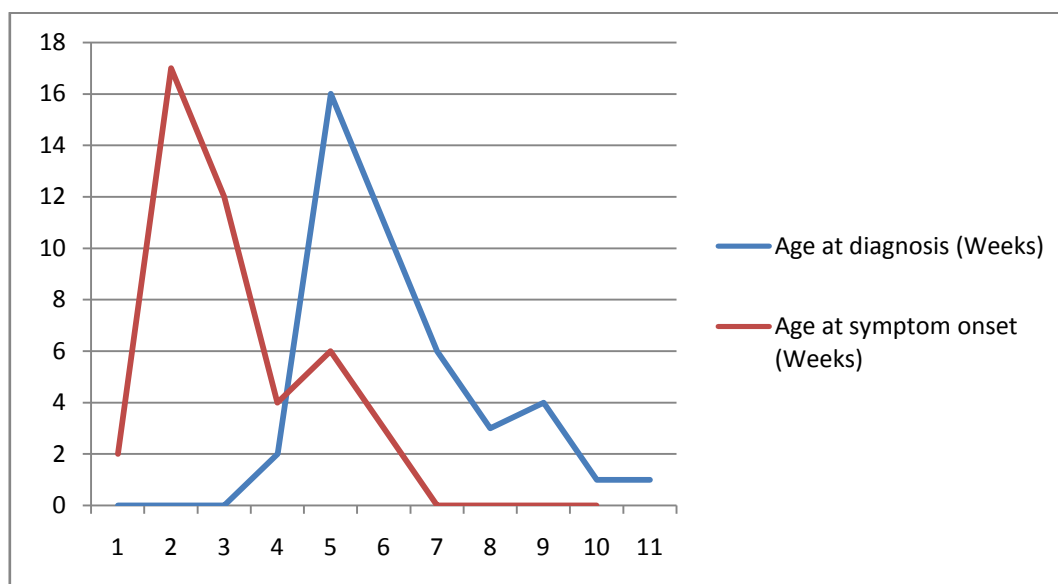


Figure 1. Line chart showing age at diagnosis and symptom onset.

In all the infants the ultrasonic findings were diagnostic of IHPS. The mean length of pyloric muscle was  $19.18 \pm 1.99$  mm (ranged 16 – 23 mm), and the mean thickness of pyloric circular muscle ranged from 4 – 6 mm (mean of  $5.02 \pm 0.82$  mm). No patient required any other diagnostic investigation for confirmation of diagnosis.

The hypochloraemia ( $Cl < 95$  mmol/L) was found in 31 of 44 (77.27 %) infants with the mean of  $92.64 \pm 5.27$  mmol/L (range of 82 – 105 mmol/L). Hyponatraemia ( $< 135$  mmol/L) was observed in only 23 patients (52.27 %) with the mean of  $131 \pm 6.22$  mmol/L (range of 116 – 140 mmol/L), and 27 patients (61.36 %) displaying hypokalemia ( $< 3.5$  mmol/L) with the mean of  $3.45 \pm 0.32$  mmol/L (range of 2.9 – 4.3 mmol/L). The results of arterial blood gas analysis were available for 33 (75 %) patients at admission. An elevated bicarbonate level ( $HCO_3 > 25$  mmol/L) was observed in 27 patients (81.8 %) with the mean level of  $29.21 \pm 3.97$  mmol/L with the range of 23 – 38 mmol/L and pH was above 7.45 in 26 of 33 patients (78.79 %) with the mean of  $7.48 \pm 0.38$  (range 7.4 – 7.55).

The mean duration of time taken for the dehydration, acid-base imbalance and electrolyte imbalance to be corrected before the surgery was  $1.39 \pm 0.49$  days (range of 1 – 2 days) and the mean duration of hospital stay was  $3.36 \pm 0.49$  days (range of 3 – 4 days). There was no surgical site infection following the surgery. The feeding was initiated after 12 – 24 hours after the surgery. Twelve (29.55 %) patients had occasional episodes of regurgitation and vomiting for 2 – 3 days following initiation of feeding which were self-limiting. There was no mortality in the study population.

#### IV. Discussion

IHPS is the most common gastrointestinal disease in the first few weeks of life. The male-to-female ratio is about 4:1, ranging from 2.5:1 to 5.5:1 [1,2,16]. In our series, the male to female ratio was 4.5:1 against the 6.02:1 of Feng et al [8]. The ability to palpate the olive varies with the experience and persistence of the examiner and ranges from 40-100% [9]. In our study, olive was palpable only in 32 patients (72.72 %). In most cases, the typical projectile, non-bilious vomiting usually occurred between the age of 2 weeks and 8 weeks [2,5]. The median age at presentation was 6 weeks in our study against 5 weeks of other studies [10,11]. The median symptom duration between age of symptom onset and age of diagnosis was about 7 to 8 days [10,12]. In our study the median symptom duration was 22 days which was comparable with 25 days of Feng et al [8].

The weight at presentation was  $3.77 \pm 0.37$  kilograms which is comparable with  $3.85 \pm 0.89$  kilograms of Feng et al [8]. Though IHPS is characterized by familial occurrence, there was no family history in our study.

Only 5 cases (11.36 %) had co-existing other congenital defects against the finding of the Feng et al (65 of 316 cases, 20.6 %) [8]. Associated congenital anomalies may be present in 6–20% of the patients with IHPS [13]. The cardiovascular system congenital defects were the most common, followed by the gastrointestinal tract congenital defects and central nervous system congenital defects [8].

Gotley found 61% of patients had elevated bicarbonate and 29% of infants had hypochloreaemia at admission [10]. In a study of 283 infants, Papadakis found that 88% had no electrolyte abnormalities on admission [14]. But in our study, 81.8 % had elevated bicarbonate and 77.27 % had hypochloreaemia, 52.27 % hyponatraemia and 61.36 % hypokalemia. More patients had electrolyte and acid-base imbalanced as compared to other studies as our patients presented with longer symptom duration (mean - 22.2 days) which was in accordance with the finding of authors that the duration of symptoms had an important influence on the biochemical parameters [10,12,15,16].

Ultrasonography has a high sensitivity and specificity in diagnosing IHPS with an accuracy approaching 100% in diagnosing IHPS [17,18]. Therefore, ultrasound examination has been largely applied to diagnose IHPS. In our study, the ultrasonography findings were diagnostic in all the patients (accuracy of 100 %) as proven by the intra-operative findings. The UGI barium series requiring oral contrast with the risk of aspiration to indirectly outline the pylorus and the exposure to ionizing radiation made a rare choice for diagnosing IHPS [17,18].

Many studies have described the pyloric muscle thickness of 3 – 4.5 mm as borderline [7,18,19] and muscle wall thickness of 2 mm is generally considered normal. According to Hernanz-Schulman[18], the circular muscle thickness ranged from 3.3 to 7.0 mm, and the mean was 4.660.7 mm. In our study, the thickness varied between 4 and 6 mm, with the mean of  $5.02 \pm 0.82$  mm, and the diagnostic accuracy by ultrasound was 100 %. The mean length of the pyloric channel was 19.18 mm against the findings of Feng et al [8] which was  $20.8 \pm 3.8$  mm. Many authors have described different abnormal length of the pyloric channel in IHPS; Rohrschneider et al [19] found that pathologic limits were 15 mm for pyloric length, whereas Reed et al [20] believed the abnormal elongation of the pyloric canal is defined as greater than 12 mm in length for IHPS. So many scholars have concluded that the muscle thickness was the most accurate criterion to make the diagnosis, while the length of the pyloric channel is seemingly less important, although this measurement may be useful in cases where muscle thickness is within borderline [7,19].

Vomiting following pyloromyotomy is usually self limiting. Although frequency of vomiting is related to type of feeding regimen, duration is independent of the timetable or composition of post-operative dietary regimen [21]. Duration of post-procedure vomiting is variable, with reports of 3.5% to 24% of infants with continued emesis more than 48 hours after surgery [21]. In our study, twelve (29.55 %) patients had vomiting after the initiation of feeding upto 2 – 3 days after the surgery.

## V. Conclusion

Maximum patients were diagnosed in the 5<sup>th</sup> and 6<sup>th</sup> week (61.36 %), even though 65.9 % had the initial symptom onset in the 2<sup>nd</sup> and 3<sup>rd</sup> week with mean delay in diagnosis of 22 days. Most of the patients suffered from acid-base imbalance, hypokalemia, hypochloreaemia and hyponatraemia. So, any infants with persistent vomiting in the first few weeks after birth, IHPS should be considered to facilitate early diagnosis with the resultant decrease in the morbidity of the late diagnosis.

## Acknowledgement:

We are grateful to the hospital authority and ethical committee for allowing us to conduct the study as well as the parents for allowing us to use the clinical details for purely academic purposes.

## References

- [1]. Habbick BF, To T. Incidence of infantile hypertrophic pyloric stenosis in Saskatchewan, 1970–85. *CMAJ* 1989; 140:395–398.
- [2]. Applegate MS, Druschel CM. The epidemiology of infantile hypertrophicpyloric stenosis in New York State, 1983 to 1990. *Arch PediatrAdolesc Med*,1995; 149:1123–1129.
- [3]. Yesildag E, Buyukunal SN. Pyloric stenosis in in vitro fertilized triplets—is it a coincidence? *J PediatrSurg*.2005; 40:1802–1804.
- [4]. Willschke H, Machata AM, Rebhandl W, et al. Management of hypertrophic pylorus stenosis with ultrasound guided single shot epidural anaesthesia --- a retrospective analysis of 20 cases. *Pae-diatrAnaesth*. 2011;21:110---5
- [5]. Rollins MD, Shields MD, Quinn RJ, Wooldridge MA. Pyloric stenosis: congenital or acquired? *Arch Dis Child*,1989; 64:138–139.
- [6]. Mitchell LE, Risch N. The genetics of infantile hypertrophic pyloric stenosis. A reanalysis. *Am J Dis Child*,1993; 147:1203–1211.
- [7]. Hernanz-Schulman M. Infantile hypertrophic pyloric stenosis. *Radiology*,2003;227:319–331.
- [8]. Feng Z, Nie Y, Zhang Y, Li Q, Xia H, Gong S, Huang H. The Clinical Features of Infantile Hypertrophic Pyloric Stenosis in Chinese Han Population: Analysis from1998 to 2010. *PLoS ONE*,2014; 9(2): e88925.
- [9]. Murtagh K., Perry P, Corlett M, Fraser I. Infantile hypertrophic pyloric stenosis. *Dig Dis*. 1992; 10:190-8.
- [10]. Gotley LM, Blanch A, Kimble R, Frawley K, Acworth JP. Pyloric stenosis: a retrospective study of an Australian population. *Emerg Med Australas*,2009; 21:407–413.
- [11]. Walker K, Halliday R, Holland AJ, Karskens C, Badawi N. Early developmental outcome of infants with infantile hypertrophic pyloric stenosis. *J PediatrSurg* 2010; 45:2369–2372.

- [12]. Shaoul R, Enav B, Steiner Z, Mogilner J, Jaffe M. Clinical presentation of pyloric stenosis: the change is in our hands. *Isr Med Assoc J*,2004; 6:134–137.
- [13]. Elinoff JM, Liu D, Guandalini S, Waggoner DJ. Familial pyloric stenosis associated with developmental delays. *J PediatrGastroenterolNutr.* 2005;41:129-32.
- [14]. Papadakis K, Chen EA, Luks FI, Lessin MS, Wesselhoeft CW Jr, et al. The changing presentation of pyloric stenosis. *Am J Emerg Med.*1999; 17:67–69.
- [15]. Beasley SW, Hudson I, Yuen HP, Jones PG. Influence of age, sex,duration of symptoms and dehydration of serum electrolytes in hypertrophic pyloric stenosis. *AustPaediatr J.*1986; 22:193–197.
- [16]. Breaux CW Jr, Hood JS, Georgeson KE. The significance of alkalosis andhypochloremia in hypertrophic pyloric stenosis. *J PediatrSurg.*1989; 24:1250–1252.
- [17]. McVay MR, Copeland DR, McMahon LE, Cospier GH, McCallie TG, et al. Surgeon-performed ultrasound for diagnosis of pyloric stenosis is accurate, reproducible, and clinically valuable. *J PediatrSurg.*2009; 44:169–171;discussion 171–172.
- [18]. Hernanz-Schulman M, Sells LL, Ambrosino MM, Heller RM, Stein SM, et al. Hypertrophic pyloric stenosis in the infant without a palpable olive:accuracy of sonographic diagnosis. *Radiology.*1994; 193:771–776.
- [19]. Rohrschneider WK, Mittnacht H, Darge K, Troger J. Pyloric muscle in asymptomatic infants: sonographic evaluation and discrimination from idiopathic hypertrophic pyloric stenosis. *PediatrRadiol.*1998; 28:429–434.
- [20]. Reed AA, Michael K. Hypertrophic pyloric stenosis. *J Diagn MedSonography.*2010; 26:157–160.
- [21]. Carpenter RO, Schaffer RL, Maeso CE, Sasan F, Nuchtern JG, Jaksic T, Harberg FJ, Wesson DE, Brandt ML. Postoperative ad lib feeding for hypertrophic pyloric stenosis *J Pediatr Surg.*1999; 34:959-61.