

Mucin Secreting Adenocarcinoma Within A Solitary Peutz-Jeghers Type Of Hamartomatous Polyp In The Rectum- A Case Report

¹Dr Sujata S. Giriyan , ²Dr Sangeeta S.

¹Professor and HOD, ²Postgraduate

(Department of Pathology, Karnataka Institute of Medical Sciences, Hubballi, Karnantaka, India.)

Abstract: A solitary rectal hamartomatous polyp is rare and it is considered to be either a variant of Peutz-Jeghers syndrome (PJS) or a separate entity. Patients do not have cutaneous manifestations and have only one hamartomatous polyp. Most are incidentally diagnosed during endoscopy/colonoscopy for other indications. This report describes the case of a 18-year-old female who presented with abdominal pain and per rectal bleeding. The initial colonoscopy showed large polypoidal pedunculated mass arising from lateral wall of rectum with CT Scan abdomen and pelvis showing asymmetrical thickening of rectal wall noted starting 1.5 cms from anal opening. She was diagnosed as solitary hamartomatous polyp with mucin secreting adenocarcinoma rectum ,which was treated by surgery.

Key words : Peutz-Jeghers polyp, Hamartomatous polyp, Adenocarcinoma, rectum.

I. Introduction

Peutz-Jeghers syndrome is a rare, autosomal-dominant disorder characterized by hamartomatous polyps in any part of the alimentary tract and mucocutaneous pigmentation, first described by Jan Peutz in 1921[1]. Recently, a patient with a Peutz-Jeghers polyp without either mucocutaneous pigmentation or a positive family history was described as a case of solitary Peutz-Jeghers-type hamartomatous polyp. It has been suggested that this condition should be considered as a clinical entity different from Peutz-Jeghers syndrome[2]. A solitary Peutz-Jeghers-type hamartomatous polyp is histologically characterized by tree-like branching of smooth muscle fibers, with a core of smooth muscle, covered by mucosal tissue of near-normal appearance[3]. A solitary Peutz-Jeghers-type hamartomatous polyp in the rectum is rare. Here we describe a case of solitary Peutz-Jeghers-type hamartomatous polyp and their endoscopic and histopathological findings in detail with a focus of adenocarcinoma present within a solitary Peutz-Jeghers-type hamartomatous polyp[4].

II. Case Report

An 18 years female presented to the surgical Out Patient Department with complaints of bleeding per rectum and mass per anum since 2 months. There was no significant family history of PJS.

On examination there was no mucocutaneous pigmentation. Upper gastrointestinal endoscopy was unremarkable. On colonoscopy a large polypoidal pedunculated mass was seen arising from lateral wall of rectum and rest of the colon appearing normal. Polypectomy was done and sent for the histopathological examination. On Gross, specimen consisted of single piece of grey brown tissue measuring 6x5x2.5cms. Cut section showed mucoid areas. On Microscopy, sections showed a polyp with smooth muscles of muscularis mucosa showing tree-like branching covered partly with benign mucous secreting colonic epithelium and partly showing a tumour consisting of round to polygonal mucin secreting cells with vesicular nucleus and prominent nucleoli with pools of mucin and the tumour cells floating in it. Mitotic figures and signet ring cells are seen.

Features suggestive of a Mucin secreting adenocarcinoma within the Puetz-Jheghers type of hamartomatous polyp in rectum. Repeat colonoscopic biopsy from the polypectomy site showed sections free from tumour.

III. Discussion

As compared with PJS, Peutz-Jeghers type hamartomatous polyps are diagnosed at a more advanced age, in the absence of mutation of the STK11/LKB-1 gene, and without familial history and mucocutaneous pigmentation [5]. Previous reports showed that polyps due to PJS had 3-6% of neoplastic change, such as adenomas or carcinomas [6]. Although solitary Peutz-Jeghers type hamartomatous polyps have been considered to show a lower potential for malignant transformation as compared to PJS, three cases of solitary Peutz-Jeghers type hamartomatous polyps with malignant components have been reported since 2008, and the total malignant transformation rate of solitary Peutz-Jehgher type hamartomatous polyps was 4 out of 27 (14.8%) [7].

The most serious problem in PJS is an increased risk of cancer in the gastrointestinal tract. The occurrence of cancer in the gastrointestinal tract has been reported in 20-25% of patients with PJS, and a risk of cancer in other organs has also been reported, including the ovary, breast, bladder, pancreas and thyroid [8].

IV. Figures

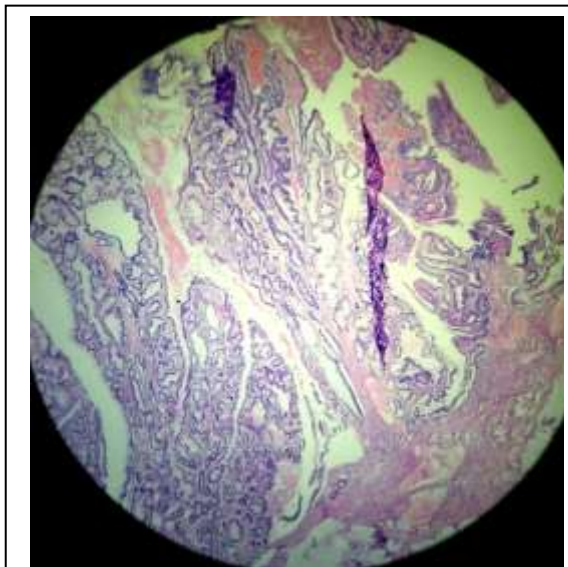


Fig 1-Microscopy showing a polyp with smooth muscles of muscularis mucosa showing tree-like branching invading between the epithelium. H&E 4x10

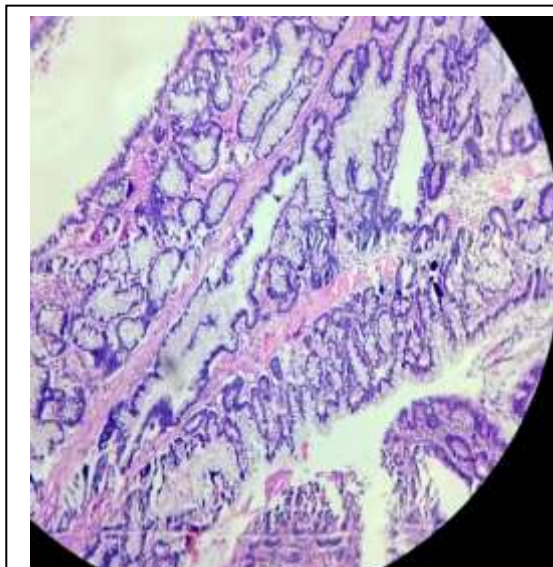


Fig 2- Similar picture showing the smooth muscle bundles invading through muscularis propria. H&E 4x10

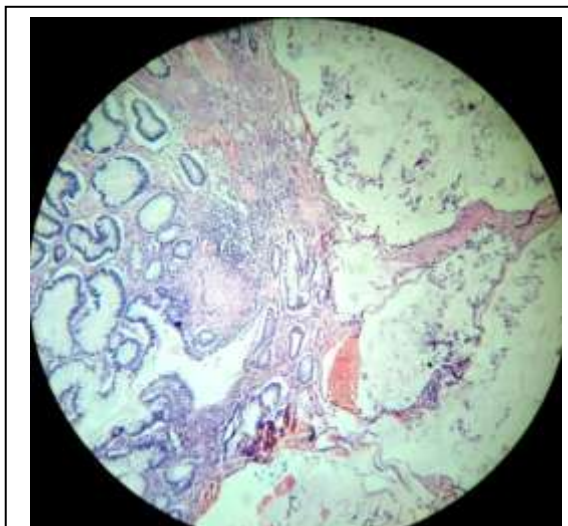


Fig 3-Microscopy showing partly benign mucous secreting epithelium with tumour cells floating in the mucin pool. (H&E 10x10)

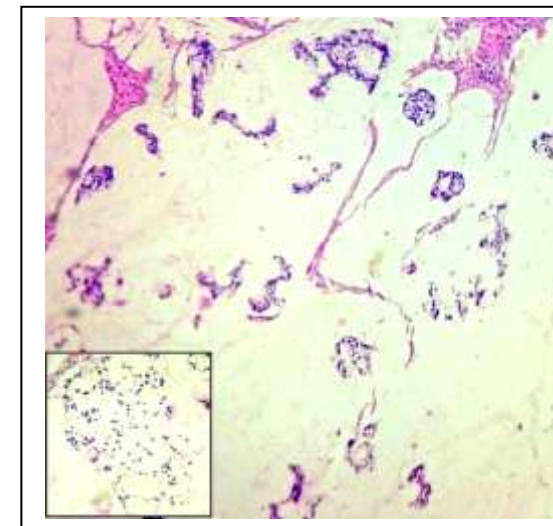


Fig 4-Microscopy showing tumour cells floating in mucin pool. (H&E 10x10)

V. Conclusion

Peutz-Jeghers type of hamartomatous polyp are generally considered to have low malignant potential compared to polyp associated with PJS. Though it has a low malignant potential, it should be treated by endoscopic or surgical resection and the patient needs whole-body screening.

References

- [1]. Jeghers H, McKusick VA, Katz KH. Generalized intestinal polyposis and melanin spots of the oral mucosa, lips and digits; a syndrome of diagnostic significance. *N Engl J Med.* 1949;241:1031–1036.
- [2]. Acea NB, Taboada FL, Parajo CA, Gayoso GR, Gomez RD, Sanchez GF, Sogo MC. Solitary hamartomatous duodenal polyp; a different entity: report of a case and review of the literature. *Surg Today.* 1993;23:1074–1077.
- [3]. Nakayama H, Fujii M, Kimura A, Kajihara H. A solitary Peutz-Jeghers-type hamartomatous polyp of the rectum: report of a case and review of the literature. *Jpn J Clin Oncol.* 1996;26:273–276.
- [4]. Perzin KH, Bridge MF. Adenomatous and carcinomatous changes in hamartomatous polyps of the small intestine (Peutz-Jeghers syndrome): report of a case and review of the literature. *Cancer* 1982;49:971–983.
- [5]. Kitaoka F, Shiogama T, Mizutani A, Tsurunaga Y, Fukui H, Higami Y, Shimokawa I, Taguchi T, Kanematsu T: A solitary Peutz-Jeghers-type hamartomatous polyp in the duodenum. A case report including results of mutation analysis. *Digestion* 2004, 69(2):79-82.
- [6]. Narita T, Eto T, Ito T. Peutz-Jeghers syndrome with adenomas and adenocarcinomas in colonic polyps. *Am J Surg Pathol.* 1987;11:76–81.
- [7]. Bartholomew LG, Moore CE, Dahlin DC, Waugh JM: Intestinal polyposis associated with mucocutaneous pigmentation. *Surg Gynecol Obstet* 1962, 115:1-11.
- [8]. Dodds WJ, Schulte WJ, Hensley GT, Hogan WJ: Peutz-Jeghers syndrome and gastrointestinal malignancy. *Am J Roentgenol Radium Ther Nucl Med* 1972, 115:374-377.