

Third Molar as Age Marker in Adolescents: Large Sample Sized Retrospective Study

MDDr. Lenka Foltasová¹, MUDr. Přemysl Krejčí, Ph.D.¹, Stomatolog Yulia Morozova, Ph.D.¹, MDDr. Iva Voborná¹, MDDr. Lucie Čihalová¹

¹ (Institute of Dentistry and Oral Sciences, Faculty of Medicine and Dentistry, Palacký University, Olomouc, Czech Republic)

Abstract:

Aim: In most countries the age of 18 years represents a threshold of majority. From the legal point of view, to be able to treat a person as a minor or an adult, it is necessary to determine whether an individual has reached this limit. The aim of this study was to answer the question whether the development of wisdom teeth can provide information on age estimation of an individual for medicolegal purposes.

Material and Methods: Our study evaluated a set of 1542 digital panoramic images in order to assess the mineralization status of upper and lower right third molars of Czech males and females aged between 14 – 25 years. The evaluation was carried out by using the eight grade system of Demirjian et al. For each developmental stage, the probability of an individual to be at least 18 years old was evaluated. Data were calculated by using statistical tools in order to provide predictive values.

Conclusion: For both genders, stage H can be used as a reference to estimate whether a subject is likely to be major, with 96,0 % and 99,7% correct predictions in men and women, respectively. Described data may provide references of the Czech population for the purposes of forensic investigation.

Keywords: Dental age; Odontology; Ortodontomogram; Tooth formation; Third molar

I. Introduction

The age of majority is generally considered as a threshold of adulthood. It is the chronological moment when an adolescent reaches adult status. In most countries, including the Czech Republic, the legal age of majority and criminal responsibility is stated as 18 years of age. For the medicolegal purposes, the attainment of adult status is a significant milestone. The age estimation during this period may be required not only to distinguish a juvenile from an adult in criminal proceedings but also for age estimation in relation to social benefits, occupation, marriage and immigration policy. Nowadays, there is a growing demand for appropriate medical tests aimed at estimating the approximate age of supposed minors. This is of great importance when an individual is without personal documents or other means of identification. Legal consequences can be quite different in case of unknown age of a juvenile or an adult.

According to the recommendations of the interdisciplinary Study Group on Forensic Age Diagnostics [1], age estimation of living persons in this specific period of life should include a physical examination, an X-ray of the left hand and dental age estimation based on dental status examination and evaluation of panoramic radiograph. Radiographic evaluation of dental development of third molars should be an integral part for forensic age estimation of young adults. Nevertheless, third molars still remain to the group of teeth with the highest anatomical variability [2] and therefore this evaluation is not applicable in cases of third molar agenesis or malformation.

Due to the fact that all other permanent teeth have finished their development in this age group [3], third molars represent the only developing teeth after 14 years of age and are therefore considered as a unique source of information for dental age assessment. Additionally, dental development is less affected by changes in nutrition and endocrine status than other growth factors. [4] Also, it has been proved that dental development relates more closely to chronological age than skeletal, somatic or sexual maturity indicators. [5] Nevertheless, recent studies have showed that the third molar mineralization is a very specific process and may differ in relation to ethnicity. [6] It is highly recommended to use population specific reference data in forensic age estimation of living people. Therefore, this study aims to establish Czech reference data on third molar mineralization evaluated according to the eight stage system proposed by Demirjian et al. (1973). [7] The probability that an adolescent with fully developed third molar is at least 18 years old was evaluated according to Mincer et al. [8]

II. Material and methods

Digital panoramic images of 1542 Czech individuals (546 males and 996 females) with known chronological age and gender were retrospectively collected for this study at Institute of Dentistry and Oral Sciences, Faculty of Medicine and Dentistry of Palacký University in Olomouc, Czech Republic. The age of individuals in this collected sample ranged from 14 to 25 years. The selection of the subjects was based on the following criteria:

Inclusion criteria:

1. Patient belongs to age group of 14-25 years
2. Age proof in the form of ID card or driving license

Exclusion criteria:

1. Dental anomaly patterns visible on OPG [9-10]
 - Absent teeth
 - Microform teeth (e.g., peg-shaped lateral incisor)
 - Tooth-size reduction (generalized or localized)
 - Delay in tooth formation and eruption (generalized or localized)
 - Infraocclusion
 - Palatal displacement of canine
 - Maxillary canine-first premolar transposition
 - Mandibular lateral incisor-canine transposition
 - Distal angulation of unerupted mandibular second premolar

2. Adequate visibility of evaluated area with no artefacts

After application of exclusion criteria, 975 orthopantograms were selected for evaluation. Each of the OPG film was viewed on X-ray viewer (Planmeca Romexis Software) by six examiners. A preliminary training session was held to unite examiners' grading. In each instance, the stage judged closest was recorded. On questionable borderline grades, inter-examiner consultation was conducted to enhance accuracy. This intentional use of multiple examiners introduced greater variability into the estimates than if differences in judgments were the result of just one of them.

Each upper and lower right third molar of 975 orthopantograms was assessed according to Demirjian's scheme of development (Fig. 1), as follows:

- Stage A: Cusp tips are mineralized but have not yet coalesced.
- Stage B: Mineralized cusps are united so the mature coronal morphology is well defined.
- Stage C: The crown is about half formed; the pulp chamber is evident and dentinal deposition is occurring.
- Stage D: Crown formation is complete to the dentinoenamel junction. The pulp chamber has a trapezoidal form.
- Stage E: Formation of the inter-radicular bifurcation has begun. Root length is less than the crown length.
- Stage F: Root length is at least as great as crown length. Roots have funnel-shaped endings.
- Stage G: Root walls are parallel, but apices remain open.
- Stage H: Apical ends of the roots are completely closed, and the periodontal membrane has a uniform width around the root.

Although not originally devised by Demirjian et al. to quantify third molars maturation, this method has been previously applied for this purpose in several scientific papers and performed best not only for intra- and inter-examiner agreement, but also for the correlation between estimated and true age. [11] Also, Demirjian's original method was adopted for use on the third molars by Mincer et al. (1993) [8] whose recommendations our study followed. According to results of Mincer's study, the onset of root maturity (stage H) in the third molar is quite reliable marker indicating that an individual is likely to be at least 18 years of age. Data of this study were recorded to check the practicability of Mincer's premise in the Czech population.

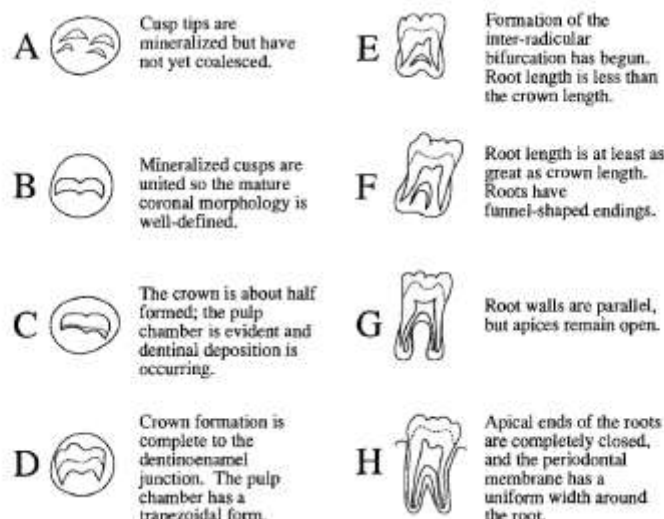


Figure 1 Schematic drawings and definitions of the eight stages of crown and root formation used to score third molar development, modified from Demirjian et al. [7]

III. Results

Collected data were processed accordingly and were subject to statistical analysis. Mean dental ages and standard deviations were calculated for each developmental stage of tooth 18 and 48 using Mann-Whitney U test (Table 1 and Table 2) separately for each gender. Only 53% of the cases showed the same grade of formation in the maxilla and mandible. Grades A and B occurred rarely if at all in the age interval under examination. Results indicated that females reach each of the formative stages at an earlier age than males in almost all developmental stages regarding sexual dimorphism. Maxillary arch mean stage developmental ages were less than the mandibular arch mean ages in both genders. Consequently, there is a trend of third molar development to be more advanced in the maxilla than in the mandible. As a result, earlier stages in teeth development (D, E and F) for both maxillary and mandibular third molars indicate that the person in question is younger than 18 years. Stage H indicates that the person has reached 18 or more years and therefore should be considered as an adult.

The likelihood of an individual being older than 18 years when third molar reaches stage H is described in Table 3. The results show very high probability, especially as to women.

The correlation between chronological age and predicted age is demonstrated in Figure 2.

Table 1 Mean ages and standard deviations at each stage of tooth 18 (Mann-Whitney U test)

Developmental stages of 18		B	C	D	E	F	G	H
Male	Mean age	15.2	15.1	15.5	16.0	16.4	18.0	20.2
	SD	1.48	1.03	1.43	1.51	1.48	2.08	2.65
Female	Mean age	15.0	14.9	14.8	15.5	15.7	16.7	19.0
	SD	0	0.88	0.67	1.25	1.19	1.46	2.10

Table 2 Mean ages and standard deviations at each stage of tooth 48 (Mann-Whitney U test)

Developmental stages of 48		A	B	C	D	E	F	G	H
Male	Mean age	14.5	15.4	15.2	15.7	16.3	17.0	18.0	21.1
	SD	0.71	1.58	1.10	1.65	1.67	1.83	1.95	2.30
Female	Mean age	15.0	15.0	15.2	14.8	15.5	16.1	17.1	19.7
	SD	-	0.63	1.37	0.85	1.12	1.41	1.08	1.99

Table 3 Likelihood (%) of a Czech individual being older than 18 years based on Demirjian's stage H

	Male	Female
18	96.5	99.8
48	95.5	99.6
Mean	96.0	99.7

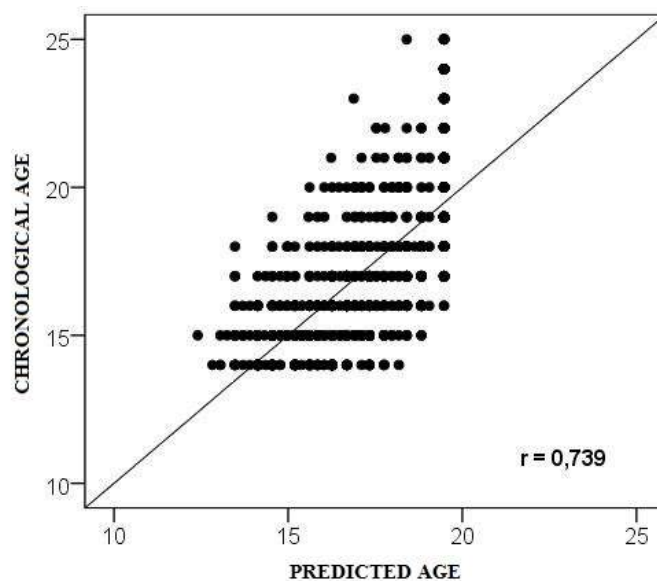


Figure 2 Correlation between chronological age and predicted age (teeth 18 and 48)

IV. Discussion

Age estimation of adolescents still remain a challenge for forensic medicine. Adolescence is a crucial period, particularly in medicolegal questions, where it is essential to differentiate a juvenile from an adult. Numerous reports have been published on the age estimation issue concerning adolescents and young adults in which the assessment of third molar development was investigated. Unfortunately, very few feasible alternative methods for estimation of chronologic age can be used in mid teens since all other permanent teeth have finished their development in this age group. [12] Mincer et al. introduced in 1993 quite different approach. As concluded in the A.B.F.O study, third molar examination may provide reliable accuracy for the likelihood that a person is at least 18 years old, instead of the estimation of exact chronological age. Demirjian's developmental stage H could serve as a useful developmental marker to answer the question whether an individual should be already considered as an adult. This stage is characterized by completely mineralized tooth with closed apex. Therefore, in our study, we investigated the probability of a Czech adolescent being major, i.e. to be older than 18 years as described by the Czech law. According to our findings, the recognition of earlier stages in teeth development (stages A - E) indicates that the person in question is younger than 18 years. Finished third molar mineralization (stage H) indicates that the probability that the juvenile being at least 18 years old is 96 % and 99,7% as to men and women, respectively. Since the previous studies have showed rather diverse results arising from sexual dimorphism, we have examined the mean ages of each stage for male and female patients. [13]

Concerning asymmetry between upper and lower arches, the study at hand has demonstrated that the wisdom teeth of Czech adolescents shows different degrees of development in maxilla and mandible. Third molar development tends to be more advanced in the maxilla than in the mandible. Similar observation was recognized by Mincer et al. [8] Consequently, these differences should be considered in the forensic investigation.

Regarding sexual dimorphism, our results indicate that females attained Demirjian formation stages earlier than males. This observation differs from recent studies, which reported lower mean age as to males in different population. [14-15]

The wisdom tooth is definitely not an ideal developmental marker as it is the most variable tooth in the dentition with regard to size, time of formation, and time of eruption, and it is often congenitally absent, malformed, impacted, or extracted. [8] It has been proved that development of each individual can be affected by genetic, racial, nutritional, climatic, hormonal and environmental factors. [16-17] Nevertheless, despite its variability, if present, it can be of a great value in cases where we need to decide whether a person is major or not.

V. Conclusion

We conducted the present research to respond to the recently rising need of population-based information on third molar development. Described data may provide the Czech representative references on wisdom tooth mineralization for the medicolegal purposes inclusive of the sex-specific mean ages for each stage of third molar formation. The probability of a Czech individual with fully developed third molar to be at least 18 years old was proved as very high.

Nevertheless, only limited conclusions can be made from a single study, therefore future research is recommended in order to make population specific reference data accessible for practical use.

References

- [1] A.Schmeling, H. J. Kaatsch, B. Marré, W. Reisinger, T. Riepert, S. Ritz-Timme, F.W. Rösing, K. Röttscher, G. Geserick, Empfehlungen für die Altersdiagnostik bei Lebenden im Strafverfahren, *Rechtsmedizin*, 11(1), 2001, 1–3.
- [2] J. Thorson, U. Hagg, The accuracy and precision of the third mandibular molar as an indicator of chronological age, *Swedish dental journal*, 15(1), 1991, 15–22.
- [3] A. Demisch, P. Wartmann, Calcification of the mandibular third molar and its relation to skeletal and chronological age in children, *Child development*, 27(4), 1956, 459–473.
- [4] R. Nykanen, L. Espeland, S. I Kvaal, O. Krogstad, Validity of Demirjian method for dental age estimation when applied to Norwegian children, *Acta Odontologica Scandinavica*, 56(4), 1998, 238-244.
- [5] A. B. Lewis, S. M. Garn, The relationship between tooth formation and other maturational factors, *The Angle Orthodontist*, 30(2), 1960, 70-77.
- [6] A. Olze, A. Schmeling, M. Taniguchi, H. Maeda, P. van Niekerk, K. D. Wernecke, and G. Geserick, Forensic age estimation in living subjects: the ethnic factor in wisdom tooth mineralization, *International Journal of Legal Medicine*, 118(3), 2004, 170- 173.
- [7] A. Demirjian, H. Goldstein, J.M. Tanner, A new system of dental age assessment, *Human Biology*, 45(2), 1973, 221–227.
- [8] H. H. Mincer, E. F. Harris, and H. E. Berryman, The A.B.F.O. Study of Third Molar Development and Its Use As an Estimator of Chronological Age, *Journal of Forensic Sciences*, 38(2), 1993, 379-390.
- [9] S. Peck, Dental Anomaly Patterns (DAP), *The Angle Orthodontist*, 79(5), 2009, 1015-1016.
- [10] I. Dubovská, and J. Heřmánek, Lateral Incisor Morphology In Patients With Impacted Canine: A CT Study, *IOSR Journal of Dental and Medical Sciences*, 14(7), 2015, 01-05.
- [11] K. S. Dhanjal, M. K. Bhardwaj, and H. M. Liversidge, Reproducibility of radiographic stage assessment of third molars, *Forensic science international*, 159, 2006, 74-77.
- [12] A. J. Lewis, K. Boaz, K. R. Nagesh, N. Srikant, N- Gupta, K. P. Nandita, and N.Manaktala, Demirjian's method in the estimation of age: A study on human third molars, *Journal of forensic dental sciences*, 7(2), 2015, 153.
- [13] G. Y. Levesque, A. Demirjian, R. Tanguay, Sexual dimorphism in the development, emergence and agenesis of the mandibular third molar, *Journal of Dental Research*, 60(10), 1981; 1735-1741.
- [14] A. De Salvia, C. Calzetta, M. Orrico, and D. De Leo, Third mandibular molar radiological development as an indicator of chronological age in a European population. *Forensic science international*, 146, 2004, 9-12.
- [15] A. Olze, M. Taniguchi, A.Schmeling, B. L. Zhu, Y. Yamada, H. Maeda, and G. Geserick, Comparative study on the chronology of third molar mineralization in a Japanese and a German population. *Legal Medicine*, 5, 2003, 256-260.
- [16] L. Kullman, G. Johanson, and L. Akesson, Root development of the lower third molar and its relation to chronological age, *Swedish dental journal*, 16(4), 1991, 161-167.
- [17] C. M. Nolla, The development of permanent teeth, PhD diss., University of Michigan, 1952.