

## Segmental Fractures of the Forearm- Outcome Analysis of Various Management Strategies

Dr. V. Thirunarayanan<sup>1</sup>, Dr. D. R. Ramprasath<sup>1</sup>, Dr. Arjun Rajan<sup>1</sup>

<sup>1</sup>(Department of Orthopaedic Surgery, Government Royapettah Hospital, Chennai, India)

---

**Abstract:** Segmental fractures of the forearm, unlike other bones, are encountered only rarely, hence creating various dilemmas in their treatment aspect. In our study, we have managed 11 patients with 12 segmental forearm fractures, utilising various combinations of treatments including conservative management. Nine forearms underwent plating alone, 2 forearms underwent plating and elastic nailing and 1 was treated with elastic nails alone. The outcome was analysed based on union, ROM and grip strength. Early union and better functional outcome was observed in patients operated with plate alone. Nailing does not provide rotational stability but can be used in selected patients (like compound fractures). External fixation has not been used in our study.

**Keywords-** forearm, fracture, radius, segmental, ulna

---

### I. Introduction

Although unifocal fractures of forearm are very commonly encountered, segmental (bifocal) fractures of forearm are very rare with a reported incidence of 0.1% of all fractures[1]. These fractures, apart from being segmental, are complicated by associated comminution, soft tissue injury and dislocations. Since literature regarding these types of fractures is very minimal, consensus regarding its optimal management for successful outcome is also not possible. The aim of our study is to analyse the functional and radiological outcome of fixation of segmental fractures of forearm.

### II. Materials And Methods

Our study is a retrospective case series involving 11 patients (12 forearms) with a sex ratio M:F= 9:2. There were 10 adults and 1 child. Study period was from June 2009 to October 2015 with a mean follow up duration of 17.9 months (5 months to 6 years). Study was done at Department of Orthopaedic Surgery, Government Royapettah Hospital, Chennai, India.

Out of the 11 patients (which includes one patient with segmental fracture in both forearms), 8 patients sustained injury due to road traffic accident, 1 patient was assaulted, 1 patient had fall of wall over his forearm and 1 child had history of fall from height. Those injuries due to assault and fall of wall were compound injuries.

Nine forearms underwent plating alone. Two forearms underwent plating + nailing (in one patient, ulna underwent nailing since it was undisplaced, in the other patient, radius underwent nailing since there was 1 cm open wound over the fracture site). One patient underwent nailing for radius and ulna, since there was a 3x2cm open wound overlying both radius as well as ulna.

In one patient who had segmental fracture of ulna alone, one fracture was missed (Fig. 1), hence the other fracture was plated. Only in the post operative X-ray, the other fracture which was displaced, was detected and was treated conservatively with long arm cast. The paediatric patient (Fig. 2a) who had segmental fracture of radius was fixed with 3.5mm Asian DCP for one segment and Kirschner wires for the other segment (Fig. 2b) (since it was a Salter and Harris type II epiphyseal injury). In the patient with bilateral forearm fracture, right side was Monteggia fracture-dislocation (Fig. 3a) with segmental ulna fracture. In this case the radial head got reduced once the ulna was fixed with long LCP (Fig. 3b).

All patients were operated through volar Henry's approach for radius and direct approach for ulna. In one patient (Fig. 4), with segmental fracture radius, the middle segment was small, with only pronator teres as soft tissue attachment. Hence in this case, in order to avoid the middle segment getting devoid of soft tissue attachment, the plate was slid dorsally and fixation done. In one patient who had comminuted segmental fracture of ulna, augmentation with autologous bone grafting was done. In all cases, the less displaced and less comminuted bone was fixed first.

The post-operative protocol included splinting for a period of 4 weeks, radiological examination at 1, 3, 5 and 10 months after surgery. Range of motion (of elbow, forearm and wrist) and grip strength were also assessed at every follow up. Active assisted mobilisation was done until radiological union and normal activities were allowed after radiological union.

The following procedure was done to assess the grip strength (Lansbury method) (Fig. 5a). The sphygmomanometer cuff inflated to 20mmHg was placed in the palm of operated side. The patient was advised to grip and compress the cuff to the maximum possible extent, and the manometer reading was recorded. Three such attempts were made by the patient and each reading was noted. A reading above 160mmHg (Fig. 5b) in one or more attempts was considered "good" grip strength.

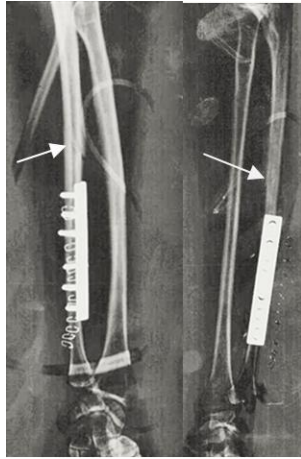


Fig. 1

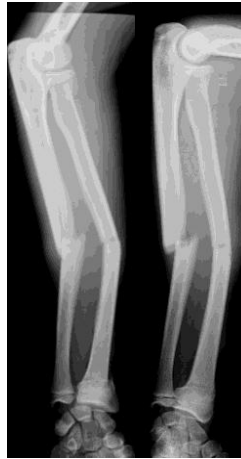

Fig. 2a

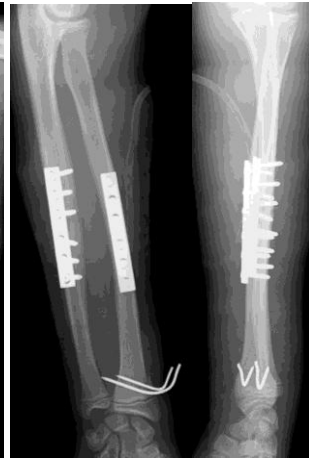

Fig. 2b

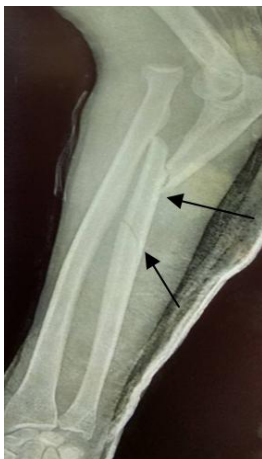

Fig. 3a

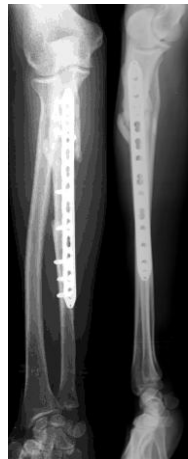

Fig. 3b

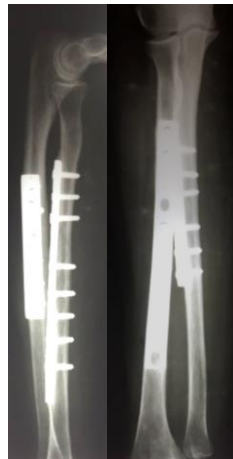

Fig. 4

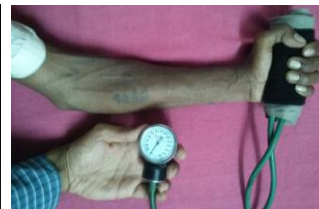

Fig. 5a

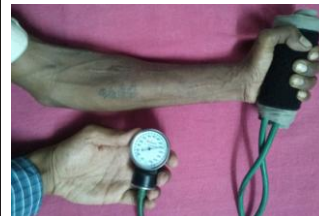

Fig. 5b

### III. Results

The mean time to achieve union (Fig. 6) in our patients was 27.6 weeks. In one patient, who underwent nailing for compound fracture of both bones, the union was delayed until 10 months post-operatively (Fig. 7) Full range of elbow, wrist and radioulnar joint movements were possible in all patients (Fig. 8) except one who had restriction of pronation (Fig. 9).

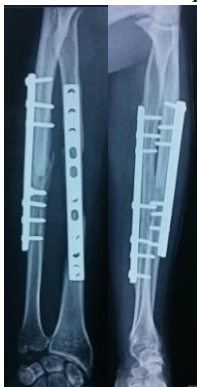

Fig. 6

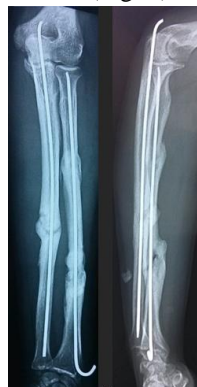

Fig. 7

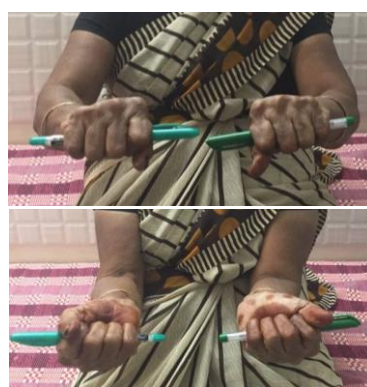

Fig. 8

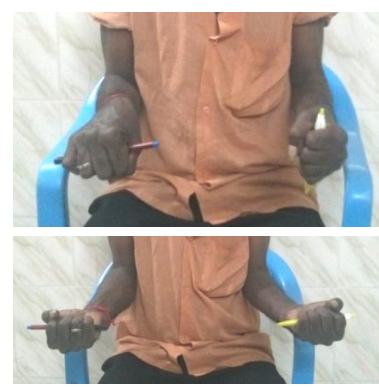


Fig. 9

The results (TABLE- 1) were analysed based on Anderson et al [2] criteria and grip strength [3].

Table- 1. Radiological and functional results

	No. of forearms	Mean union time (in weeks)	Anderson criteria	Grip strength	Complications
Plating alone	9	20.4	Excellent- 7 Satisfactory- 2	Good- 9	Nil
Plating+Nailing	2	22.4	Satisfactory- 1 Unsatisfactory-1	Good- 1 Poor- 1	Restricted pronation
Nailing alone	1	40	Excellent	Good	Delayed union

#### IV. Discussion

We started the study with the following research questions to be answered:

1. Surgical approach
2. Closed/open fixation
3. Choice of implant
4. Which bone to fix first
5. Necessity for bone grafting
6. Soft tissue closure

We have exposed all cases by volar Henry's approach for radius and direct approach for ulna. In one case, the middle segment in radius was small and had only pronator teres as soft tissue attachment. Therefore, we avoided stripping of pronator teres in order to prevent devascularisation of the middle segment. So, the plate was placed dorsally with some difficulty, even though volar Henry's approach was used. Even though there is a case report [4], where a segment of radius was completely extruded out of the forearm at the time of injury, and the same was cleaned, autoclaved and placed into the forearm, and union was achieved without complications, we feel that soft tissue attachment should be preserved as much as possible to maintain the vascularity of the fragment.

The goal of treatment according to AO principles is anatomical reduction, stable fixation, preservation of vascularity and early mobilisation. To achieve this, plate fixation is the ideal method. Moreover, radial bow can be restored better with open reduction and plate fixation. Intramedullary nailing, an attractive option in paediatric patients, cannot provide rotational stability or restore the normal radial bow, and therefore its use is not generally advocated in adults [1][5]. Some authors however recommend nailing when the skin is compromised [6].

We have used 3.5mm Asian DCP for fixing fractures in radius (except in two cases where nailing was done since both were compound fractures). We have used LCP for fixing ulna in Monteggia fracture-dislocation. Since ulna is a straight bone, contouring of plate is not necessary. The use of long LCP for radius is better avoided because LCP cannot be contoured for radial bow [7]. Nailing for ulna was done in patients with undisplaced fracture or with compound fracture.

We have fixed first, the bone with lesser comminution and lesser displacement.

Regarding the necessity for bone grafting, the opinion remains divided. Some authors believe bone grafting is necessary in comminuted fractures, whereas, others believe that preservation of vascularity (by using appropriate implant and surgical approach) obviates the need for bone grafting [1][8].

The skin over the ulna should be closed compulsorily, whereas, the skin over the radius can be left open and secondarily closed once the soft tissue tension is relieved [9].

The single paediatric patient which we have treated had fracture shaft of radius, distal radius type II epiphyseal injury and fracture shaft of ulna. The fractures of the shafts were fixed with plates and epiphyseal injury was reduced and stabilised with K-wires. A similar case with similar modality of treatment has been reported [10]. Some authors advise intramedullary nailing for paediatric fractures [11], because, implant exit, which is a must in paediatric fracture fixations, is easier with nail than with plate [12]. For plate removal, another surgical exposure should be done, and assimilation of plate by cortex poses additional difficulty [10].

Literature review [1] and our study show that restriction of movements can occur, especially of pronation if radial bow is not restored.

The union time in segmental fractures of forearm is usually longer when compared to those with

unifocal diaphyseal fractures of forearm. In our study, the union time ranges from 20 weeks to 40 weeks. This delay may be due to the associated soft tissue injuries and the fracture pattern itself.

## V. Conclusion

Even though segmental fractures are associated with various problems, meticulous planning (regarding surgical approach and implant selection) and respect to the soft tissues provides ideal functional results. Anatomical reduction, rotational stability and maintenance of radial bow are better achieved by plating for a successful outcome. Nailing is to be reserved as an option in selected patients (compound injuries, soft tissue compromise, long segment and in paediatric age group). The patient should be informed regarding longer duration for union to occur.

## References

- [1] Kapoutsis, D., Ziogas, M., Lachanas, I., Gartsiodis, K., Zagas, I., & Karliaftis, K. (1997). Complex Segmental Fractures of the Radius and Ulna without Associated Dislocation or Ligamentous Injury: A Case Report. *National Boards*, 89, 44.
- [2] Compression-plate fixation of acute fractures of the diaphyses of the radius and ulna *J. Bone Joint Surg. Am.* 71:159-169, 1989. MW Chapman, JE Gordon and AG Zissimos
- [3] Hamilton, G. F., McDonald, C., & Chenier, T. C. (1992). Measurement of grip strength: validity and reliability of the sphygmomanometer and jamar grip dynamometer. *Journal of Orthopaedic & Sports Physical Therapy*, 16(5), 215-219
- [4] Kumar, P., Shrestha, D., & Bajracharya, S. (2006). Replacement of an extruded segment of radius after autoclaving and sterilising with gentamicin. *Journal of Hand Surgery (British and European Volume)*, 31(6), 616-618.
- [5] Rockwood, C. A., & Green, D. P. (1984). *Fractures in adults*. Lippincott Williams & Wilkins.
- [6] Campbell, Canale, S. T., Beaty, J. H., (2013) *Operative Orthopaedics*, Philadelphia, PA: Elsevier.
- [7] Ibrahim, M., Cwilewicz, J., Khan, O. H., & Gibbon, A. (2011). Unilateral, trifocal, diaphyseal fracture of the radius with ipsilateral mid-shaft ulna fracture in an adult: a case report. *Journal of medical case reports*, 5(1), 123.
- [8] Raval, H., Panse, J. B., Amin, P., & Pandit, J. (2015). Unilateral, Multifocal Fracture of Radial with Ipsilateral Midshaft Ulna Fracture—Two Such Unusual and Rarely Reported Cases. *Journal of Orthopaedic Case Reports Volume*, 5(3), 22-24.
- [9] Tscherne, H., & Rojczyk, M. (1984). The treatment of closed fractures with soft tissue injuries. In *Fractures with Soft Tissue Injuries* (pp. 39-45). Springer Berlin Heidelberg.
- [10] Grainger, J., Oliva, F., & Maffulli, N. (2005). Segmental Radius and Ulna Fracture with Epiphyseal Involvement. *Bull Hosp Jt Dis*, 62(3), 4.
- [11] Heidari, N., Wong, J., Shetty, S., Malaga-Shaw, O., & Barry, M. (2008). An unusual pattern of segmental forearm fracture in the immature forearm. *Injury Extra*, 39(3), 98-99.
- [12] Yung SH, Lam CY, Choi KY, et al: Percutaneous intramedullary Kirschner wiring for displaced diaphyseal forearm fractures in children. *J Bone Joint Surg Br* 1998;80:91-94