

Benign Retroperitoneal Teratoma in young adult--A case report and literature review

Dr.Abhishek Kr Singh¹, Dr.H.I Pandey², Dr.Abhay Kumar³

Department of Surgery, Tata Main Hospital, Jamshedpur

Abstract: Teratomas are the germ cell tumours which comprises of tissues from all the three germ cell layers. Primary retroperitoneal teratoma is a relatively rare tumour in adults. The primary retroperitoneal teratoma constitutes 6–11% of the retroperitoneal tumours. Sixty percent of the retroperitoneal teratomas occur in children less than 15 years. It occurs more commonly in females than males. The order of frequency for teratoma is ovary, testis, mediastinum and the retroperitoneum at last. Early diagnosis and surgery is the mainstay of treatment. We report a rare case of retroperitoneal teratoma presented to us as left parietal wall abscess. Exploratory laparotomy with tumour resection was performed. Histopathological diagnosis confirmed a benign cystic teratoma. The patient is doing well and is on regular follow up.

Keywords: Retroperitoneum, teratoma, laparotomy, mediastinum

I. Introduction

Teratomas are uncommon neoplasm's that contain derivatives of all three germ layers (ectoderm, mesoderm and endoderm). Historically, teratomas were attributed to demons, sexual misconduct and abnormal fertilization. As with teratogenic, the name derives from the Greek word teras, meaning 'monster'. Teratomas belong to a class of tumours known as non-seminomatous germ cell tumour and are typically located in gonadal region. However, extragonadal sites such as the sacrococcygeal region, mediastinum, neck, diancephalon and retroperitoneum have also been reported. Retroperitoneal teratomas often occur in infancy and childhood but are rare in adults. In this article, we describe an unusual case of a retroperitoneal teratoma in a 18-year old male patient who presented as left parietal wall abscess subsequently, underwent successful surgical resection.

II. Case Report

A 18-year old boy presented with fever on and off for last 1 month and left upper abdominal distension for 15 days. He had no weight loss, bowel or urinary complaints. Mass was aspirated at local hospital and pus like thing came out and later referred here. On examination, a large diffuse mass was palpable in the left flank extending to left of umbilicus. X-ray Abdomen shows dilated bowel loop with calcification. Ultrasound Abdomen shows large cystic lesion of 7x10cm (approx.Vol. 400 cc) with layering of its content is noted in epigastric region. Non Contrast CT abdomen reveal few dilated bowel loops with few bowel entrapment with target sign positive, descending bowel more dilated. Chest X-ray revealed no lung metastases or lymphadenopathy.

Laboratory blood investigations shows leucocytosis W.B.C 14,500 and Hb-10.5gm%. Others parameters were within normal limit. Tumour marker AFP, B-HCG and LDH were within normal values.

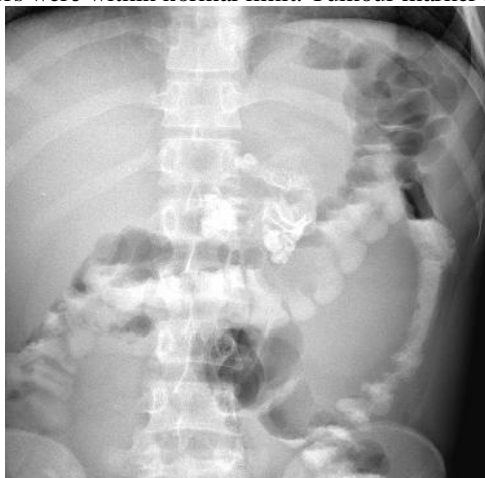

Fig.1 X-ray Abdomen shows calcification with dilated bowel the presence of calcification.

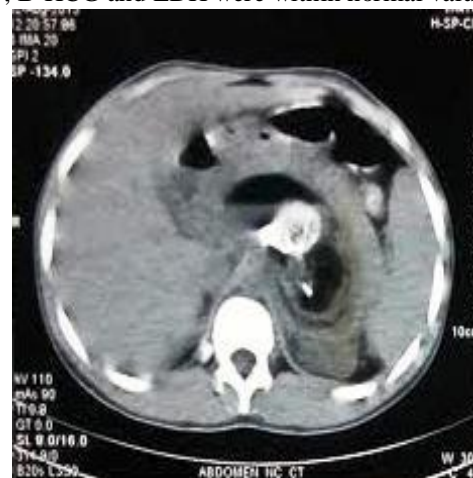

Fig 2.NCCT scan showing mass with

In view of above findings he was taken for Emergency exploratory laparotomy. Operative finding revealed large retroperitoneal dermoid tumour (?teratoma mature) with tooth (multiple) with hair and vascular pedicle, tumour and pus like collection of 700 ml. Tumour was anterior to kidney, adherent in retroperitoneal area including mesenteric vessel and adherent to aorta and renal vein and artery in close association with pancreas and portal vein, ureter separate, mesocolon involved but vessels spared. Tumour contains pus and sebum, hair and tooth with capsule. Macroscopically growth measured 8x6x4cm. Microscopically, section show squamous epithelium with intact basement membrane, underneath hair follicle and osteoid material present with areas of haemorrhage and focal chronic inflammatory exudates, few sebaceous glands. Histopathology confirmed the diagnosis of a benign cystic teratoma, benign in nature, with no malignant cells present. Postoperative course was uneventful. After 1 month, in follow up, he is fine with no recurrence or any symptoms.

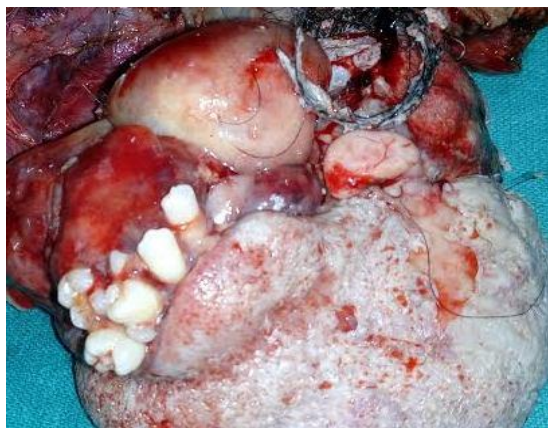

Fig 3. Gross appearance of retroperitoneal mass

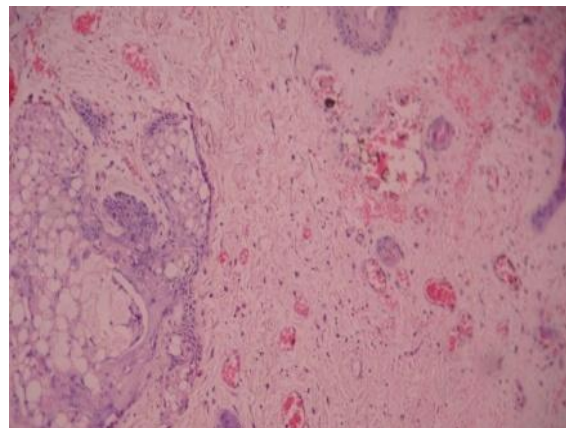


Fig.4 Microscopic examination of the tumor showing Squamous epithelium, pilosebaceous glands

III. Discussion

Overall, primary retroperitoneal teratomas constitute about 1-11% [1-3] of all primary retroperitoneal tumours. Approximately half of all teratomas found in children are discovered in first decade of life with 43-45% of retroperitoneal teratomas diagnosed within the first year of life. Less than 10-20% of retroperitoneal teratomas present in patients after 30 years of age [4].

Teratomas arise from germ cells that fail to mature normally in the gonadal locations. These totipotent cells can differentiate into tissue components representing derivatives of mesoderm, ectoderm and endoderm. The distribution of teratomas listed in order of decreasing frequency is: ovaries, testes, anterior mediastinum, retroperitoneal space, pre sacral and coccygeal areas, pineal and other intracranial sites, neck and abdominal viscera other than gonads. The developmental migratory properties of germ cells would explain teratomas in these extragonadal sites, which generally occur along midline structures [1, 5]. Retroperitoneal teratomas are usually asymptomatic except when compression of the surrounding structures occurs. Patients with compressive symptoms may present with back pain, genitourinary symptoms, gastrointestinal symptoms (abdominal distension, pain, nausea and vomiting), as well as lower extremity or genital edema secondary to lymphatic obstruction [1, 6]. The differential diagnosis of retroperitoneal teratomas include ovarian tumors, renal cysts, adrenal tumours, retroperitoneal fibromas, retroperitoneal sarcomas (usually liposarcomas), hemangiomas, xanthogranulomas, enlarged lymph nodes and perirenal abscesses [7, 8].

Testicular ultrasound is necessary to rule out testicular germ cell tumour in male patients. This is a necessary step since 50% of men with retroperitoneal tumours also have testicular carcinoma in situ, a precursor for testicular germ cell tumours [9].

Calcifications in teratomas seen within the tumour or on the rim of the cyst wall. Even though 74% of benign teratomas contain calcification, they also occur in 12.5% of malignant teratomas [10].

Ultrasound can identify the cystic, solid or complex components of the tumour [11]. The cystic portion may be further differentiated into sebum, non-fat fluid and structures resembling fetal parts. However, ultrasound has its limitations as Davidson et al found that ultrasound poorly identified fat and calcifications, which are suggestive of teratoma.

CT gives more specific information on the fat, proteinaceous fluid and calcification components of the teratoma. The presence of fatty portions of the tumour in the horizontal interface with dependent fluid, which probably represents sebum, is virtually pathognomonic of a teratoma [11, 12]. However, a fat fluid level has also

been described in case of a well differentiated liposarcoma of the retroperitoneum [13]. Second, CT appears superior to ultrasound at defining extent in to surrounding organs and for evaluating the cyst wall [11].

MRI is superior to both ultrasound and CT in defining the anatomical relationship of the teratoma with adjacent organs and local tumour spread [14, 15]. MRI can also distinguish fluid, fat, calcium and soft tissue elements, as well as predict resectability and evaluate recurrence [16].

Angiography is beneficial for detecting the presence of hypervascularity, arterial encasement and organ invasion, features often suggesting malignancy [17].

Surgical excision of benign (mature) teratoma is required for a definitive diagnosis (by histopathological examination) [18] and remains the mainstay of treatment [19]. Prognosis is fortunately excellent after complete surgical excision with an overall five-year survival rate of nearly 100% [20]. Teratomas are largely resistant to radio- and chemotherapy. Adjuvant radio- and chemotherapy are used only if malignant features of germ cell tumours are identified on histopathological examination [21].

IV. Conclusion

Teratomas can macroscopically be divided into 2 categories: cystic or solid. Cystic teratomas are mostly benign, containing sebaceous materials and mature tissue types. On the other hand, solid teratomas are often malignant and composed of immature embryonic tissues in addition to adipose, cartilaginous, fibrous and bony components. Since it does not respond to chemotherapy and radiotherapy, surgery is the mainstay of treatment. The prognosis is excellent for benign retroperitoneal teratoma if complete resection can be accomplished. Close follow-up is required, as histological mature teratoma may turn malignant.

References

- [1] Gschwend J, Burke TW, Woodward JE, et al. Retroperitoneal teratoma presenting as an abdominal-pelvic mass. *Obstet Gynecol* 1987; 70: 500-502.
- [2] Lane RH, Stephens DH, Reiman HM. Primary retroperitoneal neoplasms: CT findings in 90 cases with clinical and pathologic correlation. *Amer Jour Roentgenology* 1989; 152: 83-89.
- [3] Wang RM, Chen CA. Primary retroperitoneal teratoma. *Acta Obstet Gynecol Scand* 2000; 79: 707-708.
- [4] Panageas E. General diagnosis case of the day. Primary retroperitoneal teratoma. *AJR Am J Roentology* 1991; 156: 1292-1294
- [5] Engel RM, Elkins RC, Fletcher BD. Retroperitoneal teratoma. Review of the literature and presentation of an unusual case. *Cancer* 1968; 22: 1068-1073.
- [6] Lambrianides AL, Walker MM, Rosin RD. Primary retroperitoneal teratoma in adults. *Urology* 1987; 29: 310-312.
- [7] Pantoja E, Llobet R, Gonzalez-Flores B. Retroperitoneal teratoma: a historical review. *J Urol* 1976; 115: 520-523.
- [8] Pandya JS, Pai MV, Munchhala S. Retroperitoneal teratoma presenting as acute abdomen in an elderly person. *Ind Jou Gastroentero* 2000; 19: 89-90.
- [9] T. Gilligan, P.Kantoff. Extragonadal germ cell tumors involving the mediastinum and retroperitoneum. *UpToDate Patient Preview*, W.K. Oh, Ed., UpToDate, Waltham, Mass, USA, 2009.
- [10] Bruneton JN, Diard F, Drouillard JP, et al. Primary retroperitoneal teratoma in adults: Presentation of two cases and review of the literature. *Radiology* 1980; 134: 613-616.
- [11] Davidson AJ, Hartman DS, Goldman SM. Mature teratoma of the retroperitoneum: radiologic, pathologic, and clinical correlation. *Radiology* 1989; 172: 421-425
- [12] Billmire DF, Grosfeld JL. Teratomas in childhood: analysis of 142 cases. *J Pediatric Surg* 1986; 21: 548-551.
- [13] Smirniotopoulos JG, Chiechi MV. Teratomas, dermoids, and epidermoids of the head and neck. *Radiographics* 1995; 15: 1437-1455.
- [14] Bellin MF, Duron JJ, Curet PH, Dion-Voirin E, Grellet J. Primary retroperitoneal teratoma in the adult: correlation of the MRI features with CT and pathology. *Magn Reson Imaging* 1991; 9: 263-266.
- [15] Choi BI, Chi JG, kim SH, Chang KH, Han MC. MR imaging of retroperitoneal teratoma: correlation with CT and pathology. *J Comput Assist Tomogr* 1989; 13: 1083-1086.
- [16] Cohen MC, Weetman RM, Provisor AJ. Efficacy of magnetic resonance imaging in 139 children with tumors. *Arch Surg* 1986; 121: 522-529.
- [17] Renato F, Paolo V, Girolamo M, Vigano L, Alessandro P, Claudio V, et al. Malignant retroperitoneal teratoma: case report and literature review. *Acta Urol Belg* 1996; 64: 49-54.
- [8] P.Mathur, M.A.Lopez-Viego, andM.Howell, "Giantprimary retroperitonealteratomainanadult: acasereport,"*CaseReports inMedicine*, vol.2010, ArticleID650424, 3pages, 2010
- [9] H. Liu, W. Li, W. Yang, and Y. I, "Giant retroperitoneal teratomainanadult,"*AmericanJournalofSurgery*, vol.193, no. 6, pp.736–737, 2007.
- [10] C. W. Pinson, S. G. ReMine, W. S. Fletcher, and J. W. Braasch, "Long-term results with primary retroperitoneal tumors," *ArchivesofSurgery*, vol.124, no.10, pp.1168–1173, 1989
- [19] H. G. Gatcombe, V. Assikis, D. Kooby, and P. A. S. Johnstone, "Primaryretroperitonealteratomas: areviewof theliterature," *JournalofSurgicalOncology*, vol.86, no.2, pp.107–113, 2004.