

Foreign Body Reaction to a Plastic Pin-like Object in the Chin – A Case Report

Dler A. Khursheed¹, Didar S. Hama Gharib², Hawzhen M. Mohammed Saeed²,
Ranjdar M. Talabani²

¹(Department of Periodontics, School of Dentistry/ University of Sulaimani, Iraq)

²(Department of Conservative, School of Dentistry/ University of Sulaimani, Iraq)

I. Introduction

Foreign bodies may be endogenous or exogenous and provoke chronic inflammation of the foreignbody type. The reaction provides a mechanism for elimination of the foreign body and the reaction pattern depends on the kind of tissue involved (1).The foreign body granuloma is a response of biological tissue to any foreign material in the tissue (2).Detection of retained foreign bodies can be extremely difficult when the patients present with non-specific symptoms such as pain and/or swelling without recognizing a previous trauma (3) and granuloma is a tumor-like mass or nodule of granulation tissue, with actively growing fibroblasts and capillary buds, consisting of a collection of modified macrophages resembling epithelial cells, surrounded by a rim of mononuclear cells, chiefly lymphocytes, and sometimes a center of giant multinucleate cells; it is due to a chronic inflammatory process associated with infectious disease or invasion by a foreign body (4).

II. History, Clinical And Histological Examinations

Forty-five years old female attended dental clinic complaining with pain in the left side of the chin with two years of duration. A small scar was barely noticeable on the chin **Fig. 1**. She mentioned that a piece of a wood from a tree stabbed into her chin, from that time the pain started. She also said that she took out the wood piece from her chin immediately. On clinical examination, the upper jaw is edentulous, excluding any trauma from the upper teeth. A few teeth were present in the lower jaw, quite apart from the area of the lesion; this would exclude the dental origin of the lesion. In addition to that, she did not wear partial denture to exclude the trauma from the lower prosthesis too. Grossly, the lesion was 7 mm long and 3 mm wide. The margin of the lesion was tough with a hole of 5-6 mm depth in the center, measure by a graduated periodontal probe **Fig. 2**. Orthopantomograph view of the lesion showed neither bone lesion nor foreign body at the area of the trauma. She had no any history of medical diseases. The consent form for both diagnostic and excisional surgical procedures was signed by the patient.

Diagnostic surgical procedure: multiple local anesthetic infiltration injections were given a few millimeters around the lesion, preventing deterioration of the lesion shape. A few millimeters of the lesion with intact mucosa were excised and kept in 10% of formaldehyde solution then sent for histopathological investigation.

Therapeutic (excisional biopsy) surgical procedure: like former diagnostic surgical procedure, multiple local infiltrations were injecting around the lesion. After anesthesia was established, by using No. 15 blade, an excision around the lesion was made. The excision made deeply based upon the clinical examination that showed the lesion was about 5 mm deep. The wound was sutured interruptedly and tightly in order to close the wound margin for purpose of healing by primary intention. Then the excised tissue kept in the 10% formaldehyde solution for histopathological investigation.

III. Results

At the end stage of the surgical excision, the plastic like material was seen and carefully removed and cleaned to be recognized. The histopathology for both specimens showed chronic inflammatory giant cell reaction. polymorphonuclear cells and foreign body-type multinuclear giant cells and with a granulomatous inflammatory center were seen in the tissue. New blood vessels and lymphoplasmacytic infiltrates consistent with granulation tissue associated with an underlying foreign body granulomatous reaction. The fibrous tissue around the lesion was clearly noticeable.

The patient would not report any pain and swelling after six months of following. No sign of recurrence lesion was seen on clinical examination.

IV. Discussion

Foreign bodies may be endogenous or exogenous and provoke chronic inflammation of the foreignbody type. The reaction provides a mechanism for elimination of the foreign body and the reaction pattern depends on the kind of tissue involved. In soft tissues, there is cellular inflammation and fibrous encapsulation with macrophages (1).

The foreign body may be exogenous like talc, suture materials, parasites, wood, metal, silica and silicon or endogenous like hail shafts, keratin, cholesterol, urates, which are immunologically inert. The foreign material that implanted in the area was hair comb tooth-like material. This object was not like that that the patient reported during history taking.

On histopathological examination, the lesion showed typical chronic foreign body inflammatory reaction. No malignant cells were seen in the biopsy and after long-term follow up no any inflammatory reaction was seen, therefore no further investigation was established for.

V. Conclusion

The diagnosis was foreign body like inflammatory lesion. The cause of the lesion was a piece of hair comb tooth-like object.

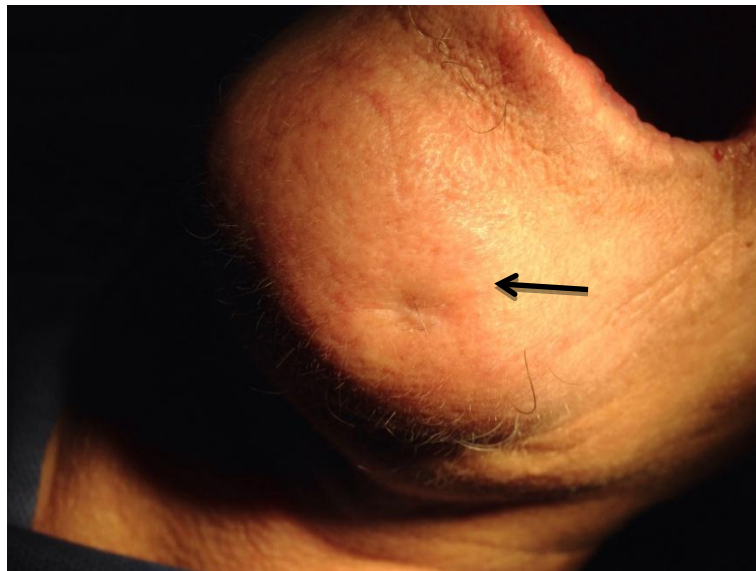

Figure 1: the scar on the left side of chin

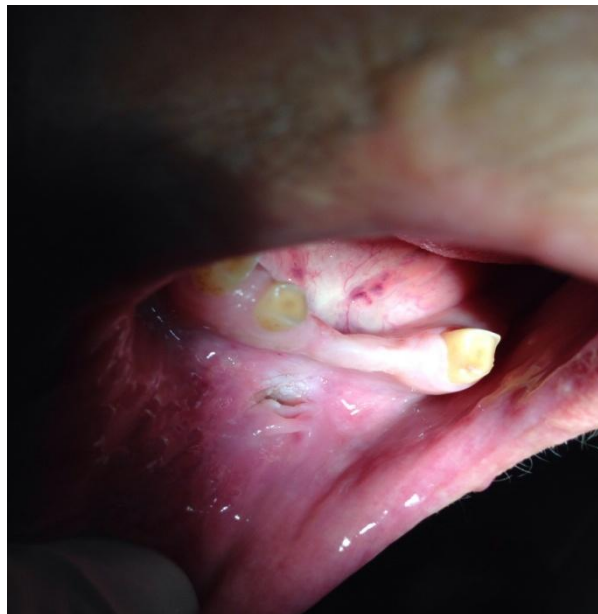

Figure 2: the lesion in the vestibule of the chin

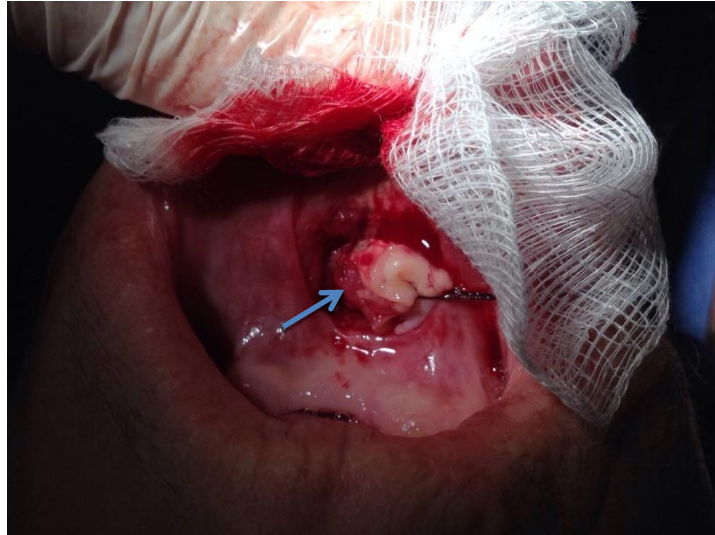


Figure 3: excision of the lesion and the arrow pointed the plastic object

References

- [1]. Donath, Karl, Monika Laaß, and Hans-Joachim Günzl. "The histopathology of different foreign-body reactions in oral soft tissue and bone tissue." *VirchowsArchivA* 420, no. 2 (1992): 131-137.
- [2]. Rapini, Ronald P., Jean L. Bologna, and Joseph L. Jorizzo. *Dermatology: 2-Volume Set*. St. Louis: Mosby. ISBN 1-4160-2999-0, 2007.
- [3]. Ando, Akira, Masahito Hatori, Yoshihiro Hagiwara, Shuji Isefuku, and Eiji Itoi. "Imaging features of foreign body granuloma in the lower extremities mimicking a soft tissue neoplasm." *Upsala journal of medical sciences* 114, no. 1 (2009): 46-51.
- [4]. Farlex, I. N. C. "The free dictionary." Retrieved June 28 (2009): 2012.