

Role Of Emergency ERCP in the Management of Biliary Sepsis Acute Cholangitis and Acute Pancreatitis related to Gall Stone Disease. Case reports and review of literature.

¹Dr M.G.Jayan, ²Dr Vergis Paul

¹Associate Professor of Gastroenterology M.O.S.C Medical CollegeKolencheryErnakulam Kerala. 682311

²Professor of SurgeryM.O.S.C Medical CollegeKolencheryErnakulam Kerala. 682311

Abstract

Introduction:We wish to present 5 cases of gall stone induced biliary sepsis/pancreatitis. These patients presented to our hospital in the emergency department either with abdominal pain, fever or shock. Emergency ERCP was successfully performed in 3 patients while two patients improved spontaneously.

Methods:Of the 5 patients 3 were female with age between 35 to 76 years, while male patients were aged between 55 to 70 years. After admission all routine investigations were done. Of the 5 patients 3 were admitted to the ICUs. Remaining 2 patients were managed in the wards.

Results:Emergency ERCP was performed for 3 patients. ERCP was not done in 2 patients as there was spontaneous passage of stone. All the five patients had a successful recovery.

Conclusion:Acute cholangitis and/or pancreatitis secondary to bile duct stones is a potentially life threatening condition. It needs to be treated on a war footing by performing emergency ERCP after carefully selecting cases which may benefit from the same.

Key words:Gall stones, Cholangitis, ERCP, Pancreatitis, Pre-cut Sphincterotomy

I. Introduction

Cholesterol cholelithiasis is one of the most prevalent and costly digestive diseases in Western countries. At least 20 million Americans ($\approx 12\%$ of adults) have gallstones. (1)

The prevalence of gallstone disease varies in different parts of India. (2)

Although many gallstones are "silent," about one third eventually cause symptoms and complications. The complications include pain, cholangitis, pancreatitis and jaundice due to stone in the bile duct. (1)

Methods

We would like to present the data on 5 patients who presented to our emergency department with various complications in the last one year.

Of the 5 patients 3 patients were female and 2 were males. Of the 3 female patients youngest was 38 years and the oldest was 76 years. The males were aged between 55 and 60 years.

II. The clinical presentation was as follows

As noted in table 1 four patients had jaundice. Fever and right upper quadrant pain was seen in almost all patients. Three of five patients had hypotension at the time of diagnosis which required emergency ERCP. None of the patients had altered sensorium at presentation. The oldest patient had pneumonia which resolved (fig 1 and fig 2). An emergency CT abdomen was done for this patient which was suggestive of large CBD stone with intrahepatic biliary radical dilation (IHBRD)(fig 3). This patient had severe hypotension the next day with respiratory distress, for which an emergency ERCP was done.

4 of 5 patients had elevated cell counts at admission with predominant neutrophilic leucocytosis. Except one patient, all others had features of gall stone pancreatitis. Cholangitis was seen in all patients(table 2). As noted in table 2, most of these parameters improved after ERCP with stenting of CBD.

The imaging features are noted in table 3. It is worthy to note that 2 patients had features of biliary abscess (fig 4). The oldest patient had the largest stone and had undergone cholecystectomy 3 years ago for acute cholecystitis. At that point, patient did not have a stone in CBD.

3 of 5 patients needed ERCP on an emergency basis. The other 2 patients improved by spontaneous passage of stones and were referred for cholecystectomy to the surgery department. During ERCP thick pus was seen flowing from the ampulla and a nasobiliary drain (NBD) was placed in one patient (fig 5, 6, 7). A large stone was removed by basket in one patient (Fig 8) and fig 9 shows a dark pigment stone removed by using a biliary basket. Pre-cut access was needed in one patient (fig 10). In the patients needing ERCP, biliary stenting or NBD was used to drain the bile duct after stone removal (fig 11, 12, 13, 14). The oldest patient had a stormy

course following the procedure. Despite improvement in cholangitis, patient developed bilateral pneumonia, (fig 1 and 2) which needed ventilator support. Patient improved after few day of starting broad spectrum antibiotics.

The patients who had biliary intervention were closely followed up. NBD placed in one patient was removed after 10 days and a 7 French plastic stent was placed insitu. After cholecystectomy the stents were removed (2 patients). One of these patients had a cirrhotic liver observed at laparotomy. This patient also had a stormy course in the hospital, eventually going on to have an uneventful recovery. At the time of stent removal an occlusion cholangiogram was done and bile duct had no residual stones. The patient with large impacted CBD stone was referred for surgery and underwent bile duct exploration with stone removal.

III. Discussion:-

Cholesterol cholelithiasis is one of the most prevalent and costly digestive diseases in Western countries. The prevalence of gallstones appears to be rising due to the epidemic of obesity, associated with insulin resistance and the metabolic syndrome.(1)

The prevalence of gallstone disease varies in different parts of India. Malhotra as early as in 1966 conducted an epidemiological study in Indian Railway employees and showed that North Indians had seven times higher prevalence of gallstones compared to South Indian employees.

In northern states including Kashmir where good epidemiological studies have been performed, a very high and increasing prevalence were reported. Khuroo from Kashmir reported a prevalence of 6.12% (men 3.07% and women 9.6%) the prevalence increasing progressively to reach a peak in the sixth decade. The prevalence rate was significantly higher in multiparous women. (2)

Types of gallstones

Based on chemical composition and macroscopic appearance, gallstones are divided into 3 types: cholesterol, pigment, and rare stones.

Cholesterol stones, consist mainly of cholesterol monohydrate crystals and precipitates of amorphous calcium bilirubinate. The remaining gallstones are pigment stones that contain mostly calcium bilirubinate (black pigment stones or brown pigment stones). Rare gallstones ($\approx 0.5\%$) include calcium carbonate stones and fatty acid-calcium stones. (1)

Gallstones are classified by their location as intrahepatic, gallbladder, and within the bile duct (choledocholithiasis) stones. Intrahepatic stones are predominantly brown pigment stones. (1)

Natural history

Stones may be asymptomatic in many patients. When symptomatic, it can cause pain in the right upper quadrant, cholangitis, choledocholithiasis and present as acute cholecystitis. Choledocholithiasis can often be asymptomatic and can predispose to cholangitis and pancreatitis.

There are many complications of gall stones. Common problems include biliary colic, pancreatitis, cholecystitis, and choledocholithiasis with or without cholangitis. Unusual complications may include cholecystoenteric fistula, gallbladder perforation, gallstone ileus, Mirizzi syndrome, emphysematous cholecystitis, gangrene of gall bladder, and Bouveret's syndrome (gastro-duodenal obstruction by the stone).(2)

Imaging of biliary system

The following are the investigations used to image the bile ducts:-

Ultrasound of abdomen

CT scan

Magnetic Resonance Cholangio-Pancreatography(MRCP)

Endoscopic Ultra Sound(EUS)

Endoscopic Retrograde CholangioPancreatography(ERCP)

As of today, the best modality is endoscopic ultrasound which is an invaluable tool for evaluation of bile duct and pancreas. It is highly accurate for stones in the bile duct with many studies suggesting higher sensitivity rates than ERCP. The specificity is also very high. In cases of low to intermediate suspicion for bile duct stone EUS is a safer option. (1)

The role of ERCP in benign biliary diseases.

Cholangitis is an inflammation of the bile ducts. Inflammatory process usually begins as an extrahepatic process and easily spreads into the intrahepatic bile ducts, causing bacteremia. The mildest clinical form is ascending cholangitis, and the most severe form is acute fulminant cholangitis. "Reynolds pentad" was defined with the addition of mental confusion and septic shock, in 1959, by Reynolds and Dragan, to the clinical findings known as "Charcot triad" (fever, abdominal pain, and jaundice). Fever and abdominal pain are the most frequently observed clinical manifestations in acute cholangitis, with an incidence of each of up to 80% or more, whereas jaundice is observed in 60%–70% of cases. The incidence of Charcot's triad is reported in not more than 72%

(range, 15.4% to 72%) of patients with acute cholangitis, and Reynolds' pentad is extremely rare, reported in only 3.5%–7.7% of the patients (3)

Normally, pressure of the hepatic bile secretion is 120–150 cm H₂O and the pressure in extrahepatic bile ducts is 100–150 cm H₂O. Bile secretion occurs according to these pressure values and bile fills into the gallbladder with a pressure of 12–18 cm H₂O. Peristaltic contraction and relaxation of the sphincter of Oddi is the most important factor in the regulation of this pressure. Bile secretion from liver is inhibited if the pressure exceeds 300 cm H₂O. If the choledochal pressure exceeds 25 cm H₂O, hepatic defense mechanisms against infection become useless. (3)

Cholangitis is one of the important causes of altered sensorium in the elderly and due care must be taken not to miss the diagnosis of same.

IV. Assessing the severity of cholangitis

In the article by K Wada et al, the severity of cholangitis was said to be more if other organ systems were involved. More than 70% of the participants at the Tokyo Consensus Meeting agreed that the severity of acute cholangitis should be divided into three grades —mild (grade I), moderate (grade II), and severe (grade III). To stratify acute cholangitis into the three grades, two different criteria were necessary, and it was decided to use “onset of organ dysfunction” and “response to the initial medical treatment” as criteria for the severity assessment of acute cholangitis (4).

Mortality

This clinical picture, which used to have a 80–90% mortality in the past, has serious morbidity without treatment or with delayed treatment, and the mortality rate has decreased to only 5–15% despite interventions using endoscopic retrograde cholangiopancreatography (ERCP) and potent antibiotics. (3)

Mortality rate is reported to be between 17% and 40% in the presence of accompanying medical problems and advanced age. Mortality is decreased significantly with endoscopic drainage, performed after stabilization of the patients. (3)

Role of ERCP in cholangitis

ERCP is an important modality of treatment in choledocholithiasis with acute cholangitis. In acute cholangitis, ERCP should be done within 24 hours. The bile duct is cannulated as in diagnostic ERCP. Before injecting contrast 10 to 20 cc of bile can be aspirated and sent for culture. It is better to avoid injecting too much contrast which would further increase intrabiliary pressure facilitating cholangiovenous reflux of infected materials into the hepatic venous circulation and septicaemia. ERCP can achieve biliary decompression by sphincterotomy and stone extraction or stent placement. In critically ill patients with coagulopathy in which sphincterotomy is contraindicated, urgent biliary drainage with a nasobiliary drain or an internal stent across the sphincter and stone should be inserted. In stable patients, the extraction of the stone can be achieved within the same session. Sphincterotomy should be performed first and the stone can then be removed with a stone extraction basket or balloon. With multiple stones are present, the most distal stone should be removed first to reduce the risk of impaction. The clearance of stone extraction should then be confirmed with occlusive cholangiogram with the help of a balloon catheter. Giant stones (stone >2cm) can be fragmented by basket mechanical lithotripsy (BML), or mother and baby choledochoscopy and intraductal lithotripsy with electrohydraulic lithotripsy (EHL) or intraductal laser lithotripsy. If a stone cannot be removed, long term stenting may result in dissolution of the stone and then the stone can be removed with interval endoscopic lithotripsy. Extracorporeal shock-wave lithotripsy (ESWL) or open surgery can be considered in difficult cases. (5)

Endoscopic balloon sphincteroplasty or dilation (EBD) was introduced by Staritz et al. in 1983. It does not involve cutting of the biliary sphincter and preserves the function of the same and may be useful in patients with profound coagulopathy.

Gall stone pancreatitis

The pathogenesis of gallstone pancreatitis remains unclear. Studies have suggested that a gallstone may compress the septum between the distal biliary and pancreatic ducts, resulting in obstruction of the pancreatic duct, or it may settle in the common channel (the ampulla of Vater), resulting in reflux of bile into the pancreatic duct. (6)

The sequelae of pancreatic-duct obstruction (reflux of pancreatic and biliary secretions, pancreatic-duct hypertension, and aberrant secretion of acinar cells) result in pancreatic-duct injury, with the release of pancreatic enzymes into the glandular interstitium causing pancreatic autodigestion and triggering acute pancreatitis. In about half of all cases of acute pancreatitis are due to the passage of small stones, usually 5 mm or less in diameter (6)

V. What are the indications for ERCP in GSP(6)

It is important to confirm the presence of CBD stone prior to ERCP. This would be a definitive reason for intervention. Ongoing cholangitis, as evidenced by fever, and elevated liver enzymes will need ERCP, more so if a stone is seen in CBD.

In a study published in Gut in 2002, C K Hui et al looked at the role of biliary decompression in patients with acute cholangitis and gall bladderstones but without evidence of CBD stones. ERCP was used to detect stones in CBD. A total of 111 patients were recruited into the study. Fifty patients were randomised to receive sphincterotomy, while 61 patients received noendoscopic intervention. This study concluded that sphincterotomy in patients with acute cholangitis without CBD stones decreased the duration of acute cholangitis and reduced hospital stay.

Persistent biliary obstruction (with bilirubin more than 5 mg/dl), worsening vitals are also indications for emergency ERCP. Even in the presence of coagulopathy it is advisable to proceed for ERCP, since these parameters will only improve after pus is drained from the bile duct. In such a scenario, the treating doctor can opt for either placing a naso-biliary drain (6 or 7 French) or a 7 French biliary stent without sphincterotomy.

The clinical trials have been reviewed in six meta-analyses and systematic reviews. It was concluded that in the absence of sepsis, cholangitis and biliary stone, early ERCP (within 24 to 72 hours) is not beneficial. (6)

When the decision is made to proceed with ERCP, several clinical issues need to be addressed. Prior to ERCP, underlying coagulopathy may be corrected. Intravenous fluids should be given and a strict input and output chart is to be maintained. Antibiotics are to be started, more so when the leukocyte count is high. Quinolones and/or cephalosporins are preferred. Adequate anesthesia support will be needed. In very sick patients it is preferable to do the procedure under general anesthesia. A standard sphincterotome is preferable. In cases of difficult cannulation, a new guide wire can be used. If a stone is seen at the tip of the ampulla or the ampulla is bulging, precut sphincterotomy is a valuable technique for shortening the procedure time.

Precut sphincterotomy enables the experienced endoscopist to increase the chances of successful cannulation in cases where other methods have failed. The conditions leading to difficult or failure of cannulation include papillary stenosis, impacted calculus, anatomical variations and surgery. Precut sphincterotomy is used in 3.8- 19.2% of ERCP procedures with a success rate ranging from 75% to 99% and complication rates from 1.9% to 30%. (7)

In the case of repeated pancreatic duct cannulation, a 5 French pancreatic stent can be placed in situ and then a precut or standard sphincterotomy can be performed. A wide sphincterotomy is useful in this scenario and there should be no fear of worsening pancreatitis since it is much more likely to resolve once the stone in the bile duct is addressed properly.

Pancreatitis is the most common complication after ERCP, with frequency estimates in the range of 2 to 8% among low-risk patients, such as those with uncomplicated choledocholithiasis. (8)

Concern about exacerbating pancreatitis in patients with acute biliary pancreatitis delayed the introduction of ERCP as a therapeutic procedure until the 1980s. The trial by Neoptolemos et al. was one of the first to show that ERCP could be performed safely by an expert endoscopist in patients with acute biliary pancreatitis. (9) However, none of the randomized trials specifically assessed post-ERCP pancreatitis as a complication, probably because of the difficulty in confirming this diagnosis in patients with established acute biliary pancreatitis. (9,10,11,12,13,14,15,16).

The Hippocratic principle, "first do no harm" is at the core of the dilemma a physician treating patients with acute biliary pancreatitis faces when he or she needs to decide whether early ERCP would be of benefit. Inconsistencies in various clinical trials and meta analyses can cause confusion and they should be interpreted within the context of limitation that the diagnosis of acute cholangitis is difficult in patients with manifestations of inflammatory reaction of acute pancreatitis (4). In the setting of acute pancreatitis EUS was as sensitive (96% vs 96%) and specific (85% vs 92%) as ERCP in detecting choledocholithiasis (17). These procedures could be applied prior to ERCP provided their availability, restricting ERCP to patients with strong evidence of biliary obstruction. The likelihood of recurrent gallstone pancreatitis occurring is thought to increase as the interval between onset of gallstone pancreatitis and cholecystectomy increases (18).

VI. What is the consensus?

The consensus is that in the absence of cholangitis and biliary obstruction, performance of early ERCP (within 24 to 72 hours after admission to the hospital) does not lead to a reduction in mortality or in local or systemic complications.

In conclusion, ERCP should be performed only in those who have strong evidence of cholangitis in the setting of acute pancreatitis. Predicted severe pancreatitis should not be an indication for early ERCP per se, but only when there are indications of persistent biliary obstruction. Both MRCP and EUS are key modalities apart

from physician experience in contributing to critical decision making for better management of the patient in this life threatening scenario.

From the above discussion, it should be clear that bile duct stone can be responsible for considerable mortality and morbidity. A well thought out plan is vital as are quick instincts. By reacting at the appropriate time and using the modality of ERCP many valuable lives can be saved.

Bibliography

- [1]. David Q.H. Wang ,Nezam H. Afdhal; Gall stone disease Slesenger and Fordtran's Gastrointestinal and Liver Disease; editors Mark Feldman, Lawrence S Friedman, Lawrence J Brandt; Saunders And Elsevier: 10th edition
- [2]. CS Pitchumoni Increasing prevalence of Gallstones ; Diagnostic and therapeutic Options Medicine Update 2010 Vol. 20
- [3]. Di Kenan Buyukasik, Ahmet Burak Toros, Hasan Bektas, Aziz Ari, and Mehmet Mehdi Deniz Diagnostic and Therapeutic Value of ERCP in Acute Cholangitis Gastroenterology Volume 2013, Article ID 191729, 4 pages
- [4]. Wada K , Takada T, Kawarada Y et al; Diagnostic criteria and severity assessment of acute cholangitis: Tokyo Guidelines. J Hepatobiliary Pancreatic Surg;2007; 14: 52-58
- [5]. Dr. Moon-sing LAI Endoscopic Management of Biliary Obstruction Consultant Physician, Department of Medicine, North District Hospital MBBS, FRCP (Edin, Glasg & Lond), FHKCP, FHKAM (Medicine) Vol 14; No 11; November 2009
- [6]. Evan L. Fogel, M.D., and Stuart Sherman, M.D. ERCP for Gallstone Pancreatitis N Engl J Med 370;2 nejm.org january 9, 2014
- [7]. Sajida Qureshi, Shahriyar Ghazanfar, Fahad Tariq et al; Role of pre cut sphincterotomy in difficult biliary cannulation; Journal of Surgery Pakistan (International) 13 (1) January - March 2008
- [8]. Freeman ML, Nelson DB, Sherman S, et al. Complications of endoscopic biliary sphincterotomy. N Engl J Med 1996;335: 909-18.
- [9]. Neoptolemos JP, Carr-Locke DL, London NJ, Bailey IA, James D, Fossard DP. Controlled trial of urgent endoscopic retrograde cholangiopancreatography and endoscopic sphincterotomy versus conservative treatment for acute pancreatitis due to gallstones. Lancet 1988;2:979-83.
- [10]. Fan S-T, Lai ECS, Mok FPT, Lo CML, Zheng SS, Wong J. Early treatment of acute biliary pancreatitis by endoscopic papillotomy. N Engl J Med 1993;328:228-32.
- [11]. Nowak A, Nowakowska-Dulawa E, Marek TA, Rybicka J. Final results of the prospective, randomized, controlled study on endoscopic sphincterotomy versus conventional management in acute biliary pancreatitis. Gastroenterology 1995;108: A380. abstract.
- [12]. Folsch UR, Nitsche R, Lütke R, Hilgers RA, Creutzfeldt W. Early ERCP and papillotomy compared with conservative treatment for acute biliary pancreatitis. N Engl J Med 1997;336:237-42.
- [13]. Orfà A, Cimmino D, Ocampo C, et al. Early endoscopic intervention versus early conservative management in patients with acute gallstone pancreatitis and biliopancreatic obstruction: a randomized clinical trial. Ann Surg 2007;245:10-7.
- [14]. Zhou MQ, Li NP, Lu RD. Duodenoscopy in treatment of acute gallstone pancreatitis. Hepatobiliary Pancreat Dis Int 2002;1:608-10.
- [15]. Chen P, Hu B, Wang C, Kang Y, Jin X, Tang C. Pilot study of urgent endoscopic intervention without fluoroscopy on patients with severe acute biliary pancreatitis in the intensive care unit. Pancreas 2010;39:398-402.
- [16]. Tang Y, Xu Y, Liao G. Effect of early endoscopic treatment for patients with severe acute biliary pancreatitis. Chinese J Gen Surg 2010;19:801-4.
- [17]. Stabuc B, Drobne D, Ferkolj et al; Acute biliary pancreatitis: Detection of common bile duct stones with endoscopic ultrasound. Eur J Gastroenterol Hepatol 2008;20: 1171-1175
- [18]. C.T. Wilson, M.A de Moya. Cholecystectomy for acute gallstone pancreatitis : Early versus delayed approach. Scandinavian J of Surgery 99: 81-85,2010

Figure 1 Showing bilateral pneumonia associated with severe cholangitis

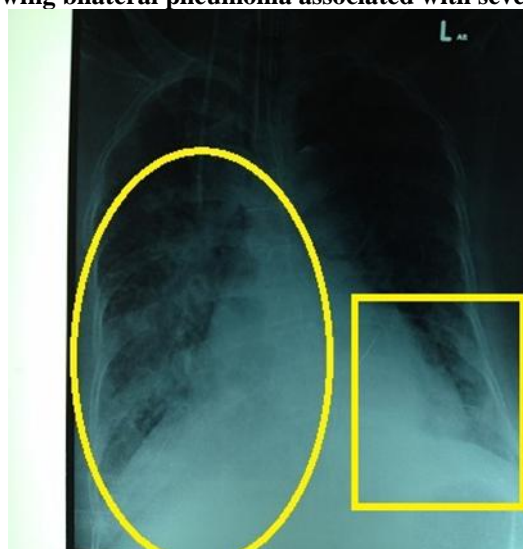


Fig 2Resolving pneumonia in the same patient

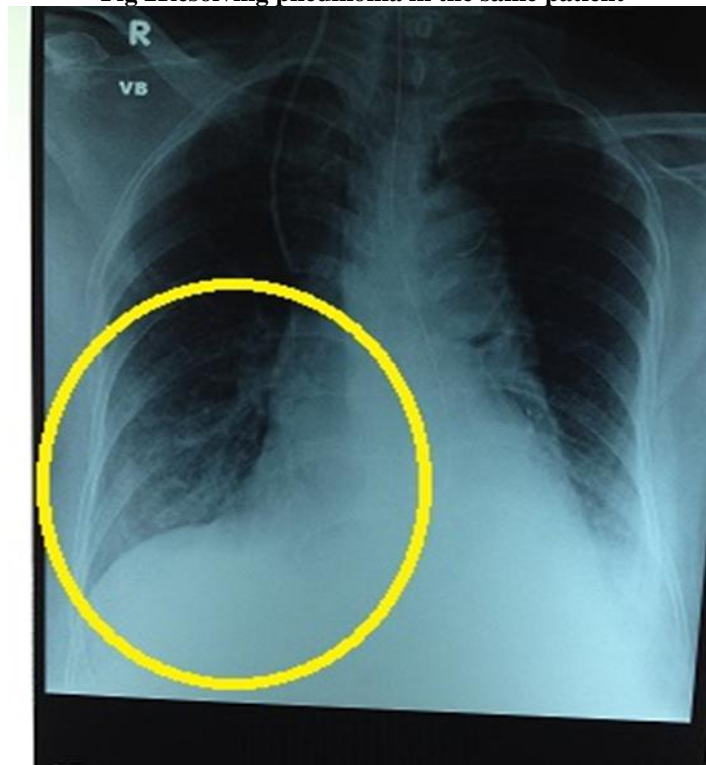


Fig 3Large stone impacted in distal CBD

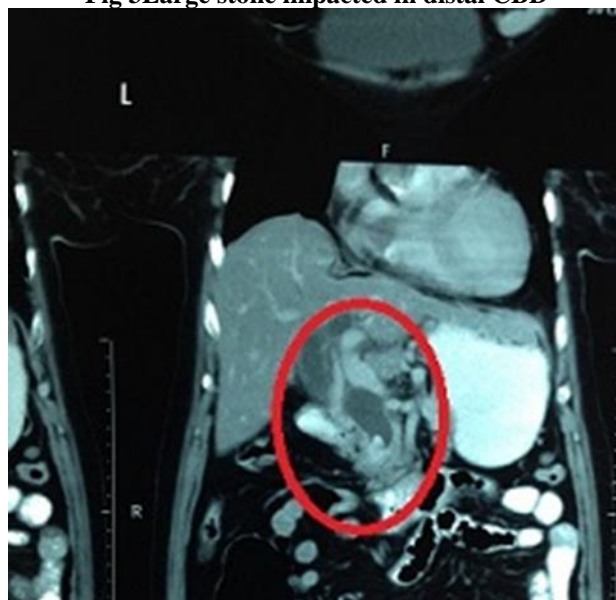


Fig 4CT showing cholangiolar abscess more in the left lobe of liver

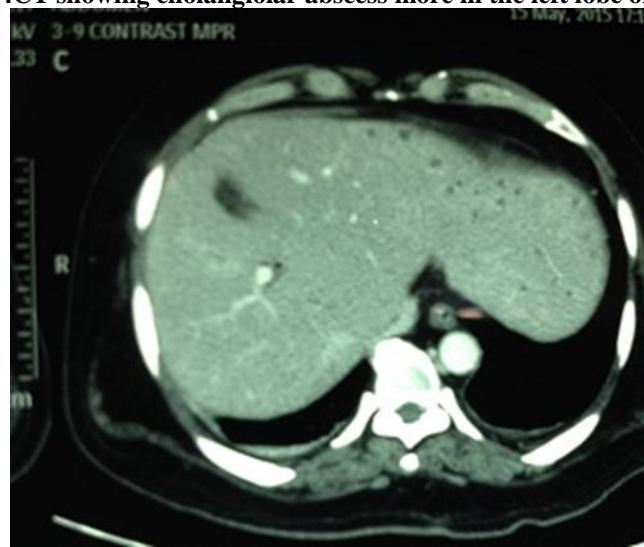

Fig 5Thick pus flowing from ampulla seen during ERCP

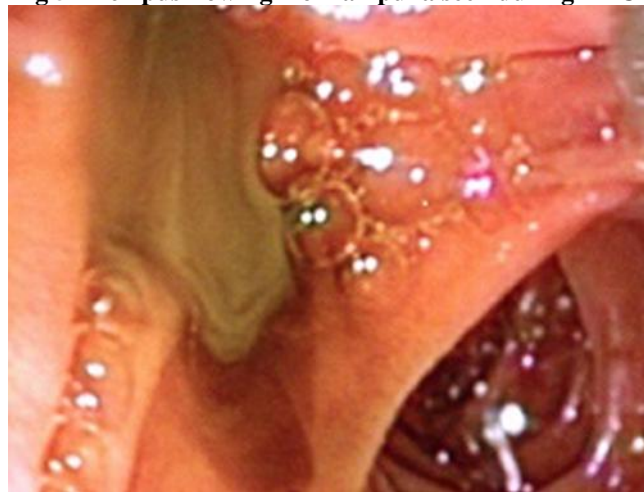

Fig 6Pus flowing from ampulla during sphincterotomy

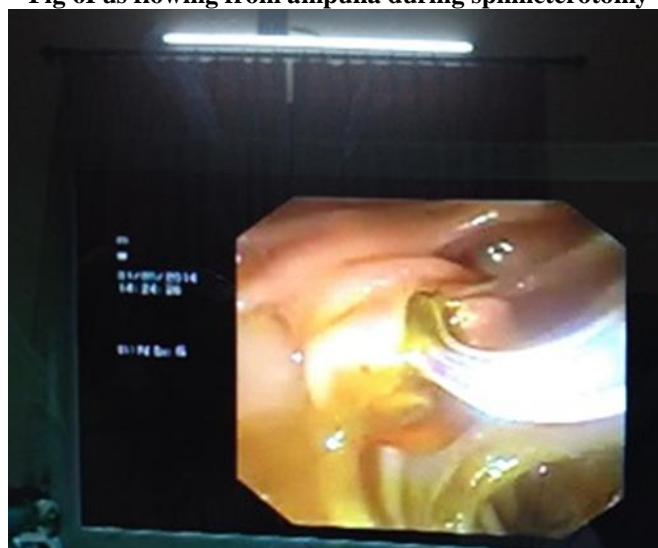

Fig 7NBD placed insitu in severe cholangitis

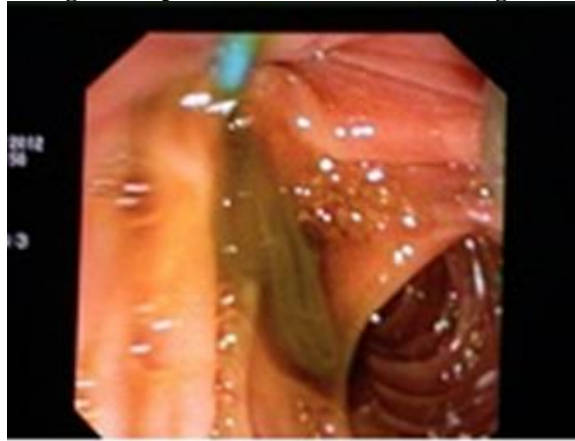

Fig 8Large stone extracted during ERCP

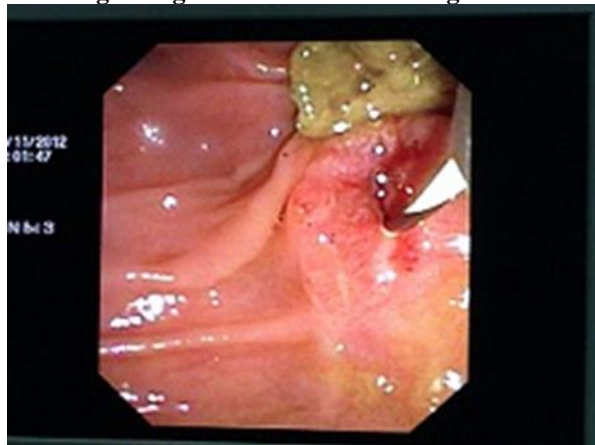


Fig 9Dark colored stone removed by basket at ERCP

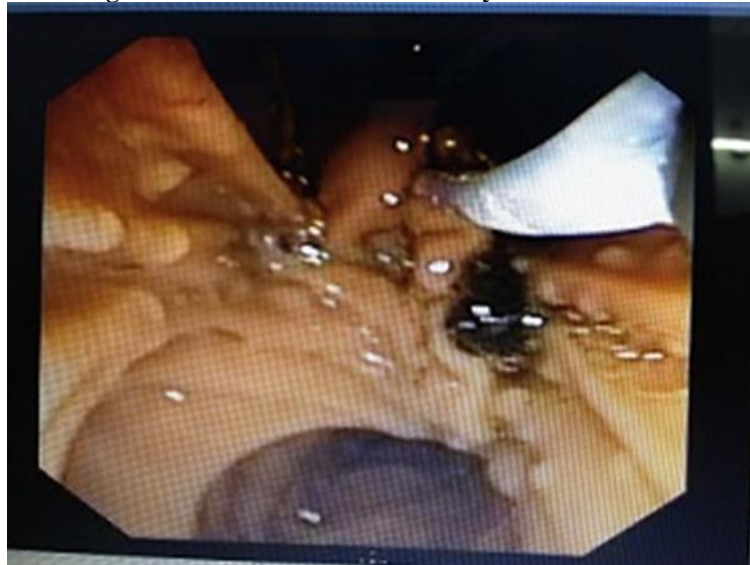

Fig 10 Precut of ampulla in an emergent situation

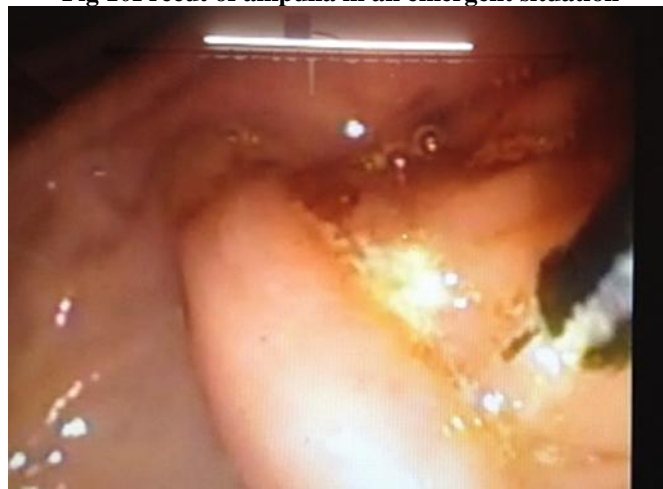

Fig 11 Large stone in CBD

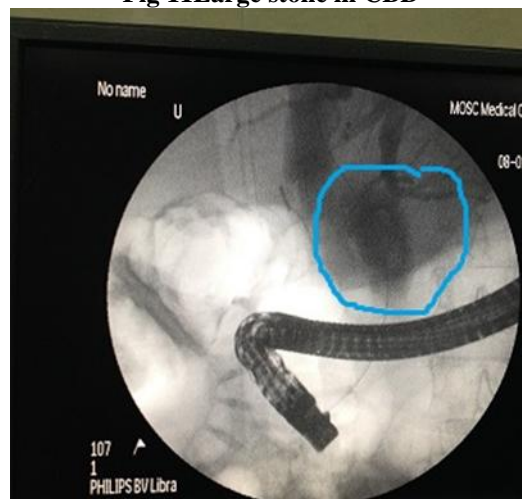


Fig 12 Large stone in CBD with cholangitis and 7 french double pigtail stent insitu

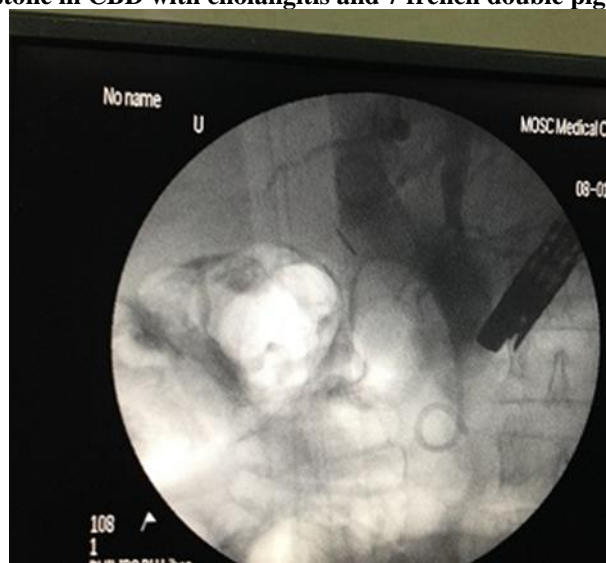

Fig 137 frenchnaso-biliary drain insitu for biliary sepsis

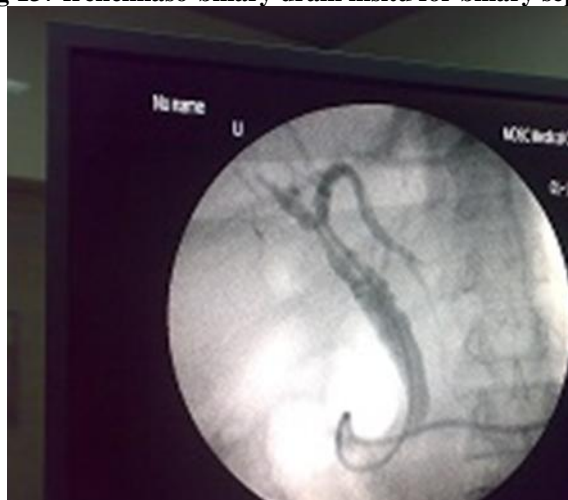

Fig 14Solitary gall stone removed using basket two months after cholecystectomy

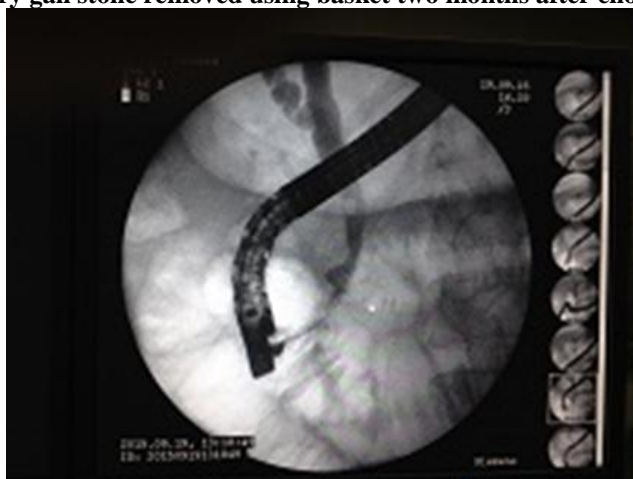

Table 1 Clinical Features At Admission

| PATIENT ID | JAUNDICE | FEVER | PAIN | HYPOTENSION | ALTERED CONSCIOUS LEVELS |
|------------|----------|-------|------|-------------|--------------------------|
| 1 | yes | yes | yes | yes | no |
| 2 | yes | yes | yes | no | no |
| 3 | yes | yes | yes | yes | no |
| 4 | yes | no | yes | no | no |
| 5 | yes | Yes | yes | yes | no |

TABLE 2 (PRE AND POST ERCP {after 48 hrs} PARAMETERS)

| Parameters And patient ID | 1 | | 2 | | 3 | | 4 | | 5 | |
|---------------------------|-------|--------------|-------|-------------|-------|--------------|-------|--------------|-------|--------------|
| | pre | post | pre | post | pre | post | pre | post | pre | post |
| Tc/dc | 12100 | 10100 | 9200 | 7500 | 32100 | 24100 | 11400 | 10000 | 20500 | 13500 |
| Total bilirubin mg/dl | 3.4 | 1.4 | 0.9 | 0.8 | 2.9 | 2 | 3.7 | 1.7 | 21.7 | 12.8 |
| SGOT U/L | 182 | 248 | 996 | 400 | 1129 | 108 | 541 | 200 | 219 | 74 |
| SGPT U/L | 255 | 177 | 682 | 200 | 622 | 176 | 498 | 198 | 101 | 58 |
| Alkaline phosphatase U/L | 139 | 111 | 96 | 85 | 184 | 210 | 224 | 157 | 213 | 263 |
| PT INR | 1.49 | 1.52 | 1.06 | 1 | 1 | 1.05 | 1.04 | 1 | 1.76 | 1.36 |
| Creatinine mg/dl | 1.8 | 1.2 | 0.7 | 0.6 | 1.1 | 3 | 1.1 | 1 | 1.3 | 1 |
| Amylase U/L | 217 | 42 | 5015 | 200 | 293 | 265 | 89 | 58 | 265 | 86 |
| Lipase U/L | 649 | 54 | 24087 | 1800 | 1123 | 780 | 148 | 100 | 658 | 714 |

Table 3 (IMAGING FINDINGS)

| PATIENT NO. | USG ABDOMEN | CT ABDOMEN | MRI ABDOMEN | EUS |
|-------------|---|--|---|---|
| 1 | Hepatomegaly ,dilated bile duct with IHBR ,ascites and altered echotexture of kidneys | CBD dilated ,biloma/abscess in the liver With moderate ascites | Not done | Not done |
| 2 | Multiple Gall Bladder stones with bulky pancreas and mildly dilated CBD | Not done | Not done | Suggestive of gall bladder stones, mildly dilated CBD, passed of stone. |
| 3 | Not done | Large calculus with a dilated CBD and IHBR | Not done | Not done |
| 4 | Cholelithiasis with features of cholecystitis | Mild intra and extrahepatic biliary dilation, no definite stone, and features of resolving cholecystitis | Suggestive of asymmetric GB wall thickening with IHBRD and dilated CBD. No definite evidence of CBD stone | Not done |
| 5 | Dilated CBD with contracted Gall Bladder | Multiple hypodense rim enhancing lesions suggestive of abscesses | Not done | Not done |

Table 4(Endoscopic procedures performed)

| ENDOSCOPIC PROCEDURES PERFORMED | 1 | 2 | 3 | 4 | 5 |
|---------------------------------|--------------|------------|--------------|----|--------------|
| STANDARD SPINCTEROTOMY | yes | no | no | no | yes |
| PRECUT | no | no | yes | no | no |
| STENTING PLASTIC | Yes 7 French | no | Yes 7 French | no | Yes 7 French |
| NBD | yes | no | no | no | no |
| BALLOON | no | no | no | no | no |
| BASKET | yes | Not needed | Not needed | no | yes |
| STENTING METAL | no | no | no | no | no |