

Primary Follicular Lymphoma of the spleen: A Case report and literature review

Dr Rajesh K, Dr Sravan Kumar K, Dr Venkateswara Rao Katta, Dr Amarendra Prasad, Dr Krishna Kishore K.

Department of General Surgery, MNR Medical College and Hospital, Sangareddy, Telangana, India.

Abstract: *Primary Splenic Lymphoma is a rare clinical entity comprising only 1% of all malignant lymphomas. Spleen is usually involved as part of multisystemic involvement of haematological malignancies, rather than isolated involvement. We report a 45 year old male patient with massive splenomegaly without any evidence of axillary or groin or abdominal lymphadenopathy. Patient had obstructive symptoms on the upper digestive system. At laparotomy, there was no mesenteric or paraaortic or periportal lymphadenopathy. The Spleen weighed about 3.5kgs and post splenectomy histopathology was in keeping with Follicular variety of Lymphoma involving spleen.*

Keywords: *Non Hodgkin's Lymphoma (NHL), Splenectomy, primary extranodal lymphomas (pENL), Primary splenic lymphomas (PSL).*

I. Introduction

The non-Hodgkin's lymphomas are a heterogeneous group of lymphoproliferative malignancies with differing patterns of behaviour and responses to treatment. NHL comprises many subtypes, each with distinct epidemiology, etiology, and morphologic, immunophenotypic, and clinical features.^{1,2} Non-Hodgkin lymphoma (NHL) originates from lymphatic hematopoietic system and can be classified as B cell lymphomas (about 90% of all NHL) and T cell lymphomas (10% of all NHL).³ Since the spleen plays a major role in the filtration of blood, primary splenic tumors are generally haematological malignancies, which are mostly lymphomas.⁴ Hodgkin and Non Hodgkin lymphomas may affect spleen as a part of systemic involvement, whereas primary splenic lymphoma is rather rare and has an incidence of less than 1%.⁵

II. Case Report

We report a 45 year old male patient, who presented to us with complaints of mass per abdomen for three years. There was no preceding trauma and was insidious in onset. The mass was palpable in the left upper abdomen just below the costal margin, initially it was measuring about 6 cms below the costal margin. The mass gradually increased over the past three years. There was no history of abdominal pain or distension, however, patient had complains of post prandial fullness and nausea. There were no history of recurrent fevers nor were any history of other swellings elsewhere in the body. There was no history of fatigue, night sweats or weight loss. Over the past one month the patient noted sensation of fullness in the central abdomen soon after oral intake with nausea. Patient reports normal bowel and bladder function. His past medical history was unremarkable apart from the fact that he completed course of anti tubercular treatment about 8 years back.

On examination the pulse rate was 74 beats/min and blood pressure was 130/80 mm Hg. There were no palpable lymph nodes in the neck, axilla or groin. Abdominal examination revealed a mass measuring 20cms X 10 cms in oblique axis arising from the left upper quadrant extending towards umbilicus, with irregular surface and firm to hard in consistency. The mass was not crossing the midline. The mass moves down with respiration. Rest of the abdominal examination was unremarkable. Patient was provisionally diagnosed as massive splenomegaly probable tropical splenomegaly with compressive symptoms on upper gastro intestinal tract for evaluation.

An ultrasound of abdomen was carried out, which was reported as massive splenomegaly with spleen measuring 25 X 15 cms and mild hepatomegaly. There were no lymph nodes identified on sonography of abdomen.

Investigations revealed Haemoglobin as 10.2 gms/dl (Normal 13.5-17.5gm/dl), Total RBC Count was 4.7 millions/cu.mm (Normal 4.5 – 6.5 millions/cu.mm), and Total WBC Count was 4,700 cells/cu.mm (Normal 4,000- 11,000 cells/cu.mm) with Neutrophils 66%, Eosinophils 02%, Basophils 00%, Lymphocytes 30%, Monocytes 02%. Platelet count was 1.4 Lakhs/cu.mm (Normal 1.5 – 4.0 Lakhs/cu.mm). ESR was slightly elevated at 18mm at the end of first hour. Smear for Malarial Parasite was negative on three occasions over a

period of a week. Rest of his investigations were unremarkable including liver function tests and Lactate Dehydrogenase. Bone marrow biopsy failed to reveal any significant abnormality.

After counselling and pre splenectomy vaccinations, the patient was posted for exploratory Laparotomy and splenectomy, during which massive splenomegaly was confirmed. Splenic hilum was free of lymphadenopathy. On further examination the small and large bowel study was unremarkable apart from the greater curvature of stomach displaced upwards and medially. There were no enlarged mesenteric or caval lymph nodes identified. However, there was a single 3cms para aortic node identified which was very vascular and in close proximity to the uncinate process of pancreas but not arising from pancreas. Biopsy of the para aortic node was done along with splenectomy.

On gross examination spleen was appearing bosselated with tubercles and hemorrhage was seen. On cut section there were uniform grey, white granular tiny nodules seen. In the sub capsular region there were few firm yellow areas seen. Histopathology was reported as sections showing multiple follicles containing monotonous nuclei and scanty cytoplasm with foci of necrosis with in the section. Similar features were also seen in the lymph node biopsy specimen. Final diagnosis was, Non Hodgkin's Lymphoma- Follicular Pattern, in both spleen and lymph node. Post operative period was uneventful and patient was discharged on 8th Post operative day and referred to oncology department for further therapy.

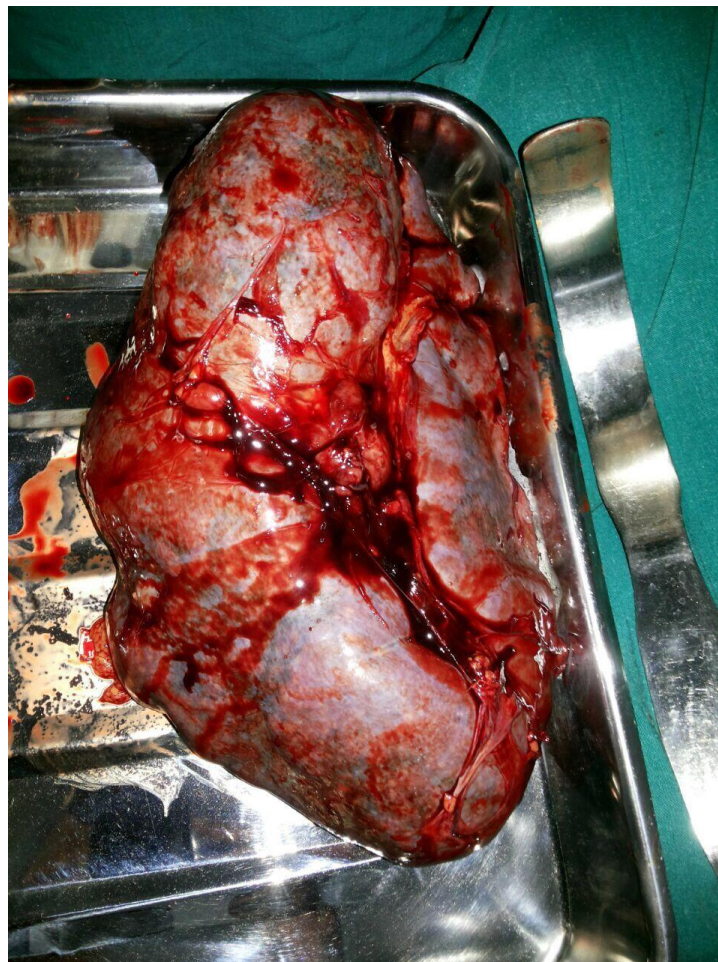


Fig: Splenectomy Specimen.

III. Discussion

A substantial percentage of non-Hodgkin's lymphomas (NHL) arise from tissues other than lymph nodes and even from sites which normally contain no lymphoid tissue. These forms are referred to as primary extranodal lymphomas (pENL). At least one-fourth of the lymphomas are probably of extranodal origin.⁶⁻⁹ The definition of extranodal lymphoma, particularly in the presence of both nodal and extranodal disease, remains a controversial issue. Different criteria primary extranodal lymphomas (pENL) have been proposed by various authors in the past.¹⁰

As per Dawson criteria, lymphoma is said to be primarily extranodal if 1) absence of palpable superficial lymph nodes on first physical examination; 2) absence of mediastinal lymphadenopathy detected on plain Chest X-ray; 3) dominant lesion at extranodal sites; 4) involvement of lymph nodes in the vicinity of the primary lesion; and 5) white blood cell (WBC) count within normal range.¹¹ Our patient presentation fits into these criteria.

It has been observed that during the last two decades the incidence of NHL has increased, and that of pENL increased more rapidly than the nodal type.¹² This trend is seen particularly in developing countries, more so in Middle East and Far East, with an increase in diffuse histological pattern over nodular, and more aggressive than indolent behaviour.^{13, 14} Primary splenic lymphomas (PSL) comprise approximately 1% of all malignant lymphomas.¹⁵ Primary splenic lymphoma has been described as 'malignancy involving only spleen and splenic hilar lymph nodes with preservation of other organ systems'. PSL is generally presented as B cell non-Hodgkin lymphoma. Secondary involvement of spleen is usually seen together with the involvement of other abdominal lymph nodes.¹⁶

Major symptoms of PSL include fatigue, weight loss, fever, left sided abdominal pain and abdominal distension secondary to splenomegaly. Other symptoms usually develop secondary to direct invasion of pancreas, stomach, diaphragm and omentum.¹⁷ Our patient had compressive symptoms on stomach for one month.

Histopathologically, malignant splenic lymphomas show four different distribution patterns: diffuse infiltration of red pulp, uniform multicentric involvement of white pulp, irregular involvement of white pulp together with secondary involvement of red pulp, early localisation in peri arteriolar lymphoid sheath and/or marginal zone.¹⁸

Patients with splenic lymphoma are divided into three groups: in group I, only spleen is involved, group II patients have splenic and hilar lymph node involvement and in group III, lymph node involvement is present beyond liver and splenic hilus.⁵

Splenectomy, chemotherapy and radiation therapy without splenectomy are treatment modalities for PSL, although there is no consensus on the latter one.¹⁰ Overall 5-year survival rate of PSL patients was reported to be 31% and 40% for those with group I and II.⁵

References

- [1]. Armitage JO, Berg AR, Purtilo DT. Adult non-Hodgkin's lymphoma. In: Bick RL, ed. *Hematology: Clinical and Laboratory Practice*. St. Louis, MO: Mosby-Year Book, Inc; 1993:875-893.
- [2]. Jaffe ES. Histopathology of the non-Hodgkin's lymphomas and Hodgkin's disease. In: Canellos GP, Lister TA, Sklar JL, eds. *The Lymphomas*. Philadelphia, PA: WB Saunders Co; 1998:77-106.
- [3]. Coiffier B., "Monoclonal antibody as therapy for malignant lymphomas", *C R Bio*, 329(4), 241-254, Apr 2006.
- [4]. Giovagnoni, A., Giorgi, C., Goteri, G., "Tumours of the spleen", *Cancer Imaging*, 5(1), 73-77, Jul 2005.
- [5]. Ahmann, D.L., Kiely, J.M., Harrison, E.G. Jr., Payne, W.S., "Malignant lymphoma of the spleen: a review of 49 cases in which the diagnosis was made at splenectomy", *Cancer*, 19(4), 461-469, Apr 1966.
- [6]. Isaacson PG, Norton AJ (Eds) (1994). *Extranodal Lymphomas*. Edinburgh: Churchill Livingstone, 1-329.
- [7]. Zucca E, Roggero E, Bertoni F, Cavalli F (1997). Primary extranodal non-Hodgkin's lymphomas. Part 1: Gastrointestinal, cutaneous and genitourinary lymphomas. *Ann Oncol*, 8, 727-37.
- [8]. Zucca E, Roggero E, Bertoni F, Conconi A, Cavalli F (1999). Primary extranodal non-Hodgkin's lymphomas. Part 2: Head and neck, central nervous system and other less common sites. *Ann Oncol*, 10, 1023-33.
- [9]. Ferry JA (2008). Extranodal Lymphoma. *Arch Pathol Lab Med*, 132, 565-78.
- [10]. Somanath Padhi, Tara Roshni Paul, Sundaram Challa, Aruna K Prayaga, Senthil Rajappa, Raghunadharao D, Rajlaxmi Sarangi. Primary Extra Nodal Non Hodgkin Lymphoma: A 5 Year Retrospective Analysis. *Asian Pacific J Cancer Prev*, 13 (10), 4889-4895.
- [11]. Dawson IP, Cornes JS, Morson BC (1961). Primary malignant lymphoid tumours of the intestinal tract. Report of 37 cases with a study of factors influencing prognosis. *Br J Surg*, 49, 80-9.
- [12]. Jemal A, Tiwari RC and Murray T. Cancer statistics (2004). *CA Cancer J Clin*, 54, 8-29.
- [13]. Yang QP, Zhang WY, Yu JB, et al (2011). Subtype distribution of lymphomas in Southwest China: Analysis of 6,382 cases using WHO classification in a single institution. *Diagnostic Pathology*, 6, 77.
- [14]. Yaqo RT, Hughson Md, Sulayvani FK, Al-Allwai NA (2011). Malignant lymphoma in Northern Iraq: A retrospective analysis of 270 cases according to the World Health Organization classification. *Ind J Cancer*, 48, 446-51.
- [15]. Morel, P., Dupriez, B., Gosselin, B., Fenaux, P., Estienne, M.H., Facon, T., Jouet J.P., Bauters, F., "Role of early splenectomy in malignant lymphomas with prominent splenic involvement (primary lymphomas of the spleen). A study of 59 cases", *Cancer*, 71(1), 207-215, Jan 1993.
- [16]. Schmid, C., Kirkham, N., Diss, T., Isaacson P.G., "Splenic marginal zone cell lymphoma", *Am J Surg Pathol*, 16(5), 455-466, May 1992.
- [17]. Dachman, A.H., Buck, J.L., Krishnan, J., Aguilera, N.S., Buetow, P.C., "Primary non-Hodgkin's splenic lymphoma", *Clin Radiol*, 53(2), 137-142, Feb 1998.
- [18]. van Krieken, J.H., Feller, A.C., te Velde, J., "The distribution of non-Hodgkin's lymphoma in the lymphoid compartments of the human spleen", *Am J Surg Pathol*, 13(9), 757-765, Sep 1989.