

Corrective Surgery for Malunited Tibial Plateau Fracture

Dr. Anand Sr¹, Dr. Bellad SH², Dr. Raghavendra MS³,

MMCRI, Mysore

¹senior Resident, ²assistant professor, ³junior Resident

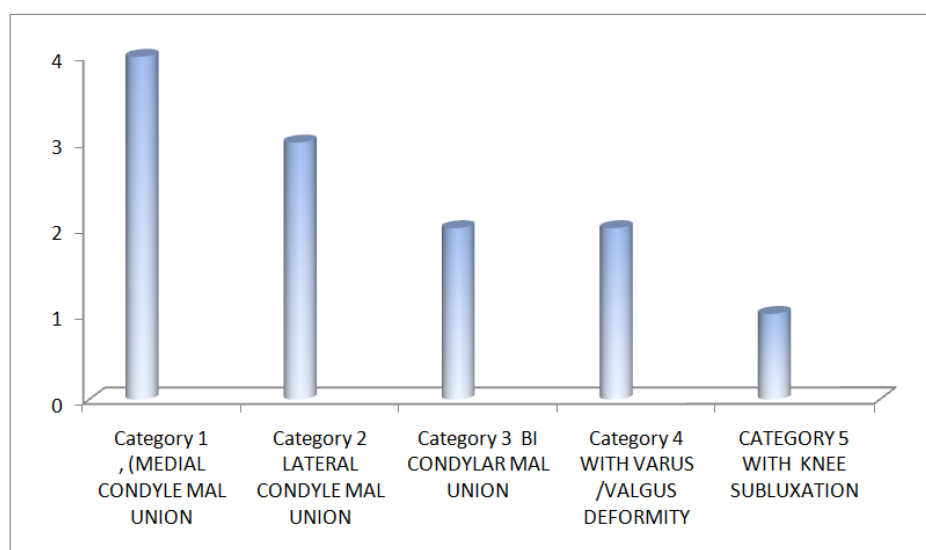
I. Introduction

Tibial plateau fractures continue to be a challenge for the orthopaedic surgeons. Restoration of normal anatomy is the goal and results are dependent on timely intervention, good surgical technique and soft tissue condition. Preventing malunion is one of the major hurdle of treating tibial plateau fractures. Joint depression, angular malunion in coronal or sagittal plane are commonly seen consequently, malunion will lead to instability and functional disability at knee joint. Prevalence of post traumatic osteoarthritis after tibial plateau fractures estimated to be 30%¹. In such cases corrective surgery is necessary to improve functional status. The surgical approach and technique will depend on the direction and amount of the deformity, the presence of preexisting implants and the condition of the soft tissue. Corrective surgery for such cases are always challenging, strategy is to restore joint congruency and enhance stability through osseous alignment². We would like to share our experience of treating such fractures in our institute

II. Materials And Methods

Patients with malunion of the intraarticular tibial plateau fracture irrespective of age and sex in adults were included in the study from 2003 -2009. We operated 12 cases (8 male and 4 female patients) during this period, with mean age of 43(range 36 - 58) . All neglected cases, cases with failed fixation going for malunion were considered for study. Time of Injury to corrective surgery was (range from 3 to 12 months) with an average 6 months, in that 60% were below 6 months. We had 4 medial condyle malunion, 3 lateral condyle malunion, 2 bicondylar Schatzker type V, VI going for mal union with one with varus, and another with valgus deformity, 1 case of mal union with subluxation of knee with ligamentous instability. Depending on the age, quality of bone and amount of displacement and depression of the malunited fragments, different surgical options like, A). Osteotomy through fracture site / reconstruction / fixation/ bone grafting. B). Extra articular open wedge osteotomy/ bone grafting. C) Reconstructing articular surface procedure were implemented⁵.

Correction of the deformity restoring mechanical axis was executed. Post operatively mobilization started after 48 hrs, and non wt bearing for 10 -12 wks advised. Patients were followed up for mean duration of 54 months (range 24 to 72months). Post operatively functional assessment of knee done using Lysholm scoring system and results were analysed



Sl no	Age/sex	category	Follow up months	Post operative functional score	remarks
1	54/m	Cat 1	66	90	-----
2	38/f	“ “	70	84	-----
3	58/m	“ “	55	88	-----
4	50/m	“ “	42	90	-----
5	40/m	Cat 2	74	86	-----
6	46/f	“ “	52	80	-----
7	47/m	“ “	70	80	-----
8	44f	Cat3	36	84	-----
9	36/f	“ “	48	78	-----
10	38/m	Cat 4	64	86	Wound healing delayed
11	40/m	“ “	46	88	
12	40/m	Cat 5	24	78	Mild persistant instability

Lysholm Knee Scale⁷

<p>Limp (5 Points) None 5 _____ Slight or periodic 3 _____ Severe and constant 0 _____</p> <p>Support (5 Points) Full Support 5 _____ Cane or crutch 3 _____ Weight Bearing impossible 0 _____</p> <p>Stair Climbing (5 points) No problems 5 _____ Slightly impaired 3 _____ One step at a time 2 _____ Unable 0 _____</p> <p>Squatting (5 Points) No problem 5 _____ Lightly impaired 3 _____ Not past 90 degrees 2 _____ Unable 0 _____</p> <p>Walking, Running and Jumping</p> <p>Instability (30 Points) Never giving way 30 _____ Rarely gives way except for athletic or other severe exertion 25 _____ Gives way frequently during athletic events or severe exertion 0 _____ Occasionally in daily activities 10 _____ Often in daily activities 5 _____ Every step 0 _____</p>	<p>Swelling (10 Points) None 10 _____ With giving way 7 _____ On severe exertion 5 _____ On ordinary exertion 2 _____ Constant 0 _____</p> <p>Pain (30 Points) None 30 _____ Inconstant and slight during severe exertion 25 _____ Marked on giving way 20 _____ Marked during severe exertion 15 _____ Marked on or after walking more than 1 ¼ miles 10 _____ Marked on or after walking less than 1 ¼ miles 5 _____ Constant and severe 0 _____</p> <p>Atrophy of thigh (5 Points) None 5 _____ 1-2 cm 3 _____ > 2 cm 0 _____</p> <p>TOTAL _____</p>
--	--

Grading the Tegner Lysholm Knee Scoring Scale

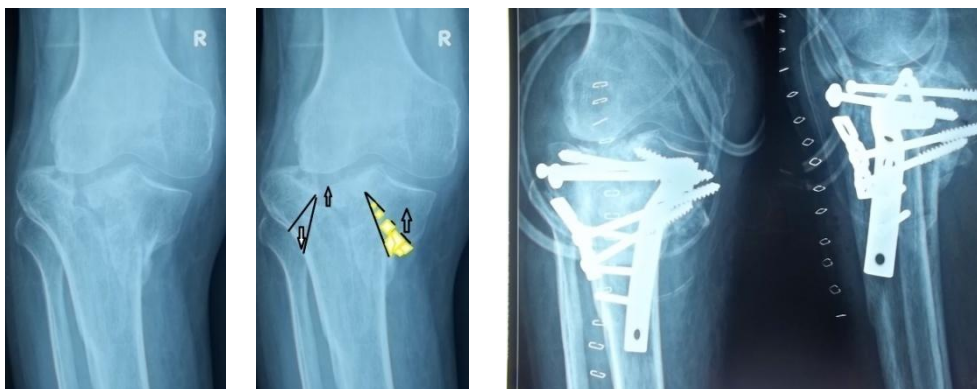<65 Poor 65-83 Fair 84-90 Good >90 Excellent

Surgical technique; ^{2,3,5,6}

Malunion medial condyle treated with osteotomy /elevation / tricortical graft from iliac crest- medial open wedge osteotomy with fixation

Lateral condyle malunion with / without valgus deformity treated with lateral open/closed wedge osteotomy with fixation, proximal fibular ostetomy/superior tibio fibular disruption.

Bicondylar malnion with extra articular deformity surgically corrected by osteotomy of proximal tibial metaphysis, cases with intra articular deformity corrected by inverted Y osteotomy/osteochondral grafts.



III. Results:

The clinical results were evaluated periodically with average 4 years (range, 2to 6 years). Tibiofemoral angle as measured pre operatively on antero posterior radiographs ranged from 20⁰ varus to 30⁰ valgus. Restoration of mechanical axis was done with mean deviation of around 3⁰. Depression of the tibial plateau as measured preoperatively ranged from 5 to 24mm on an average of 14mm. Restoration of articular surface obtained with 3mm (mean value) of depression. Ligamentous instability persisted in 2 cases, delayed wound healing noticed in one case, Post operative ROM (mean 5⁰-120⁰) achieved, mild persistant pain noticed in two cases. The comprehensively scoring assessment showed that an excellent result was achieved in 5 patients, good in 5, and fair in 2, with an excellent and good rate of 83%; according to the Lysholm and Gillquist knee joint function assessment⁷

IV. Discussion:

Malunited tibial condyle may be a result of neglected cases treated with POP cast or native treatment or inadequate reduction, early wt bearing, and collapse at fracture site. Indications for surgery are deformities of the proximal tibia in all three planes, intraarticular malunions after unicdyalar fractures, as well as residual joint impaction in combination with ligamentous instability⁵. Medial condyle fractures are more prone for malunion than lateral condyle with intra articular deformity. where as bicondylar fractures will add to an extra articular and rotational deformity. Surgical correction of such deformity will not be straight forward, cases may require dual approach and planned multiple osteotomies, so plane of osteotomy depends on the duration and site of malunion. Osteoporosis at mal united site will add to the burden of surgical correction and obtaining the stable fixation. Owing to cancellous nature of bone all cases corrected with osteotomy and elevation has to be supported with tricortical bone graft and stable fixation^{2,6}.When articular surface is lost surface reconstructing procedures are mandatory using auto or allo graft. Cases with both intra and extra articular deformity may need ring fixators for surgical correction⁵. cases with ligamentous instability are most challenging where single plane corrective osteotomy are contraindicated. Ligamentous reconstruction has to be done if significant instability persists after corrective osteotomy but the results are yet to be analysed regarding such cases. Post traumatic osteoarthritis with persistence of pain during movements commonly seen in severely depressed fractures with significant intraarticular step. Postoperative early range of movement and physical therapy, non wt bearing ambulation with functional brace for 10 to 12 wks are advised for better out come⁶.Secondary reconstruction of malunited intraarticular fracture can delay joint replacement and create a better condition for eventual replacement².

V. Conclusion:

A planned surgical correction appropriate to degree of malunion and bone quality will give excellent results and can prevent secondary arthritis, improve the joint congruency, stability, reduction of pain and restore joint mobility. We recommend this surgery in peoples of malunited fracture with high probability of success. Though procedure is technically demanding, proper plan and execution can be a definitive treatment to get good functional outcome and delay primary arthroplasty for the same in future where post traumatic arthritis is the sequelae.

References

- [1]. Combined intra-articular and varus opening wedge osteotomy for lateral depression and valgus malunion of the proximal part of the tibia. Surgical technique. [Kerkhoffs GM](#), [Rademakers MV](#), [Altena M](#), [Marti RK](#). *J Bone Joint Surg Am*. 2009 Mar 1;91 Suppl 2 Pt 1:101-15
- [2]. Proximal tibial varus osteotomy. Indications, technique, and five to twenty-one-year results. [Marti RK](#), [Verhagen RA](#), [Kerkhoffs GM](#), [Moojen TM](#). *J Bone Joint Surg Am*. 2001 Feb;83-A(2):164-70.
- [3]. Open wedge osteotomy of the proximal medial tibia for malunited tibial plateau fractures . [Harpreet Singh](#), [Vikas Rajesh Singh](#), [P Yuvarajan](#), [Lalit Maini](#), [VK Gautam](#) *Journal of Orthopaedic Surgery* 2011;19(1):57-9
- [4]. Opening-wedge osteotomy of the proximal tibia [Acta Chir Orthop Traumatol Cech](#). 2005;72(5):308-12.
- [5]. [Malunion: proximal tibia - AO Surgery Reference www.aofoundation.org/](#). by [RK Marti](#) –
- [6]. Correction of lateral tibial plateau depression and valgus malunion of the proximal tibia. [Marti RK](#), [Kerkhoffs GM](#), [Rademakers MV](#). *Oper Orthop Traumatol*. 2007 Mar;19(1):101-13
- [7]. Tegner f knee Y, Lysholm J: Rating systems in the evaluation o ligament injuries. *Clin Orthop* 198:43-49, 1985
- [8]. New procedures for tightening knee collateral ligaments in conjunction with knee realignment osteotomy. [Paley D](#), [Bhatnagar J](#), [Herzenberg JE](#), [Bhave A](#). *Orthop Clin North Am*. 1994 Jul;25(3):533-55.
- [9]. Osteotomies for Posttraumatic Deformities - Page 540 books.google.com
- [10]. René K. Marti, Ronald J. van Heerwaarden *Campbell's operative orthopaedics: Volume 3*
- [11]. *TransOsseous Osteosynthesis: Theoretical & Practical aspects of growth & regeneration of Tissue*. [Ilizarov G.A](#). Springer Verlag, Berlin 1992
- [12]. *Principles of Deformity Correction* [Paley, D](#). Springer Verlag, New York, 2002