

RBC Histogram as diagnostic tool in anemias

Dr.Jitendra Chavda¹, Dr.Parth Goswami², Dr.Alpesh Goswami³

¹ Assistant Professor, Departement of pathology, Government medical college, Bhavnagar, Gujrat, India

² Tutor, Departement of pathology, Government medical college, Bhavnagar, Gujrat, India

³ Associate Professor, Departement of pathology, Government medical college, Bhavnagar, Gujrat, India

Abstract:

Introduction: RBC histogram is routinely available almost in all counter. Histogram provides idea about morphological features of RBCs. Histogram and peripheral smear abnormal in various RBC disorders. In this article we are discussing about histogram changes in various RBC disorder and compare them with peripheral smear. **Objective:** To study RBC histogram along with peripheral smear in various RBC disorders. **Materials and Methods:** Total 500 anemic patient's blood sample collected in EDTA for peripheral smear examination and run in automated analyzer for obtaining histogram. Then abnormal histogram studied in various RBC disorders. **Results:** All 500 cases categorized into normocytic, microcytic, dimorphic, macrocytic population by smear examination. Left shifted and broad histogram mostly seen in microcytic RBC. Right shifted curve mostly in Macrocytic anemia. Bimodal peak mostly seen in dimorphic RBCs. **Conclusion:** Histogram provide hint about RBC disorder and guide in peripheral smear examination along with indices. It is powerful screening tool for RBC study. It is supplementary to peripheral smear examination for correct diagnosis of RBC disorder.

Keywords: RBC histogram, Anemia, Blood indices.

I. Introduction

RBC histogram is very useful along with other CBC parameters like RDW and MCV in diagnosis and management of various RBC disorders. It is mainly used along with peripheral smear examination for interpretation of abnormal RBC morphology.^{1,2,3,4} The Normal red cell distribution curve (Histogram) is Gaussian (bell shape) and the peak of the curve should be within the normal MCV of 80.0-100.0 fL. The red cell distribution curve will get wider as the red cell vary more in size, a narrow distribution curve indicates a homogenous population of red cells; the wider distribution curve indicates more heterogenous population of red cells.⁵

If the cells are larger than normal, the histogram curve will be more to right, as in megaloblastic anemia, if the cells are smaller than normal, the curve will be more to the left as in untreated iron deficiency anemia. After appropriate treatment of the underlying cause of an anemia, the curve should move toward the normal range.

In a dimorphic picture, the histogram may have 2 or more (multiple) red cell populations, whereas in dual populations the histogram has 2 distinct red cell populations (e.g., hypochromic-microcytic and normochromic-normocytic red cells).⁶

II. Aims And Objective

1. To study RBC Histogram (obtained by automated hematology analyzer) along with peripheral smear examination.
2. To study advantage of RBC histogram as diagnostic tool for various RBC disorders.

III. Materials And Methods

The data obtained from central laboratory, Sir T.Hospital, Bhavnagar for total 1 month during june 2015. Blood sample collected in EDTA vacuette. Cross sectional study done for 500 anemic patient. All anemic patients with hemoglobin percentage less than 12gm% will be included in the study. Hb, PCV, Blood indices, Total count, Platelet count obtained by automated hematology analyzer ABOTT CELL DYNE 3700 along with histogram. Peripheral smear examination was also done.

IV. Results And Analysis

In our study in Normocytic normochromic anemia cases show MCV, MCH and MCHC within the normal limit, with occasional cases having mildly increased RDW. In Microcytic anemia MCV, MCH, are less than normal range with normal MCHC and increased RDW due to anisopoikilocytosis. In Macrocytic anemia due to the degree of variation in size & shape of the RBCs, increase in MCV, RDW, MCH, are noted with normal MCHC. In Dimorphic anemia a MCV, MCH and MCHC were normal and increased RDW due to high

degree of anisopoikilocytosis. In Pancytopenia only change noticed in Red cell indices is an increased RDW with normal MCV, MCH and MCHC.

TABLE 1: Distribution of case as per types of anemia

Types of anemia	Percentage
Normocytic	87 cases(17.4%)
Microcytic	325 cases(65%)
Macrocytic	18 cases(3.6%)
Dimorphic	70 cases(14%)

TABLE 2 : RBC histogram in our study

Type of histogram	Percentage
Normal curve	19%
Left shift	27%
Right shift	07%
Broad base	38%
Short peak	03%
Bimodal peak	06%

This abnormal histogram show variation in different type of anemia and it will suggest particular RBC disorder which aid in diagnosis of anemia.

TABLE 3: RBC histogram in different anemia

	Normal curve	Left shift	Right shift	Broad base	Short peak	Bimodal
Normocytic	11 %			06%		
Microcytic	04%	25%		30%	02%	04%
Macrocytic			03%		01%	
Dimorphic	04%	02%	04%	02%		02%

So, analysis done in following way....

Out of total 17% cases of normocytic normochromic anemia,11% showed normal curve and 06% showed broad based curve.

Out of 65% cases of microcytic hypochromic anemia,04% were normal,25% were left shifted curve,30% showed broad based curve,02% showed short peak and 04 % showed bimodal peaked histogram. Out of total 04% cases of macrocytic anemia,03% showed right shift curve and 01% showed short peak curve histogram.

Out of total 14% cases of dimorphic anemia,04% showed normal curve,02% showed left shift curve,04%showed right shift curve,02%showed broad based curve and 02% showed bimodal curve.

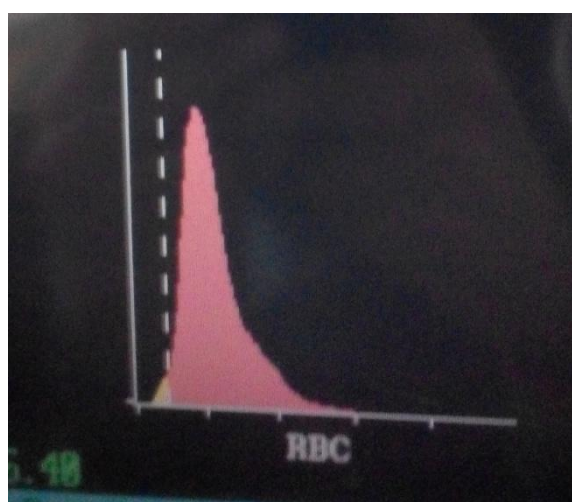


Fig. 1. Microcytic RBCs showing left shift.

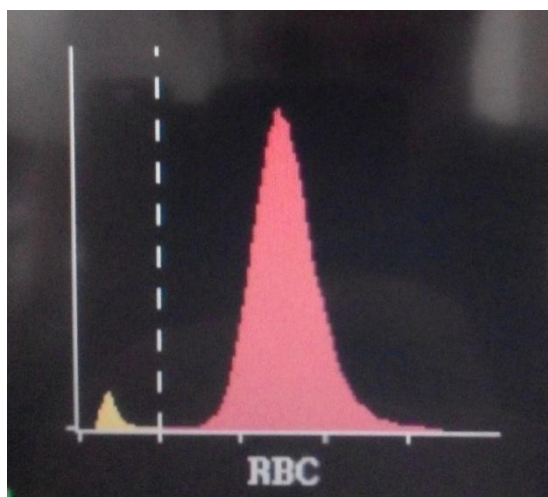


Fig. 2. Macrocytic RBCs showing right shift.

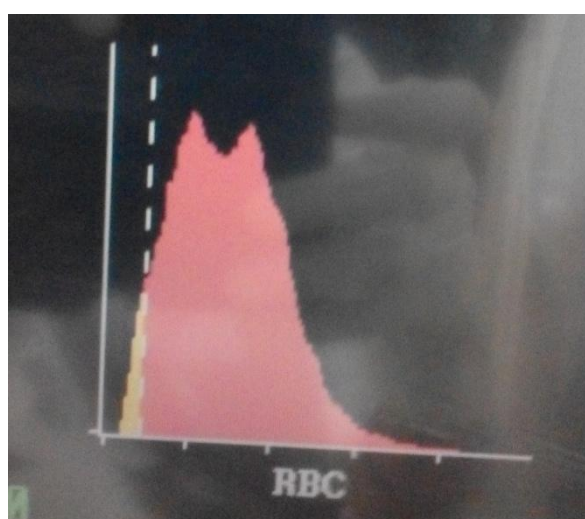


Fig. 3. Dimorphic RBCs showing bimodal curve.

V. Discussion

Histogram is graphical representations of cell frequencies versus sizes. Normally curve is symmetrical bell shaped or Gaussian distribution. Normal curve falls within normal MCV range 80-100 fl. With the help of histogram size of patient's cells can be compared with normal populations. Shift of curve in one direction is of diagnostic importance. Size (volume) is put on X axis and no. of cells per channel on Y axis. So if size of cell increase then curve shift on right side and if size decrease then curve shift on left side.^{5,7}

The cell with volume size between 36 to 360 fl counted as RBCs. Normally, below 36 fl size space is clear, but in some situation histogram begin above baseline or it will take high take off at beginning because of presence of small particles. These particles includes microspherocytes, malarial parasite, platelet clumps, normoblast, eliptocytes, bacteria, agglutinins etc.^{7,8,9,10}

WBCs presented in RBC channel and it is normally counted along with RBC. But their count is not that much of RBC (RBC count is in millions). If WBC count is much high esp. above 50,000 then RBC histogram affected.⁷

Homogenous population of RBC give narrow distribution curve while if more anisopoikilocytosis, then curve will be broad. Size of RBC affect histogram, as macrocytic RBC shift it toward right while microcytic RBC shift it toward left.

In our study, microcytic RBC show mostly left sided shifted curve because of small size along with some case showing broad base curve because of high RDW suggest anisocytosis. Most of the reason of microcytic RBC is iron deficiency anemia.^{11,12,13}

The dimorphic RBC showing bimodal curve along with some case showing left and right shifting of curve. The reason for dimorphic population may be nutritional anemia, recent blood transfusion or response of therapy to nutritional anemia or in sideroblastic anemia.^{6,14}

VI. Conclusion

Along with Blood indices and HB value, Histogram will guide regarding RBC morphology. It will guide for that which cases need actual detailed peripheral smear examination. Histogram indirectly provide idea about HB%, RBC count, MCV and of RDW.¹⁵

So as summarise Histogram is supplementary for diagnosis of various RBC disorders along with peripheral smear examination.

References

- [1]. Bessman JD, Gilmer PR Jr, Gardner FH. Improved classification of anemias by MCV and RDW. *Am J Clin Pathol.* 1983;80:322-326
- [2]. Williams LJ. Cell histograms: New trends in data interpretation and classification. *J Med Technol.* 1984;3:189-197.
- [3]. Fossat C, David M, Harle JR, et al. New parameters in erythrocyte counting. Value of histograms. *Arch Pathol Lab Med.* 1987;111:1150-1154.
- [4]. Lawrence A, Young M, Cooper A, et al. Red cell histograms in the diagnosis of diseases. In: Simpson E, ed. *Hematology Beyond the Microscope.* New York, NY: Technicon Instruments; 1984:155-164. CE Update 308 LABMEDICINE, Volume 42 Number 5; May 2011 labmedicine.com
- [5]. Interpretation of red blood cell rbc histograms. aspx .
[http://www.medialabinc.net/spg579125/interpretation of red blood cell rbc histograms.aspx](http://www.medialabinc.net/spg579125/interpretation%20of%20red%20blood%20cell%20rbc%20histograms.aspx).
- [6]. Benie T constantino. CML health care INC, Mississauga, Ontario, Canada "The red cell histogram and the dimorphic red cell population doi:10.1309 /LMF1UY85HEKBMIWO(2011) *Lab Medicine*, 42, 300-308
- [7]. Mary Louise turgeon *Clinical Haematology Theory and procedures* -4th edition page no 503-506
- [8]. Gulati GL, Hyun BH: The automated CBC.A current perspective. *Hematol Oncolcin North Am.*1994; 8; 593-603. MedlineSearch Google Scholar.
- [9]. Rowan RM. *Blood Cell Volume Analysis—A New Screening Technology for the Hematologist.* London: Albert Clark and Company; 1983:43–55. Search Google Scholar
- [10]. Bessman JD. Red blood cell fragmentation. Improved detection and identification of causes. *Am J Clin Pathol.* 1988; 90: 268–273. Medline Search Google Scholar
- [11]. Williams LJ. Cell histograms: New trends in data interpretation and classification. *J Med Technol.* 1984; 3: 189–197. Search Google Scholar
- [12]. Lawrence A, Young M, Cooper A, et al. Red cell histograms in the diagnosis of diseases. In: Simpson E, ed. *Hematology beyond the Microscope.* New York, NY: Technicon Instruments; 1984:155–164. Search Google Scholar
- [13]. Kakkar N, Makkar M. Red cell cytograms generated by an ADVIA 120 automated hematology analyzer: Characteristic patterns in common hematological conditions. *Lab Med.* 2009; 40: 549–555. Search Google Scholar
- [14]. <http://statlab.tumblr.com/post/18770587328/lab-test-cbc-histograms>
- [15]. Macrocytosis - Medscape Reference emedicine.medscape.com/article/203858-overview.