

Palatally impacted canines: factors affecting treatment duration on lateral cephalograms

MUDr. Ivana Dubovská, Ph.D.¹, MUDr. Wanda Urbanová, Ph.D.³,
MUDr. Eva Sedlatá – Jurásková, Ph.D.¹, MUDr. Přemysl Krejčí, Ph.D.¹,
Dr. Pèter Borbèly², MDDr. Iva Voborná¹, MUDr. Martin Kotas, Ph.D.¹

¹(Institute of Dentistry and Oral Sciences, Faculty of Medicine and Dentistry, Palacky University Olomouc, Czech Republic)

²(Private practice, Budapest, Hungary)

³(Department of Orthodontics and Cleft Anomalies, Dental Clinic 3rd Medical Faculty, Charles University, University Hospital Královské Vinohrady, Prague, Czech Republic)

Abstract: Aim: The aim of the study was to find out whether a relationship exists between the position of palatally impacted canines, focused on vertical position and inclination of palatally impacted upper canines on lateral cephalograms taken prior to orthodontic therapy, and the treatment duration.

Material and Method: Forty – seven palatally impacted canines were measured in 44 lateral cephalograms prior to treatment. The measured parameters were: vertical distance of the canine crown and inclination of the canine long axis to the occlusal plane on lateral cephalograms. Duration of treatment of the impacted canine was established as the time period between commencement of an active traction till the canine was aligned into the dental arch.

Conclusions: A statistically significant mild correlation was found between the canine inclination to the occlusal plane on a lateral cephalogram and treatment duration. The relationship between the canine cusp distance from the occlusal plane on a cephalogram and treatment duration was not proved.

Keywords: impacted canine, lateral cephalogram, treatment duration, canine inclination

I. Introduction

The permanent canine is an important tooth from the aesthetic and functional point of view due to its anatomical shape, size, axial position, and location in the dental arch at the border between the anterior and lateral segments of the dentition. If it is not located in an optimal position, the smile aesthetics is never satisfactory. If the tooth is missing, the high/low/high gingival margin contour is not achieved, the buccal corridors are widened, and, in the frontal view, natural tooth proportions cannot be reached [1]. Its function is canine guidance and it is also the determining tooth for lateral part torque [2]. In the natural dentition, the loss of canine guidance is substituted for by the group guidance of lateral teeth, which results in their greater load [3]. Therefore, proper canine eruption into the right position is essential from the functional and aesthetic point of view.

The maxillary canine is second only to the mandibular third molar in its frequency of impaction [4]. A timely and accurate diagnosis of this condition is important for its prevention and treatment. Primary canine extraction can help to prevent impaction [5] in stages when diagnosis is made early with the help of OPG [6], lateral cephalogram [7] or posteroanterior head film [8]. When the canine is impacted and the diagnosis is made later, it may be managed by orthodontic, orthodontic-surgical, or surgical approaches. Indeed, an early, correct and accurate diagnosis is fundamental in choosing the most appropriate and effective therapy.

The position of impacted canines is very important in terms of establishing the orthodontic treatment plan and estimating treatment duration. Pitt, Hamdan and Rock [9] concluded that the main factors affecting the treatment of impacted canines were the following: horizontal position of canine, patient's age, vertical position and bucco-palatal position of canine.

Treatment planning and decision-making are essentially influenced by radiographic and clinical diagnostic information. Traditional radiological examination of patients undergoing orthodontic treatment usually relies on a panoramic or lateral cephalometric radiograph that may be supplemented by intraoral, occlusal radiographs or CBCT.

The most common measurements used to estimate the treatment time for aligning the impacted canine are made using OPG or lateral cephalograms. On OPG, the distance of the canine cusp and inclination to the reference lines: vertical reference line [10, 11, 12, 13, 4] and occlusal plane [14], horizontal overlapping of the lateral incisor [6, 7, 12, 13, 16] and vertical position to the lateral incisor root [10, 12, 13, 15] are measured. On lateral cephalograms, the inclination and vertical position of the canine to the occlusal line [17, 18] is usually

measured. The aim of the present study was to find out whether a relationship exists between the position of palatally impacted canines, focused on vertical position and inclination of palatally impacted upper canines on lateral cephalograms taken prior to orthodontic therapy, and the treatment duration.

II. Material and Method

The study included 44 patients who successfully underwent orthodontic treatment for palatally impacted canines at the Institute of Dentistry and Oral Sciences in Olomouc. There were 12 males (27.3%) and 32 females (72.7%). The average age of the patients at the beginning of treatment was 16.5 ± 3.3 years (range 11 to 29 years). Forty-one patients had unilateral impaction and three had bilateral impaction; a total of 47 palatally impacted canines were measured.

All the patients received treatment with a fixed appliance in the upper arch, most of them in both arches. In all the patients, following the initial orthodontic alignment, an open eruption technique was performed. Individual metric parameters were measured by one examiner on lateral cephalograms made before treatment. All 47 lateral cephalometric radiographs were taken using the same equipment under the same conditions. Treatment duration was established from patient documentation. The following parameters were evaluated in each patient:

1. Treatment duration

Duration of treatment of the impacted canine was established as the period of time between commencement of an active traction till the canine was aligned and ligated at least to the .018" stainless steel wire. The accuracy of measurement was 0.5 month.

2. Vertical distance between the canine crown tip and occlusal plane (mm) on cephalogram

Vertical distance of the canine cusp from the occlusal plane (in mm) on a lateral cephalogram was measured with a method developed by Štefková and Kamínek [13]. The occlusal plane of the upper dental arch was interposed with the incisal edge of upper central incisors and the centre between mesiobuccal cusps of upper first molars. The perpendicular line went from the canine cusp to the occlusal plane (Fig. 1). The distance between the canine cusp and the occlusal plane was measured with an accuracy of 0.5 mm.

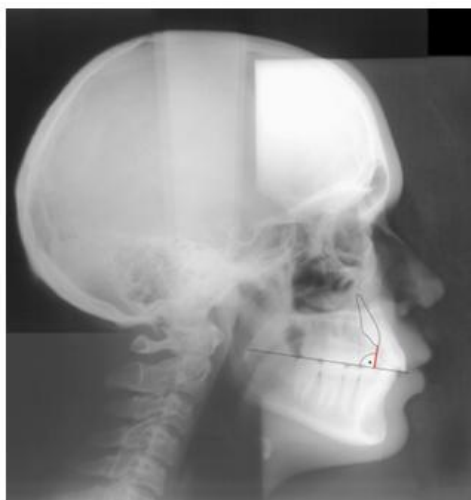

Figure 1: Vertical distance between the canine crown tip and occlusal plane on cephalogram

3. The inclination of the canine long axis to the occlusal plane on cephalogram

Inclination of the canine long axis to the occlusal plane (in degrees) on a cephalogram was measured with a method developed by Štefková and Kamínek [13] (Fig. 2). The angle between the canine and the occlusal plane of the upper dental arch was measured with an accuracy of 0.5° .

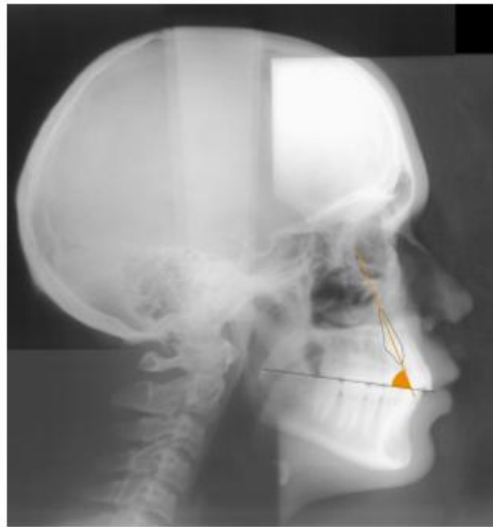


Figure 2: The inclination of the canine long axis to the occlusal plane on cephalogram

III. Statistics

The measurement error was determined using the Dahlberg's formula [9].

The measurement error established by using repeated measurements on 10 cephalograms selected randomly was 0.3° and 0.1 mm.

The degree of relationship between the duration of an active orthodontic treatment and canine position prior to orthodontic treatment found on the cephalograms was evaluated by Pearson coefficient of linear correlation and by determination coefficient.

Table 1: Position of the impacted canine before treatment on the lateral cephalogram

	Vertical distance (mm)	Inclination (°)	Treatment duration (months)
Min.	4	28	4
Max.	16	91	36
Mean	9.3	61.5	17.1
S. D.	2.4	10.4	8

A statistically significant low correlation between the canine inclination to the occlusal line on a cephalogram and the treatment duration was proved by means of the Pearson correlation coefficient ($r = -0.359$, $p = 0.013$).

The correlation between the distance of the canine cusp from the occlusal line on a cephalogram and the treatment duration was not proved (Table 2, Figs. 3 and 4).

Table 2: Correlation between treatment duration and the position of impacted canine before treatment on the cephalogram

Pearson correlation	N	coef. correl. r	p-value	sign.	coef. det. r2
Inclination	47	-0.359	0.013	**	13%
Vertical distance	47	0.196	0.186	ns	4%

*** $p < 0.001$; ** $p < 0.01$; * $p < 0.05$; ns = $p > 0.05$; Pearson correlation (r and det. R2)

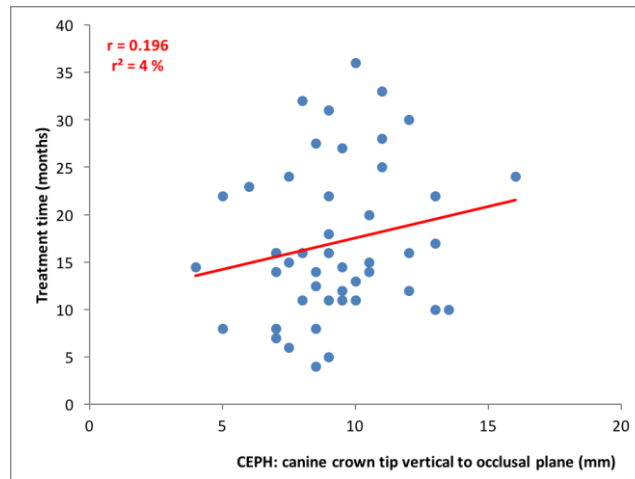


Figure 3: Correlation of vertical distance of the canine crown tip from the occlusal plane on the cephalogram with treatment duration

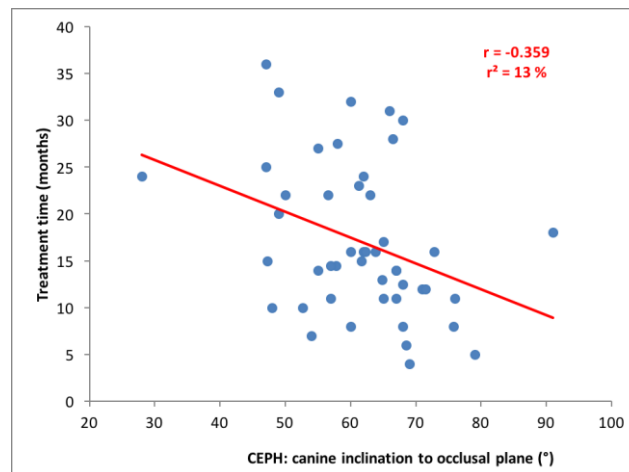


Figure 4: Correlation of inclination of the longitudinal axis of the canine to the occlusal plane on the cephalogram with treatment duration

IV. Results

The mean length of therapy of 47 impacted canines was 17.1 ± 8.0 months (the range between 4 and 36 months); median = 15 months.

The mean distance between an impacted canine and the occlusal line measured on a cephalogram made prior to treatment was 9.3 ± 2.4 mm (the range from 4 to 16 mm).

The mean inclination of the canine long axis to the occlusal plane measured on a cephalogram was $61.5^\circ \pm 10.4^\circ$ (the range between 28° and 91°) (Table 1).

V. Discussion

Treatment duration is the main concern of all orthodontic patients. However, to estimate the length of therapy for treatment of an ectopic canine with a fixed appliance is almost impossible because of large individual variation and many different influencing factors. The time needed to align the impacted canines to the dental arch in our group varied from 4 to 36 months.

In the present study, a statistically significant mild correlation was found between the canine inclination to the occlusal line measured on a cephalogram and the treatment duration. The larger the inclination of the longitudinal axis of the canine to the occlusal plane, the shorter was the alignment phase. Horizontally impacted canines required longer treatment. This can be explained by a better root position in canines with a greater inclination from the occlusal plane. It can mean that the necessity of adding additional torque may lengthen the treatment time. This phenomenon was also observed in an OPG study, wherein the torque of canines located mesially from the long axis of the lateral incisor influenced the treatment duration [19].

Vertical position of the canine was not shown to be a significant factor for treatment duration as the relationship between the distance of the canine cusp and the occlusal line on lateral cephalograms and the length

of therapy was not found. This can imply that when addressing other positional problems (inclination, torque...) an extrusion may occur [7].

As seen in our results, the determination coefficient r^2 further indicates that the canine position before the commencement of orthodontic treatment determined on the lateral cephalogram of the skull can explain only 13% (canine long axis inclination) or 4% (vertical position of the canine), respectively, of treatment duration variability. More than 80% of the variability in the length of the therapy is due to other factors. These might include the age [17], distance of the canine cusp to the occlusal plane [10, 17, 18], ankylosis, inclination to the vertical/occlusal plane on OPG [10], overlapping of the lateral incisor [10, 15], patient cooperation and many others.

The results indicate that the position of an impacted canine measured on the lateral cephalogram is not a precise indicator to estimate the treatment duration, even though the predictability of impaction and reliability of allocation of the impacted canine on the cephalograms were confirmed in other studies [7, 20]. According to the literature, it would be probably necessary to combine cephalogram findings with OPG [20], posteroanterior cephalometric radiograms [8], 3D CBCT [21] or intraoral x-rays [6] in order to estimate the length of therapy more accurately.

VI. Conclusion

1. A statistically significant mild correlation was found between the canine inclination to the occlusal line on a lateral cephalogram and treatment duration.
2. The relationship between the canine cusp distance from the occlusal line on a cephalogram and treatment duration was not proved.

References

- [1] J. D. Preston, The golden proportion revisited, *Journal of Esthetic and Restorative Dentistry*, 5(6), 1993, 247-251.
- [2] B. Zachrisson, Buccal uprighting of canines and premolars for improved smile esthetics and stability, *World Journal of Orthodontics*, 7(4), 2006, 406 – 412.
- [3] G. G. Nordquist, R.W. McNeill, Orthodontic vs. restorative treatment of the congenitally absent lateral incisor – long term periodontal and occlusal evaluation, *Journal of Periodontology*, 46(3), 1975, 139 – 143.
- [4] J. Kuroi, S. Ericson, J. O. Andreasen, The impacted maxillary canine, in: J. O. Andreasen, J. Kolsen – Petersen, D. M. Laskin (Eds.). *Textbook and color atlas of tooth impactions*, (København: Munksgaard, 1997), 125-175
- [5] S. Ericson, J. Kuroi, Early treatment of palatally erupting maxillary canines by extraction of the primary canines, *European Journal of Orthodontics*, 10(1), 1988, 283–295.
- [6] S. Ericson, J. Kuroi, Radiographic examination of ectopically erupting maxillary canines, *American Journal of Orthodontics and Dentofacial Orthopedics*, 91(6), 1987, 483-492.
- [7] P. McSherry, A. Richardson, Ectopic eruption of the maxillary canine quantified in three dimensions on cephalometric radiographs between the ages of 5 and 15 years, *European Journal of Orthodontics*, 21, 1999, 41 – 48
- [8] S. Sambataro, T. Baccetti, L. Franchi, F. Antonini, Early predictive variables for upper canine impaction as derived from posteroanterior cephalograms, *Angle Orthodontics*, 75, 2004, 28 - 34
- [9] S. Pitt, A. Hamdan, P. Rock, A treatment difficulty index for unerupted maxillary canines, *European Journal of Orthodontics*, 28(2), 2006, 141-144.
- [10] J. A. Stewart, G. Heo, K. E. Glover, P. C. Williamson, E. W. N. Lam, P. W. Major, Factors that relate to treatment duration for patients with palatally impacted maxillary canines, *American Journal of Orthodontics and Dentofacial Orthopedics*, 119(3), 2001, 216–225.
- [11] M. Leonardi, P. Armi, L. Franchi, T. Baccetti, Two interceptive approaches to palatally displaced canines: a prospective longitudinal study, *Angle Orthodontics*, 74(5), 2004, 581–586.
- [12] A. Crescini, M. Nieri, J. Buti, T. Baccetti, G. P. P. Prato, Orthodontic and periodontal outcomes of treated impacted maxillary canines. An appraisal of prognostic factors, *Angle Orthodontics*, 77(4), 2007, 571–577.
- [13] N. A. Stivaros, N. A. Mandall, M. Orth, Radiographic Factors affecting the management of impacted upper permanent canines, *Journal of Orthodontics*, 27(2), 2000, 169–173.
- [14] M. Vermette, V. Kokich, D. Kennedy, Uncovering labially impacted teeth: apically positioned flap and closed-eruption techniques, *Angle Orthodontics*, 65(1), 1995, 23–32.
- [15] P. McSherry, The assessment of and treatment options for the buried maxillary canine, *Dental Update*, 23(1), 1996, 7–10.
- [16] S. J. Lindauer, L. K. Rubenstein, W. M. Hang, R. J. Andreason-Isaacson, Canine impaction identified early with panoramic radiographs, *Journal of American Dental Association*, 123(3), 1992, 91–92, 95–97.
- [17] M. Štefková, M. Kamínek, Poloha retinovaných špičáků a doba léčení, *Československá Stomatologie*, 79(6), 1979, 424–430.
- [18] I. Dospíšilová, Treatment of impacted canines – key factors, *Ortodoncie*, 14(2), 2005, 29–39.
- [19] I. Dubovská, M. Špidlen, P. Krejčí, P. Borbély, I. Voborná, E. Harvan, M. Kotas, Palatally Impacted Canines – Factors Affecting Treatment Duration, *IOSR – JDMS*, 14(2), 2015, 16 – 21.
- [20] V. Gavel, L. Dermaut, The effect of changes in tooth position of unerupted canines on cephalograms, *European Journal of Orthodontics*, 25, 2003, 49 – 56.
- [21] A. Alqerban, R. Jacobs, S. Fieuws, G. Willems, Comparison of two cone beam computed tomographic systems versus panoramic imaging for localization of impacted maxillary canines and detection of root resorption, *European Journal of Orthodontics*, 33(1), 2011, 93 – 102.