

Management of a Case of Oesophageal Web

Dr. Habib Rahaman A A¹, Dr. Abdul Rahman Hyder²

1. Asso. Professor, Dept. Of Anaesthesia, Yenepoya Medical College

2. Consultant Gastroenterologist, Mangalore Centre of Gastroenterology

Abstract: The triad of dysphagia, upper esophageal webs, and iron deficiency anemia is known as Plummer-Vinson syndrome. Even though the syndrome is very rare nowadays, its recognition is important because it identifies a group of patients at increased risk of squamous cell carcinoma of the upper alimentary tract. This syndrome affects mostly women in their middle ages. This rare disease was relatively common in early part of 20th century. The rapid fall in prevalence of the syndrome in the latter part of the 20th century has been attributed to an improvement in nutritional status. A 27 year old lady came with History of easy fatigability which was affecting her daily activities. On enquiry she told she has difficulty in swallowing solids for the past six months. Blood Investigations revealed Iron deficiency Anaemia. Upper GI Endoscopy was done under sedation. A oesophageal web was revealed and mechanically dilated using Savary Gilliard Bougies under radiological guidance. She was sent home with Iron supplements and advised regular follow up. During subsequent visit she told her dysphagia was relieved.

Keywords: Plummer Vinson Syndrome, Dysphagia, Oesophageal web, Iron deficiency Anaemia, Upper GI Endoscopy, Savary Gilliard Bougies, Oesophageal Dilatation.

Other Names for same disease

Plummer-Vinson syndrome, PVS

Paterson-Kelly syndrome

Paterson-Brown Kelly syndrome.

Sideropenic dysphagia

I. Introduction

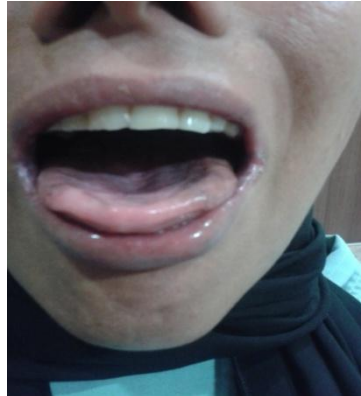Anaemia is the most common nutritional deficiency disorder in the world. Iron deficiency is the most common cause of Anaemia (1). Anaemia is associated with weakness and tiredness. These symptoms will prompt a person for medical consultation (2). When a patient with Iron deficiency anaemia complains of difficulty in swallowing, then one should suspect Plummer Vinson Syndrome and should be investigated for the presence of upper oesophageal web (3).

Upper GI endoscopy is the safe and economical way of finding the cause of dysphagia. If there is any oesophageal web the therapeutic intervention of mechanically dilating the oesophageal web can be carried out in the same setting (4). Usually dysphagia will be relieved after single dilatation. Rarely multiple dilatation are required (5). Identification of oesophageal web in these patient should prompt us to keep these patient under surveillance for squamous cell Carcinoma of the upper alimentary tract (6,7).

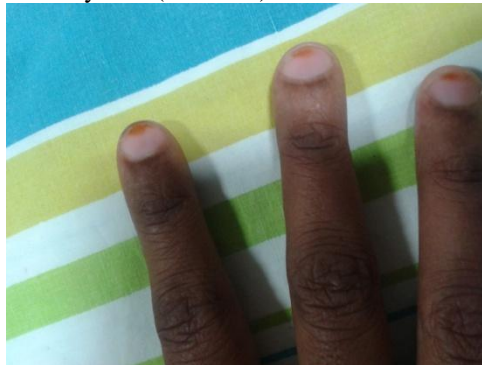II. Case report:

A 27 year old lady came with History of easy fatigability for six months. This was progressed to such a level that she was not able to do her routine activities without getting fatigued. On enquiry she told that she has difficulty in eating solids for the past six months. When she eats solids she feels the food is stuck in the throat. There was no History of weight loss. On General Physical Examination she had Glossitis and Angular Chelitis. (Picture 1)

Picture 1. Glossitis and Angular Chelitis



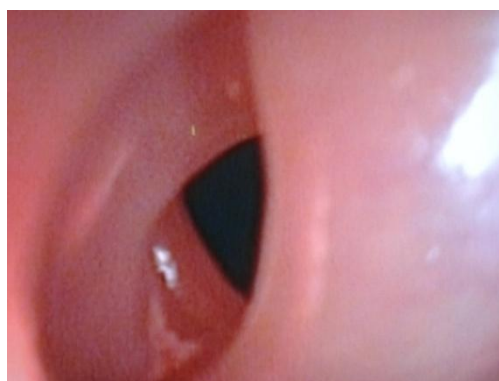Also she had Pale Nails and early Koilonychia. (Picture 2)



Picture 2. Nail changes

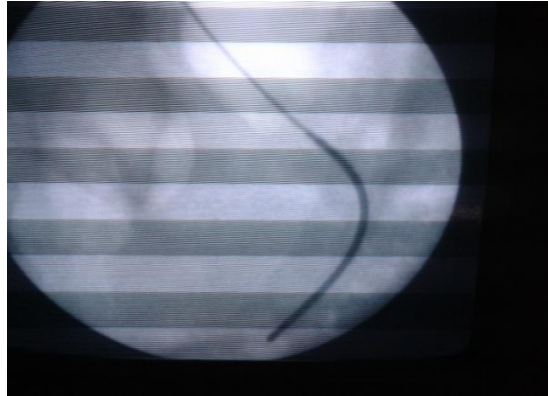
Complete Haemogram Showed Hb% of 5.2 g% and low Mean Corpuscular Volume and Low Mean Corpuscular Haemoglobin Concentration. Peripheral Smear showed Microsytic Hypochromic blood picture. Serum Ferritin and serum Iron levels were low and Total Iron Binding Capacity was Increased.

She was transfused one unit of Packed Cell and posted for Upper GI endoscopy to examine for the cause of dysphagia. Presence of oesophageal web was suspected and plan was to mechanically dilate if required. After thorough pre anaesthetic evaluation and informed consent she was kept fasting for 6 hours. She was positioned in the procedure table of endoscopy room which was C Arm Compatible. Pulse Oximeter, ECG and NIBP monitors were connected. Oxygen supplementation was given through nasal prongs. Bite block was placed. Anaesthesiologist administered sedation with Fentanyl 100 microgram, Glycopyrrolate 0.2 mg IV. Then propofol was given in titrating doses. Once the patient stopped responding to verbal commands gastroenterologist passed the Upper GI scope to visualize the upper oesophagus. A oesophageal web was noticed just below crico pharynx (Picture 3).



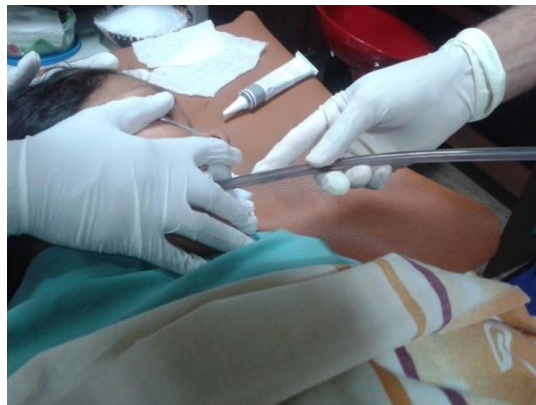Picture 3. Oesophageal web

A guidewire was passed through the endoscope. Tip of the guide wire was confirmed in the stomach radiologically using C Arm. (Picture 4). Then endoscope was removed

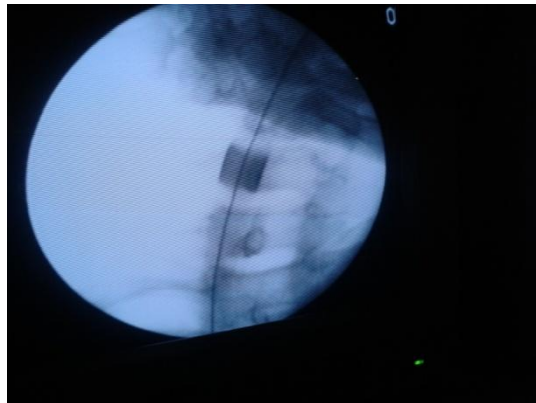


Picture 4. Tip of guide wire in stomach

This web was forcibly dilated using Savary Gilliard dilators , starting with 7 mm, then 9 mm ,11 mm ,12.8 mm ,14 and finally 15 mm Dilator, which were passed over the guide wire.(Picture 5&6).

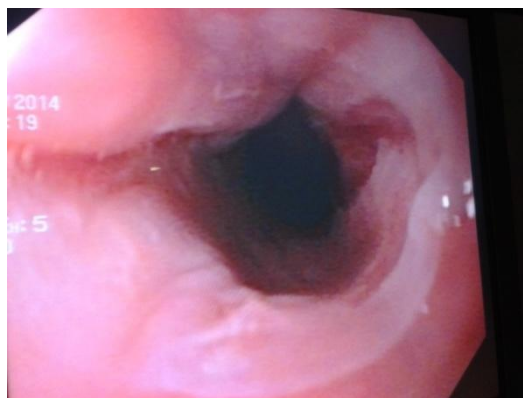


Picture 5. Dilatation with Savary Gilliard Bougies



Picture 6. Radiological image of Dilatation

Check Endoscopy was to done to check for rupture of web, Bleeding and any other complication (Picture 7)



Picture 7. Check Endoscopy after Dilatation

Patient was shifted to recovery Room. She was started on Oral diet next day and discharged on the second day with Iron supplements and she was advised regular follow up visit.

III. Discussion

Plummer-Vinson syndrome which is also known as Paterson-Kelly

Syndrome in UK or sideropenic dysphagia in Scandinavian Country is characterised by difficulty in swallowing, iron deficiency anemia and oesophageal web(8). The pathogenesis of this condition is unknown (9). The most important possible etiological factor is iron deficiency. This theory is primarily based on the finding that iron deficiency is a part of the classic triad of Plummer-Vinson syndrome together with dysphagia and oesophageal webs and that dysphagia can be improved by iron supplementation (10). Impaired oesophageal motility has been described in Plummer-Vinson syndrome and it was corrected by iron treatment (11). It has been shown that iron deficiency can precede dysphagia (11). On the other hand, the alimentary tract is susceptible to iron deficiency; it rapidly loses iron dependent enzymes due to its high cell turnover, which is speculated to cause mucosa degeneration and web formation (12).

This disease is extremely rare today. Reduction in incidence is attributed to nutritional improvement, advanced health care and fortification of flour with Iron (13).

Other etiologic factors including malnutrition, genetic predisposition or even autoimmune processes have been proposed. The latter is based on the association between Plummer-Vinson syndrome and certain autoimmune disorders such as celiac disease, thyroid disease and rheumatoid arthritis (14).

In our case her chief complaints were because of Anaemia. She had difficulty in swallowing and she was taking liquids and semisolids without much difficulty. There was no pain while swallowing. She also had angular cheilitis and brittle nails. Oesophageal web can be diagnosed radiologically by barium swallow or by direct visualization under endoscope. Cost analysis evaluations have suggested that initial endoscopy with therapeutic intent is less costly than

a barium swallow in patients with a history suggesting esophageal obstruction (15). Endoscopy is indicated in patients with dysphagia to determine the underlying etiology, exclude malignant and premalignant conditions, assess the need for therapy, and perform therapy, such as dilatation (16). Usually web is found at the level of Cricopharynx and the management includes treatment with iron supplementation (17), oesophageal dilatation (18, 19) as well as surgical correction (20). Most of the symptomatic oesophageal web improves after single oesophageal dilatation. But sometimes additional sittings of dilatation are required to improve the symptoms. Wire-guided polyvinyl dilators, Savary Gilliard bougies are used to mechanically dilate the oesophagus. Initially smaller diameter bougies are passed over the guide wire. Usually upper oesophagus is dilated upto 15 mm or 17 mm dilator. This dilatation is a safe and minor procedure which is done with Intravenous sedation in the endoscopy room.

Conclusion: Dilatation of the esophageal web and Iron supplementation relieves dysphagia in patient with Plummer Vinson syndrome. Dilatation with Savary Gilliard dilators is a safe and easy procedure done in the endoscopy room under sedation. Plummer-Vinson syndrome is known to be associated with an increased risk of upper alimentary tract cancers. So they will need regular follow up and surveillance upper gastro intestinal endoscopy every year.

References

- [1]. Thankachan PI, Muthayya S, Walczyk T, Kurpad AV, Hurrell RF An analysis of the etiology of anemia and iron deficiency in young women of low socioeconomic status in Bangalore, India. Food and Nutrition Bulletin 2007 Sep;28(3):328-36.
- [2]. World Health Organization. Iron Deficiency Anaemia: Assessment, Prevention, and Control: A Guide for Programme Managers. Geneva, Switzerland: World Health Organization; 2001.

- [3]. Hoffmann RM, Jaffe PE: Plummer-Vinson syndrome. A case report and literature review. Arch Intern Med 1995, 155:2008-111.
- [4]. Yasawy MI: Treatment of Plummer-Vinson syndrome with Savary-Gilliard dilatation. Saudi Med J 2004, 25:524-526
- [5]. Ben Gamra O, Mbarek C, Mouna C, Zribi S, Zainine R, Hariga I, El Khedim A. Plummer Vinson syndrome ; Tunis Med. 2007 May;85(5):402-4.
- [6]. Lars-Gunnar Larsson, Anita Sandstrom, and Per Westling : Relationship of Plummer-Vinson Disease to Cancer of the Upper Alimentary Tract in Sweden. CANCER RESEARCH November1975 , 35, 3308-3316.
- [7]. J. McK. Watts: The Importance of the Plummer-Vinson Syndrome in the Aetiology of Carcinoma of the Upper Gastro-Intestinal Tract. . Postgrad Med J. Sep 1961; 37(431): 523–533
- [8]. Novacek G. Plummer-Vinson syndrome. Orphanet J Rare Dis. 2006;1:36
- [9]. D Lawoyin, E Reid, F Sam, T Obayomi, A Bonnick. : Plummer Vinson Syndrome: A Case Report And Literature Review. The Internet Journal of Dental Science. 2006 Volume5 Number2
- [10]. Tomomitsu Tahara et al: A Case of Plummer-Vinson Syndrome Showing Rapid Improvement of Dysphagia and Esophageal Web after Two Weeks of Iron Therapy. Case Rep Gastroenterol. 2014 May-Aug; 8(2): 211–215
- [11]. Dantas RO, Villanova MG : Esophageal motility impairment in Plummer-Vinson syndrome. Correction by iron treatment. Dig Dis Sci. 1993 May;38(5):968-71
- [12]. Chisholm M: The association between webs, iron and post-cricoid carcinoma. Postgrad Med J 1974, 50:215-219
- [13]. Chen TS, Chen PS. Rise and fall of the Plummer-Vinson syndrome. J Gastroenterol Hepatol 1994; 9: 654-8
- [14]. Makharia GK, Nandi B, Garg PK, Tandon RK: Plummer-Vinson syndrome: unusual features. Indian J Gastroenterol 2002, 21:74-75.
- [15]. American Society for Gastrointestinal Endoscopy (ASGE) Guideline, Esophageal dilation. Gastrointestinal Endoscopy. 2006; 63 : 756-60
- [16]. American Society for Gastrointestinal Endoscopy (ASGE) Guideline, The role of endoscopy in the evaluation and management of dysphagia. Gastrointestinal Endoscopy. 2014; 79: 191-201
- [17]. Atmadzitis K, Papaziogas B, Pavlidis T, et al. Plummer-Vinson syndrome. Dis Esophagus 2003; 16(2): 154-7
- [18]. Sreenivas DV, Kumar A, Mannar KV, Babu GR. Results of Savary-Gilliard Dilatation in the Management of Cervical web of esophagus. Hepatogastroenterology 2002; 49:188-190
- [19]. Demirci F et al, Plummer-Vinson syndrome and dilatation therapy: A report of two cases, Turk J Gastroenterol 2005;4:224-7.
- [20]. Auris Nasus Larynx. 1999 Oct;26(4):495-500.. The operation of upper esophageal web in Plummer-Vinson syndrome: a case report. Kitahara S1, Ohmae Y, Ogura M, Matumura Y