

## Direct Immuno Fluorescence Study in Auto Immune Bullous Disorders

Nageswaramma.S , Vani.T, Swarnakumari.G , Ram mohan .Ch, Sirisha.G, Sowjanya.p.

Department of dermatology, venerology, leprosy , Guntur medical college, Guntur.

**Abstract:** Autoimmune vesicobullous disorders in dermatology are numerous ,the diagnosis can be helped by determining morphology of lesion, age group affected , histopathology and immunofluorescence(IF) .

**Aim:** The aim is to study histopathology of various Autoimmune vesicobullous disorders and its correlation with IF studies in patients attending DVL department, Guntur medical college.

**Material & Methods :** A total of 46 patients of various bullous disorders attending to department of DVL in one & half year period from January 2013 to July 2014 were analysed. of these females (29), males (17), and (3) were children .The clinical features and histopathology were correlated with direct immunofluorescence (DIF) findings.

**Results:** out of 46 patients we studied, females were 29( 6.04 %), males 17(36.95%), children 3 (6.5%). 40 to 60 yrs age group were more commonly affected .we studied & correlated histopathology with IF , of these 24 patients (52.17%) were pemphigus vulgaris. 13 (28.26 %) were bullous pemphigoid. 2 were (4.34%) Dermatitis herpetiformis, 2 (4.34 %) were pemphigus vegetans, 2 were pemphigus foliaceus(4.34%), 3 were CBDC ( 6.52%).

**Discussion & Conclusion :** Histopathology & immunofluorescence findings were correlated in majority (95.5%) of autoimmune bullous disorders except few cases (4.5%) where clinically diagnosed conditions differed from immunofluorescence findings. To conclude, the correlation between clinical findings, Histopathology and Immunofluorescence plays a predominant role to confirm the atypical appearance of autoimmune blistering diseases.

**Keywords:** Autoimmune disorders, Direct immunofluorescence, Vesicobullous lesions.

### I. Introduction

Direct Immunofluorescence (DIF) is a histochemical laboratory staining technique used for demonstrating the presence of immune complexes in the skin at various locations such as (intercellular) in epidermis, Dermo epidermal junction, dermal blood vessels. DIF has become an indispensable diagnostic tool in the diagnosis of immunobullous disorders of the skin. It has been widely used to supplement the clinical and histological features of various vesicobullous disorders.

The diagnostic specificity of clinical findings varies among various bullous disorders. There is a clinical overlap among various groups of bullous diseases for example; Linear IgA dermatosis may mimic BP or DH. IgA pemphigus may mimic pemphigus foliaceus, pemphigus herpetiformis, subcorneal pustular dermatoses . Inflammatory EBA is indistinguishable from BP.This differentiation between the entities is important for both treatment modalities & prognosis.

The AIM of the study is to analyze and correlate clinical, histopathological with Direct immunofluorescence findings of various autoimmune blistering disorders .

### II. Methods And Material

The present study was conducted in the Department of DVL from Jan 2013 to July 2014 i.e 18 months. The patients were selected from the in and out patient department of Dermatology, and the informed consent was obtained. Patients with clinical diagnosis of various autoimmune blistering disorders willing to participate in this study were included irrespective of age, gender. .

Clinical data was recorded in the form of :

- Detailed clinical history .
- General & dermatological examination .
- Routine investigations.
- Tzanck smear for Acantholytic cells.
- After taking written informed consent of the patients, two biopsies were performed one from the fully developed vesicobullous lesion (lesional biopsy) for histopathological examination.

- The other from the perilesional skin area with in 2cm of diameter of lesion (perilesional biopsy) for Direct immunofluorescence .

A total of 46 cases, clinically diagnosed as Autoimmune bullous disorders were included in this study.

For HPE lesional skin biopsy was sent in 10% formalin ,following standard processing ,the sections were stained with H and E stain.For DIF, the biopsies were obtained in holding fluid (Michelle's medium) containing a saturated solution of ammonium sulfate in buffer at room temperature and stored at 4°C until cut.

While reporting DIF findings, the fluorescent staining was described under the following headings :

1. Type of immunoreactants: IgG, IgA ,IgM ,C3 & fibrin.
2. Location of immune deposits : intercellular in epidermis / basement membrane zone / blood vessels / hair shaft.
3. Pattern of immune complex deposits: Granular/ linear.
4. Semiquantitative grading of strength of fluorescence : + to ++++.

The description of all these staining characteristics leads to immunopathological diagnosis.The definite diagnosis of these patients was based on clinical histopathological and immunofluorescence findings.

### **III. Results**

The study group comprised of 46 cases, with 29 females (63%) and 17 males (37%) . In that 3 were children . The age ranged from 10 years to 75 years.

The clinical diagnosis of predominant cases were pemphigus vulgaris in 24 patients (52.17%), Bullous pemphigoid in 13 patients (28.26 %), Dermatitis herpetiformis in 2 patients (4.34%), pemphigus vegetans in 2 patients (4.34 % ) , pemphigus foliaceus in 2 patients (4.34%) , CBDC in 3 patients ( 6.52%) [ table 1].

Discordance between clinical , histopathological , DIF findings were noted [ Table 2].Over all 95.5% cases were correlated clinically,histopathologically with DIF findings.

### **IV. Discussion**

The diagnosis of autoimmune bullous disease was based on evaluation of Clinical findings, Histopathology & Direct immunofluorescence.

The most frequent disorder in our study was pemphigus vulgaris followed by bullous pemphigoid ,Cases of limited number in our study were pemphigus foliaceus, pemphigus vegetans, CBDC, Dermatitis herpetiformis.Male to female ratio was 1:1.7 which is comparable to the findings of Shamim et al, Archana et al.

In the present study , DIF was able to confirm 95.67% of clinically diagnosed cases. In a study by Minzet al; DIF was able to detect 70% of clinically diagnosed vesicobullous lesions of the skin.

All ( 24 ) cases, clinically diagnosed as pemphigus vulgaris (PV) were confirmed by both HPE and DIF. DIF findings in pemphigus vulgaris showed IgG positivity in ICS in fishnet pattern in 80%. Few cases showed both IgG and C3 deposition in ICS. This is comparable with other studies. DIF is positive in 90 to 100% of patients with active disease if an appropriate biopsy specimen has been obtained.

The pattern of fluorescence appears as continuous around individual keratinocytes, Occasionally the fluorescence may be limited to or most intense at the level of the epidermis that is involved with blister formation . This variation in the intensity of fluorescence at various layers of the epidermis may be caused by differences in the relative amounts of the target desmosomal proteins for each of the two diseases, namely desmoglein 1 for pemphigus foliaceus, and desmoglein 3 for pemphigus vulgaris, c3 may also be seen, usually with intensity lower than IgG.

In pemphigus foliaceus, all cases DIF showed IgG and C3 deposition in upper epidermis in ICS. This finding is helpful to differentiate pemphigus foliaceus from pemphigus vulgaris.

Bullous pemphigoid affects the elderly during 5<sup>th</sup> to 7<sup>th</sup> decade of life, with an average age of onset being 65yrs. Bullous pemphigoid occurred in (13) 28.26% in our study patients.Of them were confirmed by DIF , 68% patients showed linear IgG & C3 deposition in the Basement membrane zone ,one has C3 deposits along BMZ. One was clinically diagnosed as CBDC was picked on DIF as BP showed IgG,C3 deposits along BMZ .

In our study DIF sensitivity for BP 100%, but Sano SM observed DIF detection rate in patients with BP as 55.6%. Herpes gestationalis, linear IgA dermatosis and EBA show subepidermal bullae with neutrophil

rich infiltrate, which can be confused with BP. However, DIF helps to differentiate these conditions from BP.

All (2) cases clinically diagnosed as of pemphigus vegetans were confirmed by DIF. Pemphigus vulgaris and vegetans have similar DIF findings and hence need to be differentiated by clinical and HPE characteristics.

In our present study, two cases of DH were seen both being males aged 25yrs and 30yrs. Out of two cases clinically diagnosed as DH, One was consistent with DH showed granular IgA deposit at dermal papillae, and the other turned out to be Pemphigus Herpetiformis. Histopathology showed subcorneal bullae, eosinophilic spongiosis, slight acantholysis, DIF showed IgG intercellular deposits in epidermis like pemphigus group. The recognition of pemphigus herpetiformis as a variety of pemphigus is practically important since it differs clinically, histopathologically both from pemphigus vulgaris, foliaceus and requires a different therapeutic regimen.

All the 3 clinically diagnosed CBDC cases, were histopathologically consistent with CBDC, BUT only 2 were consistent with DIF showed linear deposits of IgA along BMZ, and the other case was turned out to be BP.

The limitation of our study was the salt split technique could not be done. Further studies are planned using this technique to differ subepidermal disorders.

DIF is a useful aid when it comes to diagnosing autoimmune bullous disorders which may have a confusing similar clinical profile.

Conclusions:

In the present study, DIF was able to confirm 95.67% of clinically diagnosed cases. Our study validates that DIF is requisite for diagnosis of autoimmune bullous disorders of skin

#### Key message

Thus improved detection and confirmation of clinical diagnosis of diseases like Pemphigus Herpetiformis, DH, CBDC, Bullous SLE, is attainable with DIF only.

**TABLE NO:1**

#### Clinical types of blistering disorders:

CLINICAL ENTITY	NO OF CASES	PERCENTAGES
PEMPHIGUS VULGARIS	24	52.17
PEMPHIGUS FOLIACEOUS	02	4.34
PEMPHIGUS VEGETANS	02	4.34
BULLOUS PEMPFIGOID	13	28.26
DERMATITIS HERPETIFORMIS	02	4.34
CBDC	03	6.52

GRAPHICAL PRESENTATION:

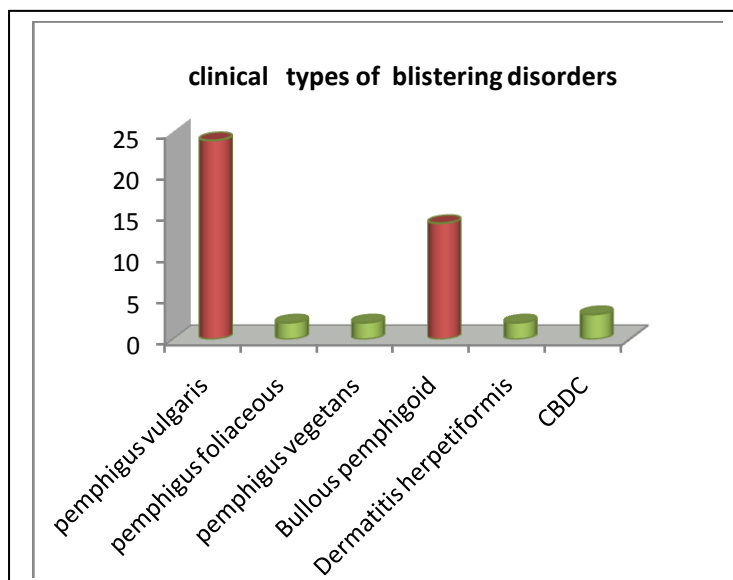


TABLE NO:2 Showing consistent histopathological findings and DIF findings

Disease entity	No of cases	Consistent histopathological diagnosis		DIF findings		Site of deposits
		POSITIVE	NEGATIVE	POSITIVE	NEGATIVE	
PEMPHIGUS VULGARIS	24	24	--	24	--	Intercellular,IgG,Epidermis
PEMPHIGUS VEGETANS	02	02	--	02	--	Intercellular,Epidermis
PEMPHIGUS FOLIACEOUS	02	02	--	02	--	Intercellular,IgG,Epidermis
BULLOUS PEMPHIGOID	13	13	--	13	--	IgG,Linear,BMZ
DERMATITIS HERPETIFORMIS	02	01	01	01	--	Granular,IgA,Dermalpapillae
CBDC	03	03	--	02	--	Linear,IgA,BMZ

TABLE NO: 3 DIF findings types of Ig, its pattern , Site of deposits.

Disease entity	DIF positivity	IgG	IgM	IgA	C3	Site of deposits
PEMPHIGUS VULGARIS	24	24	----	----	3	Intercellular,IgG,Epidermis
PEMPHIGUS VEGETANS	02	02	----	----	01	IgG,ICS,Epidermis
PEMPHIGUS FOLIACEOUS	02	02	----	----	01	IgG,ICS,Upper Epidermis
BULLOUS PEMPHTIGOID	13	13	----	----	10	IgG,Linear,BMZ
DERMATITIS HERPETIFORMIS	01	---	01	01	01	Granular,IgA,Dermalpapillae
CBDC	02	---	02	02	--	Linear ,IgA,BMZ

**PEMPHIGUS VULGARIS :**

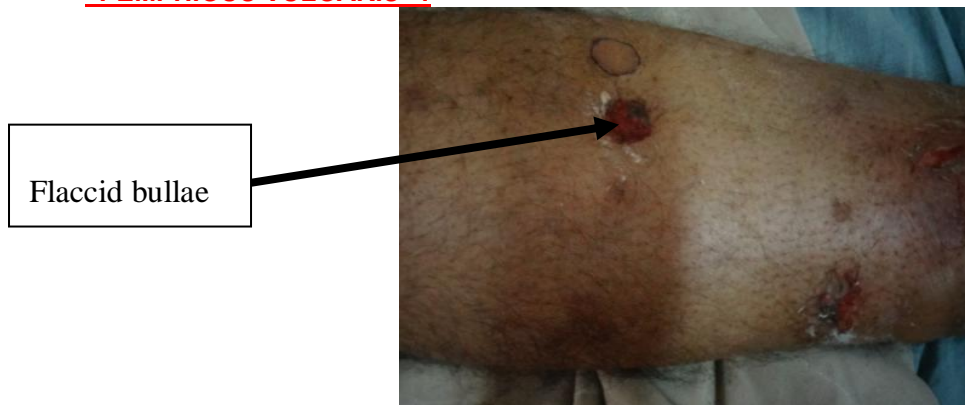

Fig 1: pemphigus vulgaris showing flaccid bullae

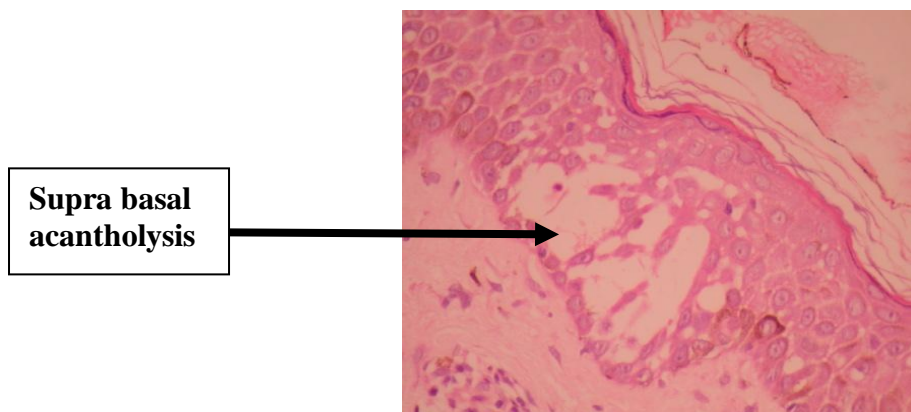


Fig 2: Pemphigus vulgaris showed intraepidermal blister ,suprabasal acantholysis

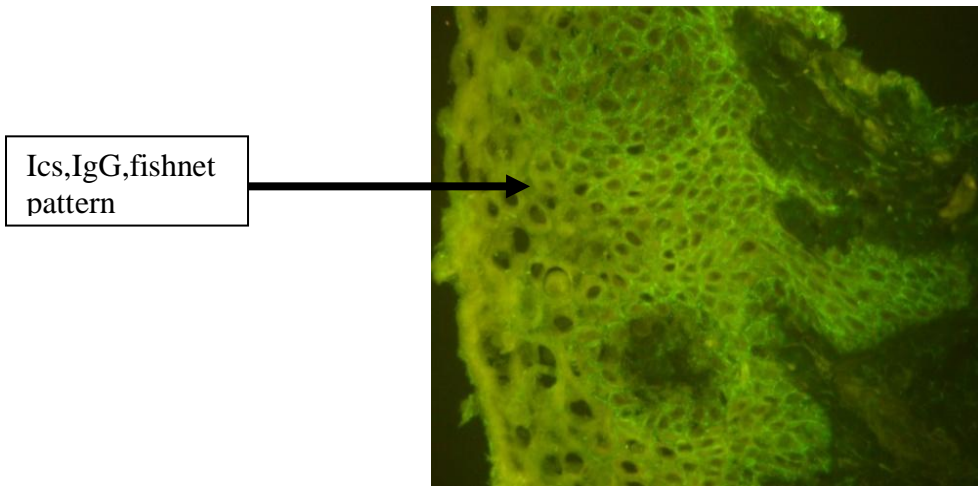


Fig 3: Direct immunofluorescence of pemphigus vulgaris showed lace/fishnet pattern of IgG,ICS

**PEMPHIGUS HERPETIFORMIS:**

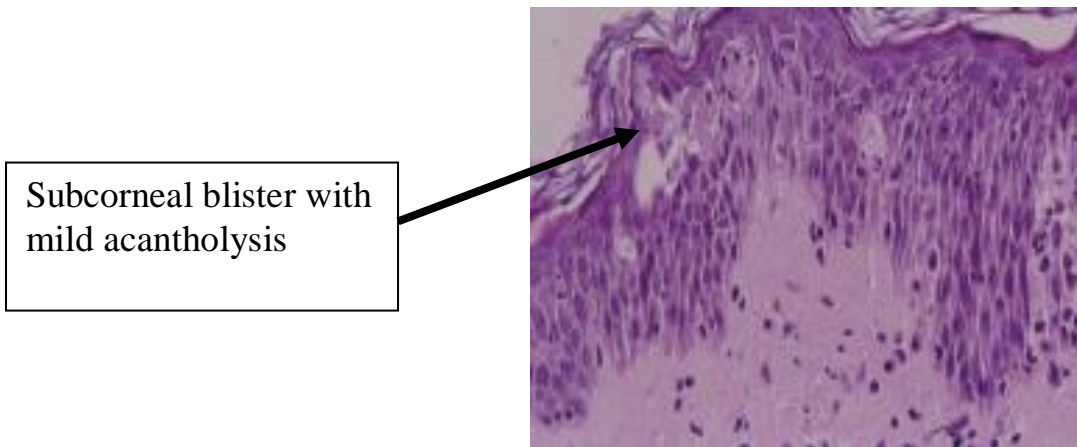
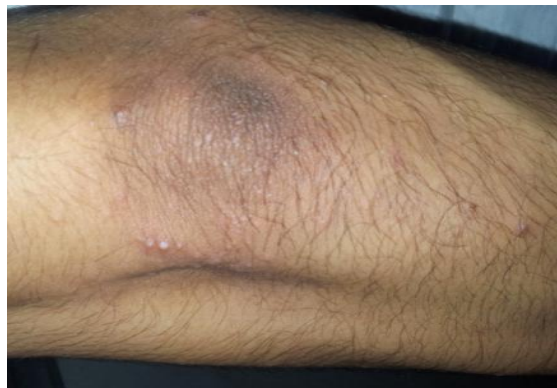


Fig no:4 Pemphigus herpetiformis showed subcorneal blister

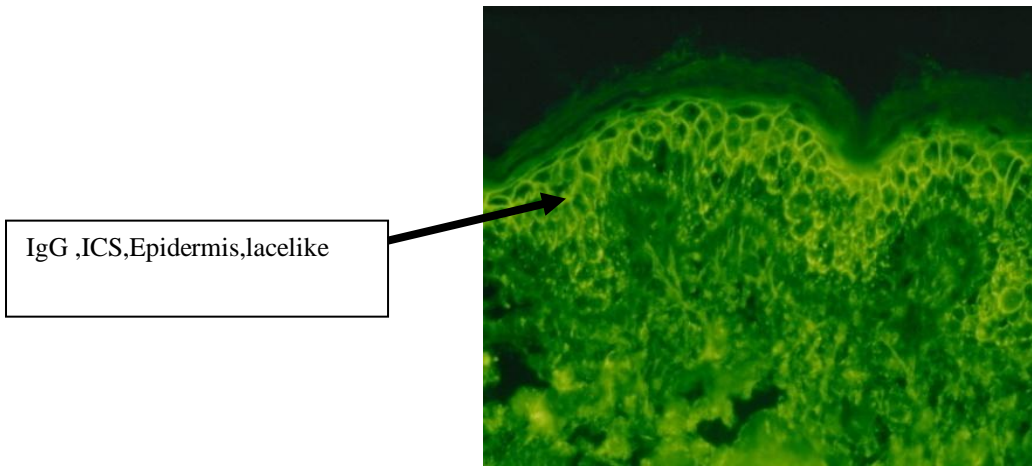
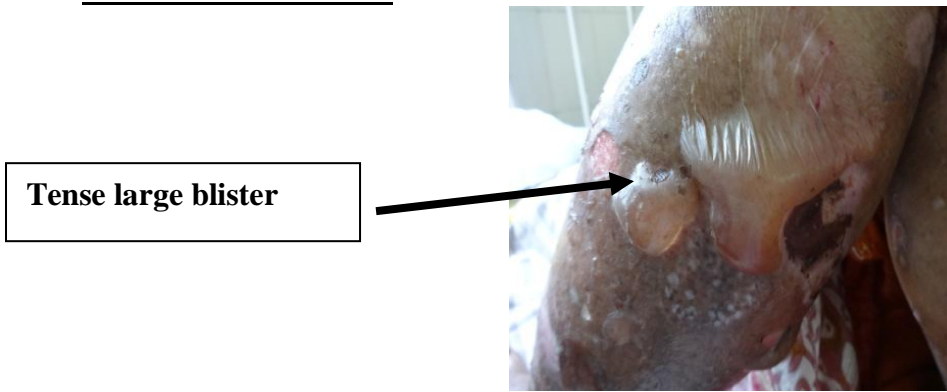


Fig no: 5 Pemphigus herpetiformis on Direct immunofluorescence showed IgG,ICS, Upper epidermis

**BULLOUS PEMPHIGOID:**



Figno:6 Bullous pemphigoid showed multiple tense large blister

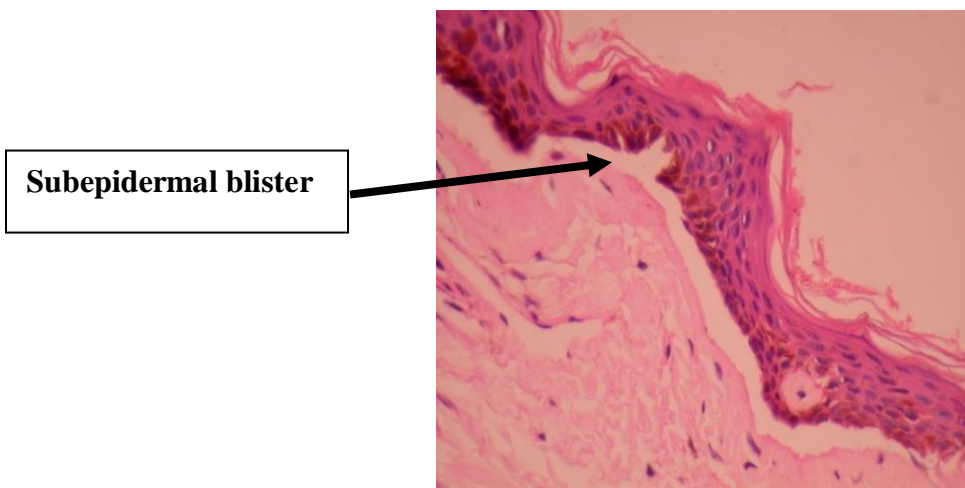

Fig no:7 Bullous pemphigoid showed subepidermal blister

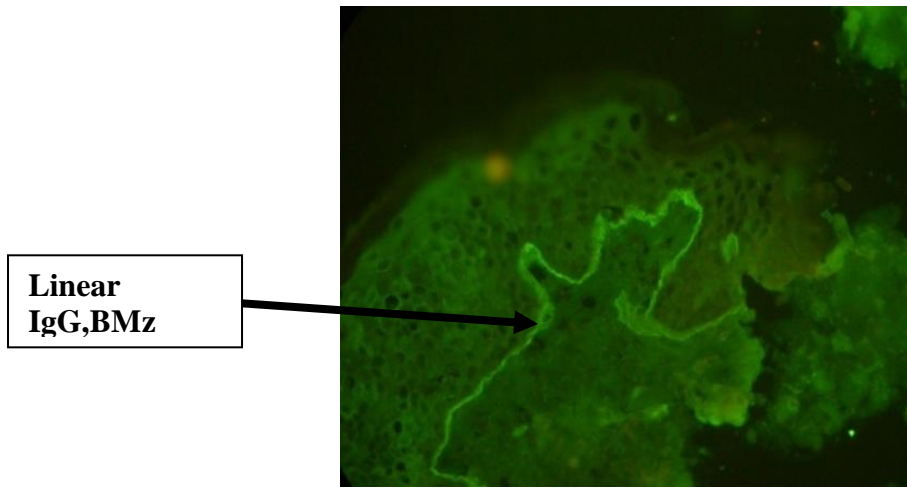


Fig no: 8 Bullous pemphigoid Showed linear IgG ,along BMZ

**CBDC:**

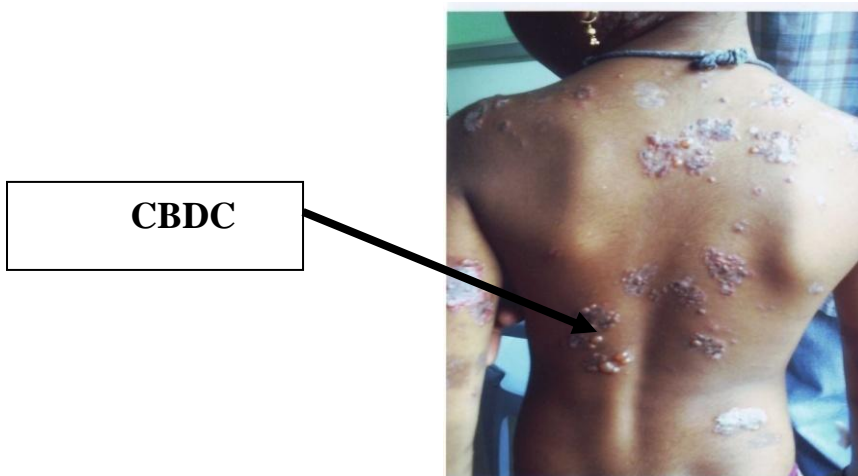


Fig no:9 CBDC child showed string of pearl sign

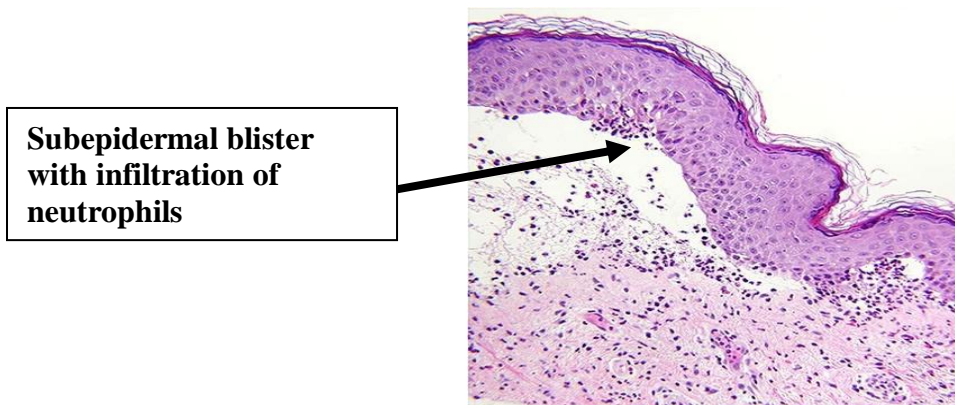
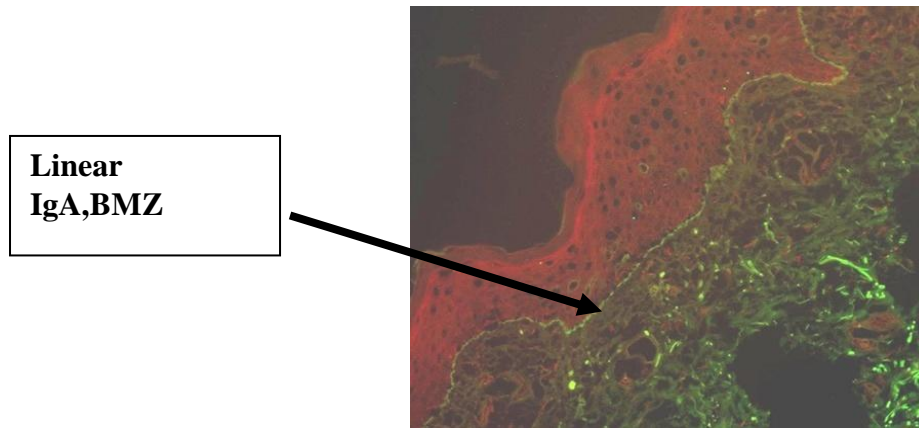


Fig no :10 CBDC,HPE showed subepidermal blister with infiltration of neutrophils





Figno: 11 CBDC,DIF showed linear deposition of IgA along BMZ

### References

- [1]. 1.Mahmood T, Haroon TS.patterns of direct immunofluorescence in sub epidermal vesicobullous lesions of skin in lahore, pakistan. J Pak assoc Dermatol 2003;13;67-71.
- [2]. 2.Inchara yk, Rajalakshmi T. Direct immunofluorescence in cutaneous vesicobullous lesions.Indian J Pathol microbiol 2007;50:730-2.
- [3]. 3.Mutasim DF, Adams BB. Immunofluorescence in dermatology. J Am Acad Dermatol 2001;45:803-22.
- [4]. 4.Huilgol sc, Bhogal BS, Black MM. Immunofluorescence of the immunobullous disorders part one: Methodology. Indian J Dermatol Venereol Leprol 1995;61:187-95.
- [5]. 5.Lebe B, Gul Niflioglu G, Seyrek S, Ellidokuz H. Evaluation of clinical and histopathologic/direct immunofluorescence diagnosis in autoimmune vesicobullous dermatitis. Utility of direct immunofluorescence . Turk Patoloji Derg 2012;28:11-6.
- [6]. 6.Minz RW, Chhabra s, Singh S, Radotra BD, Kumar B.Direct immunofluorescence of skin biopsy: perspective of an immunopathologist . Indian J Dermatol Venerol Leprol 2010;76:150-7.
- [7]. 7.Rizvi SR, Sadiq S. Use of direct immunofluorescencet microscopy in the diagnosis of vesicobullous disorders of skin . Pak J Med sci 2010,26:411-5.
- [8]. 8.Beytner EH, Chorzelski TP, Jablonska S. Immunofluorescence tests. Clinical significance of sera and skin in bullous diseases.Int J Dermatol 1985;24:405-21.
- [9]. 9.Sitaru C, Zillikens D. Mechanisms of blister induction by autoantibodies.Exp Dermat 2005;14:861-75.
- [10]. 10.Sitaru C, Mihali S, Zillikens D. The relevance of the IgG subclass of autoantibodies for blister induction in autoimmune bullous skin diseasea.Arch Dermatol Res 2007;299:1-8.