

Gender Determination Using Cheiloscopy In Pediatric Population.

Mohammed Almuhaiza¹ Rajashekhara Bhari Sharanesha²,
Deepti Virupakshappa³

¹(College of Dentistry/Salman Bin Abdul Aziz University, Saudi Arabia)

²(College of Dentistry/Salman Bin Abdul Aziz University, Saudi Arabia)

³(Faculty of Dentistry /Al-Qassim Private College, Saudi Arabia)

Abstract: AIM: The present study was designed for documenting common patterns, as well as their disparity in the study population, with objective of evaluating uniqueness of the lip print pattern among the study population, as well as to evaluate the possibility of gender determination.

Materials And Methods: The study sample comprises of 103 children i.e., 49 males & 54 females of aged between 4 to 14 years. Lip prints were recorded with transparent overlay and transferred on to a bond paper. The impression is visualized with the use of a magnifying lens. Lip prints were later analyzed. Chi square test was used to find out degree of association between variables and to check out whether statistically significant differences exist. *p* value <0.05 was considered to be statistically significant.

Conclusion: In our study no two lip print patterns matched each other thus establishing the uniqueness of lip prints. It was found that Type II: Branched grooves (branching Y-shaped pattern) was the predominant pattern in both males and females.

Keywords: Forensic, gender, lip print,

I. Introduction:

Establishing a person's identity is a very important process in civil and criminal cases. Dental, fingerprint and DNA comparisons are probably the most common techniques allowing fast and secure identification processes. The grooves present on the human lips are unique to each person and can be used to determine identity. The study of these grooves or furrows present on the red part or the vermilion border of the human lips is known as cheiloscopy¹

This biological phenomenon was first noted by anthropologists. R. Fischer was the first to describe it in 1902². They are identifiable as early as the sixth week of intrauterine life, and from that time on, their pattern rarely changes, resisting many afflictions such as herpetic lesions³⁻⁵

Features of the lip print relative to the surrounding anatomy were also examined and found to be stable, recordable and to contribute to the usefulness of lip prints as a forensic tool⁶.

In the past decades, lip-print studies (cheiloscopy) attracted the attention of many scientists as a new tool for human identification in both civil and criminal issues. The present work aimed to study in depth the lip prints of children (males and females) in Davangere. It is the first chieloscopic study done on children in Karnataka.

II. Materials And Methods:

The present study was conducted in the Department of Pediatrics And Preventive Dentistry, College of Dental Sciences, Davangere.

Study sample

The study sample comprises of 103 children i.e., 49 males & 54 females of aged between 4 to 14 years. Prior to the commencement of the study, approval will be taken from the ethical committee to conduct the study. Consent of all the participants is obtained for the study.

Study materials

Materials required for the study are,

1. Brown and red colored lipstick
2. Cellophane tape
3. White chart paper
4. Magnifying lens

Technique

A dark colored lipstick is applied with a single stroke, evenly on the vermilion border. The subjects were asked to rub both the lips to spread the lipstick .After two minutes a lip impression was made on a strip of cellophane tape on glued portion, which was then stuck to a white bond paper .This serves as permanent record .The impression is visualized with the use of a magnifying lens.

In this study, we are following the classification of patterns of the lines on the lips Proposed by Tsuchihashi Y⁷.

1. Type I: Clear cut vertical grooves that run across the entire lips.
2. Type I¹: Similar to Type I, but do not cover the entire lip.
3. Type II: Branched grooves (branching Y-shaped pattern)
4. Type III: Criss-cross pattern, reticular grooves
5. Type IV : Undetermined

For classification, the middle part of the lower lip (10-mmwide) is taken as study area as proposed by Sivapathasundaram et al⁸.Because this is almost always visible in any trace. The results obtained verified from the coded data collected at the beginning of the study.

III. Observations and Results:

All the data were entered in Microsoft excel and analyzed using SPSS package (version 17). All the data were presented as frequency and percentages. Chi square test was used to find out degree of association between variables and to check out whether statistically significant differences exist .p value <0.05 was considered to be statistically significant

**Lip type * Gender
Crosstab**

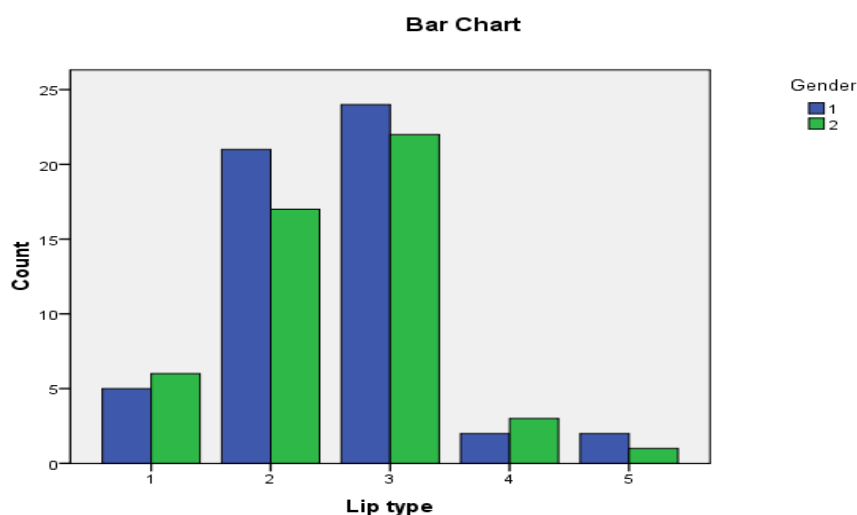
Count		Gender		Total
		1	2	
Lip type	1	5	6	11
	2	21	17	38
	3	24	22	46
	4	2	3	5
	5	2	1	3
Total		54	49	103

Both lip type and gender is denoted as Type I-1, Type I¹-2, Type II-3, Type III-4,Type IV-5 and Gender as 1- female,2-male

Chi-Square Tests

	Value	Df	Asymp. Sig. (2-sided)
Pearson Chi-Square	.892 ^a	4	.926
Likelihood Ratio	.898	4	.925
Linear-by-Linear Association	.025	1	.875
N of Valid Cases	103		

a. 4 cells (40.0%) have expected count less than 5. The minimum expected count is 1.43.



IV. Discussion:

Cheiloscopy is an upcoming tool for the identification of a person's lip print. It is one of the most interesting and emerging methods of human identification, and originates from criminal and forensic practice⁹. Lip prints are unique and do not change during the life of a person¹⁰. These can be obtained at the crime scene from clothing, cups, cigarettes, windows and doors⁹.

In our study it was found that Type II: Branched grooves (branching Y-shaped pattern) was the predominant pattern in both males and females. This was followed by Type I: Similar to Type I, but do not cover the entire lip. Type IV (undetermined) pattern was the least common of all patterns.

Various studies in India have shown population-wise dominance. Sivapathasundaram et al., and Saraswati et al., studied lip print patterns and found that Type III was the predominant lip pattern in the Indo-Dravidian population^{8,11}. Varghese et al., found Type IV as a predominant pattern in both males and females in subjects from Kerala¹².

In our study we found Type II: Branched grooves (branching Y-shaped pattern) was the predominant pattern in both the sexes in the Davangere population. We did not observe any statistically significant difference between males and females in individual lip print types in our study group.

India is a vast country with large ethnic variation. More studies should be conducted in different centers with a larger pediatric sample size to form a Cohesive Cheiloscopy System which would be a useful tool in forensic odontology. There are certain limitations. Various factors can alter lip print recording. The patterns also depend on the position of the lip. The closed mouth position lips exhibit well-defined grooves and are easy to interpret which is not the case with the open position lips. There can be erroneous results in case of pathology and loss of front teeth. The lip print appearance may also be affected by the pressure, direction and method used while taking the impression^{13,14}.

V. Conclusion:

Lip prints are unique for every person and show differences according to the race and the ethnic origins of a person¹². In our study no two lip print patterns matched each other thus establishing the uniqueness of lip prints. It was found that Type II: Branched grooves (branching Y-shaped pattern) was the predominant pattern in both males and females. We did not observe any statistically significant difference between males and females in individual lip print types. Though emerging as a promising tool, lip print recording is a tedious task which is technique-sensitive. More collaborative work needs to be done involving multiple centers and larger study groups to reach a consensus in order to have practical implications.

Acknowledgement

I am personally very much thankful to all my colleagues who supported me directly or indirectly to conduct and complete my work.

References

- [1]. Nandy A. Principles of Forensic Medicine. 2nd edition. Calcutta: Central; 2003.p. 100-101.
- [2]. Kasprzak J. Possibilities of Cheiloscopy. Forensic Sci Int. 1990; 46: 145-151
- [3]. M. Alvarez, Cosmetic advances and criminalistics, The Study of Lip Prints Generated by Permanent Lipstick, Doctoral Thesis University of Valencia Spain, 1999.

- [4]. M.A. Molano, J.H. Gil, J.A. Jaramillo, S.M. Ruiz, Estudio queilosco' p'ico en estudiantes de la facultad de odontolog'ia de la Universidad de Anti'oquia, Rev. Fac. Odonto. Univ. Antioquia 14 (1) (2002) 26–33.
- [5]. Castello, M. Alvarez-Segui, F. Verdu, Luminous lip-prints as criminal evidence. Forensic, Sci. Int. 155 (2–3) (2005) 185–187.
- [6]. Coward RC. J Forensic Odontostomatol. 2007 Dec; 25(2):40-56.
- [7]. Tsuchihashi Y. Studies on personal identification by means of lip prints. Forensic Sci 1974;3:233-48.
- [8]. Sivpathasundaram B, Prakash PA, Sivakumar G. Lip prints (Cheiloscopy). Indian J Dent Res 2001;12:234-7.
- [9]. Reddy LV. Lip prints: An overview in forensic dentistry. J Adv Dent Res 2011; 11:16-20.
- [10]. Gondivkar MS, Indurkar A, Degwekar S, Bhowate R. Cheiloscopy for sex determination. J Forensic Dent Sci 2009;1:56-9.
- [11]. Saraswathi TR, Misra G, Ranganathan K. Study of lip prints. J Forensic Dent Sci 2009;1:28-31.
- [12]. Verghese AJ, Somasekar M, Umesh BR. A study on lip print types among the people of Kerala. J Indian Acad Forensic Med 2010; 32:6-7.
- [13]. Kavitha B, Einstein A, Sivpathasundaram B, Saraswati TR. Limitations in forensic odontology. J Forensic Dent Sci 2009;1:8-10.
- [14]. Vahanwalla SP, Parekh BK. Study on lip prints as an aid to forensic methodology. J Forensic Med Toxicol 2000;17:12-8.