

Jess and Illizarov in Neglected /Relapsed Ctev: A Prospective Comparative Study

Ramesh Chandra Meena, Devi Sahai Meena, Purnima Patni, Narendra Saini,
Ankit Chauhan

Department of orthopaedics sms medical college, rajasthan university of health science jaipur, india

Abstract:

Background: Neglected and relapsed club foot deformities remains a difficult problem even for the most experience surgeon .Our purpose of this studies was to evaluate the role of jess and illizarov for correction of deformities in neglected / relapsed ctev .

Methods and Material: This prospective study was conducted in SMS hospital attached to SMS Medical College, Jaipur from April 2012 – September 2013. 21 patients (n=28 feet) were included. Average age was below 8 year (range 3 to12 years). Unilateral feet and male were more in this study.

Results: Severity of the deformities and outcome was assessed by dimeglio score. In Illizarov group (n=15) result were excellent (27%), good(23%), fair (13%) and poor (20%).in Jess group(n=11), result were excellent(15%) , Good(23%), fair(23%) and poor(39%) .

Conclusions: External fixators are versatile technique for correction of deformities in neglected/relapsed CTEV
Key-words: ctev, deformities, illizarov frame, jess

I. Introduction:

Idiopathic club foot is one of the oldest and commonest congenital deformities of mankind even since man has adopted in erect posture [6]. In developing countries, clubfoot remains a significant problem and yields an unpredictable outcome because of late presentation and ignorance of the parents. Neglected clubfoot usually presents the unyielding rigid deformities because of the extremely contracted skin, tendons, ligaments and capsules on the postero medial aspect of the foot. Remodeling of the tarsal bones in the deformed position usually results in altered shape, which has an effect on the unpredictable results of treatment in such feet. . The outcome of conservative and surgical method in a relapsed clubfoot is usually poor because of the extensive fibrosis and scars of the earlier surgery. So this study was conducted to evaluate the outcome of jess and illizarov in neglect /relapsed ctev .

II. Materials And Methods

This prospective comparative study was conducted on 28 feet of 21 patients during the period from October 2010 to December 2012 in SMS medical college, attached hospital jaipur.

Relapsed and neglected cases up to age of 3- 12 year was included in this study. Non idiopathic club feet, Paralytic club feet (spina bifida), Club feet with associated anomalies such as: arthrogryopsis multiplex congenita were excluded from this study .

In this study patient were randomly selected in two group jess and illizarov, not on the basis of deformities .In bilateral feet deformities one foot included in jess group and another foot included in illizarov group .

Anteroposterior and lateral radiograph of both feet normal and affected feet were taken and talocalcaneal angle in AP & lateral view, talo 1st metatarsal angle in AP view were measured.

Dimeglio scoring system was used for preoperative and last follow up assessment of deformities .A score were assigned with one of the four parameter on a four point scale with four point given for reducibility from 90 degree to 45 degree , three point given for reducibility from 45 degree to 20 degree , 2 point given for reducibility from 20 degree to 0 degree 1 point given for reducibility from 0 degree to -20 [8] .Four additional point imparted, one point each for marked posterior crease ,medial crease , cavus deformity and poor muscle condition .These add up to a total 20 point . The feet graded according to total score as follow grade 1: mild deformity with score 0-5, grade 2: moderate deformity with score 5-10 grade 3: severe deformity with score 10-15, grade 4: very severe deformity with score 15-20 points.

Operative procedure:

JESS :The procedure is carried out under general anaesthesia with the patient in the supine position. The procedure involved two major steps- insertion of K- wires and creation of hold and connection between the hold.

Insertion of K-wires

- **Tibial K-wire placement:** With the patient in supine position and extended limb, two parallel K-wires were passed in the proximal tibial diaphyses from the lateral to the medial side. The wires were about 3 to 4 cm apart and run parallel to the axis of the knee joint one finger breadth distal to tibial tuberosity. In older children 3 wires were passed to increase the stability.

- **Calcaneal K-wire placement:** Two parallel K-wires were passed through the tuber of calcaneum from medial to lateral side taking care that they were well away from the course of the neurovascular structures on the medial side. One additional half pin K-wire was passed from the posterior aspect of the calcaneum along the long axis. The entry point was below the insertion of the tendo-achilles in the midline using distractor as the guide.

- **Metatarsal K-wire placement:** One transfixing K-wire was passed through the necks of first and fifth metatarsal from lateral to medial side in such a way that the K-wire engaged the two metatarsals. Two additional wires were passed parallel to and 10 to 12 mm apart from either side engaging three metatarsals each so that the third metatarsal has engaging half pins from either side through it.

- **Creation of holds and connecting between the holds**

- Two 'Z' bars were attached to the tibial pins, one on either side. The wires were prestressed before the link joints were tightened. Two transverse bars were attached to the 'Z' rods, one anteriorly and one posteriorly. Calcaneo-metatarsal distractors were then attached to the K-wires. Two 'L' rods were attached to calcaneal K-wires and two other 'L' rods were attached to the metatarsal K-wires one on either side with the arms of the 'L' rods facing posteriorly and inferiorly. One posterior transverse bar was attached to the posterior calcaneal half pin and the posterior arms of the 'L' rods.

- Tibiocalcaneal distractors were applied, one on each side connecting the corresponding transverse rods. Two additional transverse rods were attached to the inferior arms of the 'L' rods which took the toe sling which provided dynamic traction to prevent flexion contracture of the toes as the deformity was being corrected. All four distractors were distracted till resistance was felt. Extra lengths of the K-wires were cut, and no tension was created in them.

- The transverse anterior rod of the tibial hold and metatarsal hold was connected on either side static tibiometatarsal connecting rod. This provided tension force and kept the anterior portion of the joint open. It also prevented crushing of the articular cartilage and provided better glidage to the talus while correcting the equinus.

- Adequate skin release was made at the pin entry sites. Haemostasis at the pin entry wounds was achieved with pressure. Dry dressing of the pin entry wounds was done after cleaning. The sharp cut ends of the Kirshner wires were protected.

Distraction schedule

- In all hospitalized patients, fractional calcaneo-metatarsal distraction was applied from second post-operative day at the rate of 0.25 mm/hrs. Differential distraction on medial side was performed twice the rate than that on the lateral side (0.25 mm every 6 hours medially and 0.25 mm every 12 hours laterally). In non-hospitalized patients parents do the distraction at the rate of 1 mm/daily on medial side and ½ mm/daily on lateral side. By calcaneo-metatarsal distraction, we achieved correction of forefoot adduction at tarso-metatarsal joints, stretching the socket for head of talus and reduction of calcaneocuboid joint.

- The tibio-calcaneal distraction is carried out in two positions. Initially, the distractors were mounted between the inferior limbs of the 'Z' rods and posterior limbs of the calcaneal 'L' rods. The distractors lie parallel to the leg and just posterior to the transfixing calcaneal wires. The distraction was applied at the rate of 0.25 mm every 6 hours medially and 0.25 mm every 12 hours laterally and the end-point was judged clinically. Distraction in this position corrected varus of the hindfoot and equines. The tibio calcaneal distractors were then shifted posteriorly and connected above to the transverse bar connecting the posterior limbs of 'Z' rods and below to the posterior calcaneal bars connecting the posterior limbs of 'L' rods and axial calcaneal pin. The distractors lie on the either side of the axial calcaneal pin. Distraction in this position provided thrust force to stretch posterior structures and corrected hind foot equinus at the ankle and subtalar joints. Both distractors were applied at the rate of 0.25 mm every sixth hourly and the end point assessed clinically and radiologically.

- Visual correction of the deformities was noted during the distraction phase. Full correction was achieved, usually at the end of 5 to 6 weeks. X-ray was taken finally after the removal of the fixator. Following

the correction, assembly is held in static position for further three to six weeks to allow soft tissue maturation in elongation position. Single stage removal of the whole assembly was done under general anaesthesia. After removal of the assembly, a well moulded below knee plaster cast was applied in maximum correction. The child was allowed to ambulate full weight bearing in the plaster. Later, a short plaster boot was applied which not only acted as an orthotic device but also allowed mobilization of ankle joint and strengthening of tendoachilles. Squatting was encouraged to achieve dorsiflexion of the foot. Plaster was changed for 2-3 times at an interval of 15 days.

- Then an orthosis was prescribed to hold the correction during night time and a day wearing shoe was prescribed for the day time. The child was reevaluated for the correction of deformity attained. X-rays of the foot, anteroposterior and lateral view in stress dorsiflexion was obtained to assess correction, the child was then followed up at three monthly intervals.

III. Illizarov:

Site of k wire:

(1) **Proximal tibial k wire:** Two K wire (1.8 mm diameter) is inserted at the junction of upper and middle third of tibia. First wire is inserted at about one finger breadth lateral and behind the shin of tibia with an inclination of the wire aiming to emerge at the same level just anterior to the medial border. Second wire is inserted about one finger breadth anterior to the palpable anterior border of fibula at a point about 5 mm (thickness of ring 4 mm) below the level of first wire and with inclination anteriorly aiming the wire emerge about one finger breadth postero medial to the shin of tibia at about the same level .

(2) **Distal tibial wires :** Two k –wire (1.8 mm diameter) are inserted at the junction of distal and middle third of tibia .The first wire of this set is inserted through fibula and passed through the tibia with an inclination aiming the wire to emerge one finger breadth postero medial to the shin of tibia. the second wire is inserted through the safe middle zone into the tibia with an inclination to emerge just anterior to the medial border of tibia .one should be careful to avoid piercing of the great saphenous vein which crosses the medial border about 5 finger breadths above medial malleolus in anteroposterior direction .

(3) **Calcaneal wire:** one k wire inserted from antero medial to postero lateral and second wire inserted postero medial to antero lateral.

(4) **Fore foot metatarsal wire:** in the fore foot, the first olive wire is inserted from the outer side through the distal part of the 5th metacarpal almost at the neck and is advanced obliquely piercing the fifth, fourth and third metacarpal neck to emerge on the surface on the dorsum of the foot. The second olive wire is inserted on the medial surface in the first metacarpal neck which advanced obliquely to emerge on the dorsum of foot after piercing through second metacarpal neck .Before putting second wire head of second metacarpal should be lifted.

Size of ring: The size of ring should allow clearance at least of two finger breadths at the maximum girth of the limb .All four rings should be of the same size.

Proximal tibial ring: A full ring is placed approximately at the junction of upper third to middle third of the leg.

Distal tibial ring: A full ring is placed about 10 -12 cm above the ankle joint i.e. at about the junction of lower third and middle third of leg. Proximal tibial and distal tibial ring were connected with four threaded rods. The calcaneum half ring was connected to the distal tibial ring by hinge which is placed posteriorly, medially and laterally while the forefoot ring was connected to the calcaneum ring by medial and lateral hinge. . The forefoot ring is connected to the proximal tibial ring by single anterolateral and anteromedial rods Placed to pull the forefoot up out of equines and supination deformities. The hinge allows the rods to move without bending and also prevent the subluxation of joint during distraction. Half ring over the calcaneum was used as a distractor or pusher and compression or pulling was achieved through the half ring over dorsum of the forefoot.

The sequence of the deformity correction was gradual differential distraction over medial side 1mm /day and lateral side ½ mm/day to correct cavus and forefoot adduction which was started on the 2nd post operative day. After correction of forefoot adduction, and pronation, hind foot varus and finally equinus were corrected through the setting of the illizarov external fixator.

- During distraction, tension over soft tissue, neurovascular status, and improvement in the correction of the deformities were observed clinically, and radio logically dislocation or subluxation of tarsal and ankle joint was observed. Approximate 8-10 degree deformity was over corrected and this over lengthening of soft tissue avoided the recoil that could occur in the soft tissue after frame removal.

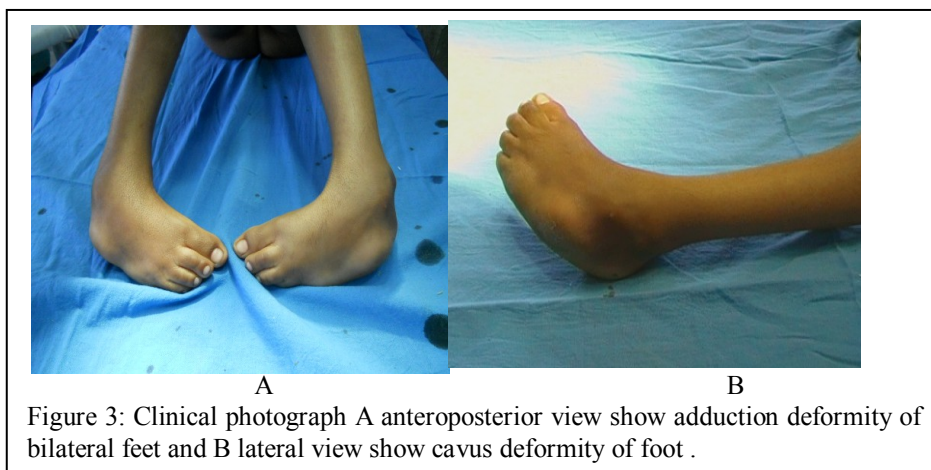
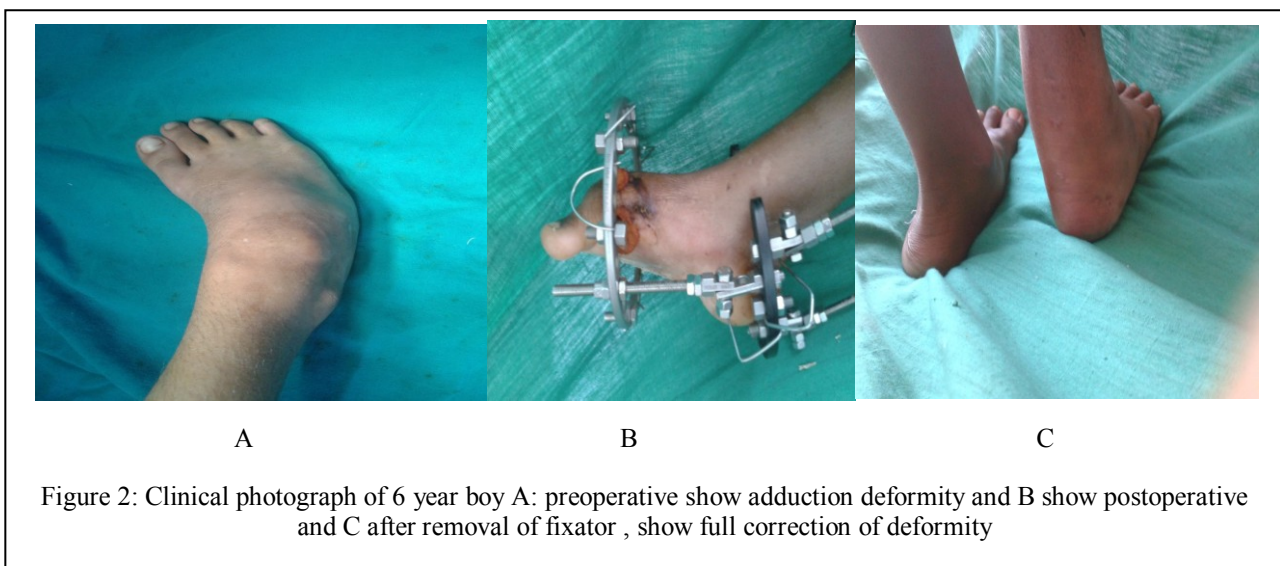
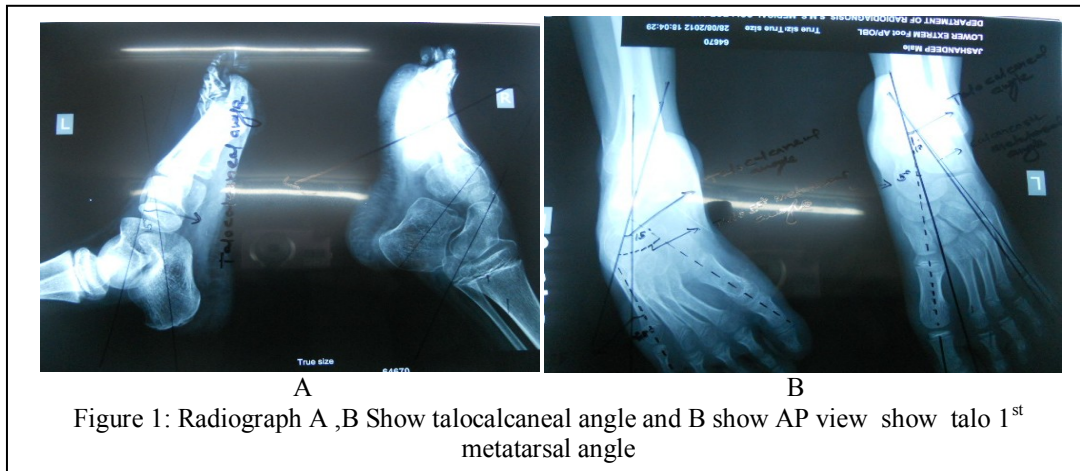
- All the pins were cleaned with normal saline and dressed with sterilized dry gauzes initially after 24 hours than after 72 hours. Loose clamps, nuts, and bolts were tightened regularly in our hospital initially weekly up to deformity correction.

- After complete correction, the distraction stopped and the illizarov was retained in fixed position for a further period of 4-6 weeks. Fixator was removed ,all the pins wounds were washed ,and aseptic dressing were

done , a short below knee walking pop cast was applied for 2 weeks, the patient were reviewed at the outpatient clinic after 2 weeks, and the pop cast was removed . The status of wound was checked and again short leg walking cast was applied for 4 weeks. The total time of the pop cast were 6 week after removal of the fixator, followed by an ankle foot orthosis (AFO) for 3 months in day and night.

Clinical photograph of the patient were obtained preoperatively, post-operatively, at the time of removal of fixator, at orthosis prescription and at follow-up.

IV. Figure And Table



Detail of patient

S. N.	Age In year	Sex	Side Involved	Side Operated	Family History	preoperative Dimeglio score	Previous procedure (Cons. / Surgical)	procedure (illizarov / jess)	Follow Up In month	complication		Postop. Dimeglio score	Result
										Early	Late		
1	6	M	B/L	R,L	-	15	Conservative	illizarov	18	PTI,ES,L	FF	3	Good
2	5	M	B/L	R,L	+	18	-	Jess	11	PTI,J,C	RFA,N	7	Poor
3	11	M	U/L	L	-	11	PMSTR	Illizarov	10	-	-	2	Excellent
4	9	M	U/L	L	-	17	Steindler+ost eotmy Of metatarsal base	Illizarov	9	PTI,SN	-	2	Fair
5	5	F	U/L	R	-	12	PMSTR	illizarov	10	E	-	3	Good
6	4	M	U/L	R	-	11	-	Jess	12	E,L,J	-	4	Fair
7	5	M	U/L	R	-	15	Conservative	illizarov	11	SN,PTI,C	-	2	Excellent
8	5	M	B/L	R,L	-	11	Conservative	Jess	22	E,PTI	-	3	Excellent
9	6	M	B/L	L	-	14	-	illizarov	27	L,C	-	2	poor
10	5	M	U/L	L	-	17	Conservative	Jess	9	L,J,	-	3	Good
11	7	M	B/L	R,L	-	17	-	Illizarov	25	-	-	2	Excellent
12	6	F	B/L	R,L	+	18	Conservative	Illizarov	26	PTI	-	3	Good
13	5	M	U/L	R	-	13	Conservative	illizarov	20	PTI,L	-	6	Poor
14	8	M	U/L	R	-	15	Conservative	illizarov	24	-	-	3	Good
15	4	M	U/L	R	-	12	Conservative	Jess	16	PTI,L,J	-	3	Fair
16	5	F	B/L	R,L	-	11	Conservative	Jess	9	E,L,J,C	FFA,GT A	5	Poor
17	4	F	U/L	R	-	12	Conservative	Jess	10	E,L,J,C	FFA	6	Poor
18	8	M	U/L	L	-	13	-	Jess	11	L,J,C	-	4	Good
19	10	M	U/L	R	-	11	Conservative	illizarov	9	L,J	-	3	Fair
20	6	M	U/L	R	-	12	PMSTR	Jess	10	PTI,L,	-	3	Fair
21	7	M	U/L	L	-	13	Conservative	jess	9	PTI,L,C	-	4	Good

V. Results:

In the illizarov group result were excellent 4 (27%), good 6 (40%), fair 2(13%) and poor3 (20%). In the jess group result were excellent 2(15%), Good 3 (23%), fair 3 (23%) and poor 5(39%).but no significant difference was found between two group. The average follow up period was 15.06 and 4 patient was absent at last follow up. We used dimeglio scoring system for clinical assessment of deformities of club foot [6]. In the illizarov group average preoperative score was 14.3 and post operative score was 2.81 whereas in jess group average preoperative score was 13 and postoperative score 4.2 . Average Talocalcaneal angle and Talocalcaneal index was better improved in illizarov group compare to jess group .Temporary edema was more in jess group (4 v/s 2) due to insertion of K wire in metatarsal. It subsided after elevating the feet and stopping the distraction. Clawing of toe is more in jess group (6 v/s 4) due to shortened and stretching of flexor during the distraction despite foot plate and elastic rubber sling. passive mobilization were advised for correction of clawing .After the removal of fractional distraction clawing of toe decreased and at the last follow up it was absent or slight visible. Pin tract infections were more in illizarov group (5 v/s 4) .In most of patients it subsided with dressing, oral antibiotics and tighten of loose screw and link joint. Loosening of fixator were more in jess group (9 v/s 3). Linear skin necrosis (n = 2) and epiphyseal separation of distal tibia (n=1) was found in illizarov group.Three long term complication such as recurrence of forefoot adduction were more in jess group (3v/s 2. During follow up flat foot (n = 1) was found in illizarov group and persistence of great toe adduction (n=1) was found in jess group.

VI. Discussion:

The goal of any club foot surgery is to obtain a cosmetically acceptable foot, pliable, functional, painless, plant grade foot and to spare the parent and the child from frequent hospitalization and years of treatment with casts and braces [1, 6, 8].

Physiological tension and stress applied to the tissues stimulates histoneogenesis, while controlled differential distraction gradually corrects the deformities and realigns the bones [10].

Our study was compared with the s suresh, A Ahmad et. Al. 1999, Oganessian and istomina -1999 C. F. Bradesh et .al .1999, Fernando De La Huerta, et al. -1994, Amin Abdel –Razek youssef Ahmed -2010 and Asadullah Makhdoom 2012.

In S Suresh, A Ahmed et. al. -1999 there were 44 feet with male predominating,bilateral more than the unilateral with age ranging from 0.8 – 6 years. There were more of younger group in the study; most of them are less than 3 years.

In Oganessian and istomina-1991 there were 70 feet with male predominating than female .Unilateral were more than the bilateral with average age of 12 year

In Our study there was 28 feet with male were predominant. Majority of patients were below 8 year (range 3-12 years). Unilateral feet were 14 and bilateral feet were 7.

We used dimeglio scoring system for clinical assessment of deformities of club foot [6]. In the illizarov group average preoperative score was 14.3 and post operative score was 2.81 whereas in jess group average preoperative score was 13 and postoperative score 4.2 .

In S Suresh, A Ahmed et. al. - 1999 there were 45% Neglected, 55% Recurrent / Relapsed type, with an average follows up of 2.2 to 3.9 years.

In Oganesian and Istomina- 1991 there were 70 feet treated by Hinged distraction device, average fixator period was 16 weeks with follow up ranging from 1-9 years.

In our study there were more of neglected type feet, compared to recurrent/relapsed feet (25 v/s 3). The average fixator period was 12.86 weeks in Illizarov group and 11.76 weeks in jess group. The average follow was 15-16 month (range 1 -2.5 years).

Radiological assessment was done using talocalcaneal angle in AP, Lateral view and Talo –Calcaneal index. Average Talocalcaneal angle and talocalcaneal index was better improved in illizarov compare to jess[1,3,4].

In S Suresh, A Ahmed et. al. – 1999 of 44 feet treated by Jess there were 12 (27.3%) pin tract infections, 2 (4.5%) skin necrosis, 6 (13.6%) pin loosening, there was 1(2.2%) feet with flexion contractures of the toes and the fixator was removed I (4%) because of pin loosening.

In our study temporary edema developed in 2 feet in illizarov and 4 feet in jess due to insertion of K wire in metatarsal. It subsided after elevating the feet and stopping the distraction. This complication was more in jess compare to illizarov.

Clawing of toe developed in 4 feet (26 %)in illizarov group and 6 feet in jess -group due to shortened and stretching of flexor during the distraction despite foot plate and elastic rubber sling. passive mobilization were advised to patient for correction of clawing .After the removal of fractional distraction clawing of toe decreased and at the last follow up it was absent or slight visible. But its complication was more common in jess compare to illizarov.

Pin tract infections were noted in 5 (32.14 %) feet in illizarov and in 4 feet (30.7 %) in jess group. Pin tract infections were more in illizarov compared to jess group .In most of patients it subsided with dressing, oral antibiotics and tighten of loose screw and link joint.

Loosening of fixator noted in 3 (20%) feet in illizarov and 9 feet (69%) in jess, and jamming of distracter occurs in 6(21.42%) feet in jess. Both of these complications were more in jess compared to illizarov.

Linear skin necrosis developed in 2 (7.14 %) feet and epiphyseal separation of distal tibia was noted in 1 foot (7%) treated by illizarov. both of these complication were not found in jess.

Three long term complication such as recurrence of forefoot adduction noted in 2 feet in illizarov and 3 feet in jess. During follow up flat foot were noted in 1 feet in illizarov and persistence of great toe adduction were noted in 1 feet in jess group.

In C. F. Bradish et. al.- 1999 treated by Ilizarov device there were 47% excellent,29.4% good, 11.7% fair and 11.7% poor results.

Amin Abdel –Razek Youssef Ahmed-2010 included 18 feet 72.2 % were satisfactory (2 excellent and 11 good while 27.8 % were unsatisfactory (4 fair and 1 poor).

Asadullah Makhdoom, Ahmed siddiqui 2012 included 27 feet 3 excellent, good 17, fair 5and poor 2.

In our study 15 feet treated by Illizarov, 4 (27%) were excellent, 6 (40%) Were good, 2(13%) were fair and 3(20%) were poor results.

Anwar and Arun -1999 24 feet treated by jess excellent and good result in 59.7 % Of cases.

In s suresh, A Ahmed et. al. -1999 of 44 feet age 0.8 -6 year treated by jess there were (77%) excellent, (13%) Were good, o fair and 9% were poor results.

In our study 13 feet treated by Jess, 2(15%) were excellent, 3 (23%) were Good, 3 (23%) were fair and 5(39%) were poor result.

VII. Conclusion

We concluded for better comparison of functional outcome of illizarov ring fixator and jess required long term study, follow up and similar identical group (such as type and grade of deformity ,age).

In our short term study, we concluded that outcome of illizarov ring fixator were better than jess in patients having moderate to severe deformity, more advanced age group and educated parents. jess is better than illizarov ring fixator in Patients having small feet with early age group ,less severe deformity and illiterate parents because , illizarov ring fixator is technically more demanding procedure and more bulky to use in small feet.

Reference:

- [1]. Jason A. Freedman, Hugh Watts, and Norman Y. Otsuka , The Ilizarov Method for the Treatment of Resistant Clubfoot: Is It an Effective Solution J Pediatric Orthop 2006; 26:432-437 .
- [2]. Wael Yousif El-Adly · Khaled M. Mostafa .Ilizarov external fixator in treatment of severe recurrent congenital talipes equinovarus deformity Eur J Orthop Surg Traumatol (2009) 19:565–570.
- [3]. C. F. Bradish, S. Noor.The Ilizarov method in the management of relapsed club feet J Bone Joint Surg [Br] 2000;82-B:387-91.
- [4]. M. CN .Joshi's External Stabilization System (JESS) Application For Correction Of Resistant Club-Foot. The Internet Journal of Orthopaedic Surgery. 2010: 18 10.5580/1408.
- [5]. Sujit Kumar Tripathy ,ragav saini ,pebam sudes ,mandeep singh Dhillon ,shivinder singh gill et al. Application of the Ponseti principle for deformity correction in neglected and relapsed clubfoot using the Ilizarov fixator . J Pediatr Orthop 2011 B 20:26–32
- [6]. Ajai Singh , Evaluation of Neglected Idiopathic CtevManaged byLigamentotaxis Using Jess: A Long-TermFollowupSAGE-Hindawi Access to ResearchAdvances in Orthopedics 2011 :218489 ,6
- [7]. Grill F and Franke J . The Ilizarov distracter for the correction of relapsed or neglected clubfoot. JBJS 1987 69-b 593 .
- [8]. Grant AD, Atar D, Lehman WB. The Ilizrov technique in correction of complex foot deformities. Clin Orthop 1992; 280:94-103.
- [9]. Bassett GS, Morris JR. The use of the Ilizarov technique in the correction of lower extremity – deformities in children. Orthopedics 1992-280:72-80.
- [10]. Galante VN, Molfetta L, Simone C. The treatment of club foot with external fixation: a review of results – Current Orthopaedics 1995; 9