

## **Silicon Implant in Middle Ear Reconstruction**

Dr. Rahul kawatra<sup>1</sup>, Dr. Puneet Maheshwari<sup>2</sup>, Dr. Shikhar Saxena<sup>3</sup>

<sup>1</sup>*Head of Department of otorhinolaryngology, Era's Lucknow Medical College and Hospital/  
Dr RML Avadh University Faizabad, India)*

<sup>2</sup>*(Senior resident, Department of otorhinolaryngology, Era's Lucknow Medical College and Hospital/  
Dr RML Avadh University Faizabad, India)*

<sup>3</sup>*(Junior resident 2<sup>nd</sup> year, Department of otorhinolaryngology, Era's Lucknow Medical College and Hospital/  
DrRML Avadh University Faizabad, India)*

### **I. Introduction**

Chronic Suppurative Otitis Media (CSOM) is a very common disease affecting mainly the younger population. Various factors like socioeconomic condition, over-crowding, lack of concern about hygiene, poverty, illiteracy etc. contribute much towards the occurrence of this disease.

The audiological impairment is very distressing to the patients even if recurrent otorrhoea ceases. To improve upon the hearing and to check the recurrence, tympanoplasty surgery came into existence.

Ossiculoplasty is defined as the reconstruction of the ossicular chain. The ideal prosthesis for ossicular reconstruction should be biocompatible, stable, safe, easily insertable, and capable of yielding optimal sound transmission.

Although, autologous and biomaterial implants, both are in practice, yet it is always of interest to find out innovative use of materials other than those being conventionally used. In present study, silicon implants were used. Silicon implants have been successfully used in rhinoplasty[1,2]. The prospects of silicon implants in jaw surgery and innovative areas has been proposed as long back as 1963[3].

Use of silicon implants in ossiculoplasty is rarely reported despite their enormous prospects[4]. The present study is an attempt to evaluate the feasibility, increase in hearing sensitivity, extrusion rate and cost effectiveness of silicon implants in middle ear reconstruction surgeries.

### **II. Aim Of The Study**

To evaluate the efficacy of Silicon implants for ossiculoplasty in terms of increase in hearing sensitivity , extrusion rate and cost effectiveness.

### **III. Methods**

#### **3.1 Study design and Setting**

In this Randomized prospective crossover study , 80 patients of chronic suppurative otitis media (CSOM) with conductive hearing loss and ossicular chain discontinuity were operated for middle ear reconstruction. This study was conducted after clearance from the registered ethical committee. Patients were properly informed regarding the nature of the disease process, the proposed surgical procedure including expected outcomes, potential complications, and alternative treatments. Written consent was signed by patient and attendant both.

#### **3.2 Study period**

The duration of the study was 46 months between May 2010 to March 2014 with 24 months follow-up period for every case[5].

#### **3.3 Sample size**

Eighty patients from outpatient department of ENT.

### **IV. Procedure**

All cases of chronic otitis media with conductive hearing loss, with suspected ossicular chain discontinuity, (after diagnosing by Pure tone audiometry and otomicroscopy), were taken up for surgery. In all cases of ossicular discontinuity, ossiculoplasty was done by silicon.

#### **4.1 Reshaping of silicon**

From the silicon block, with a surgical blade, reshaping was done as per the defect (Fig.i).

#### 4.1.1 Partial silicon replacement implant

Necrosed ossicles were removed and the defect present was measured, accordingly a cuboidal shaped piece of silicon is sculptured from the block, at the centre a hole is created, to fix it over the stapes head and touching the handle of malleus (Fig.ii,iii).

#### 4.1.2 Total silicon replacement implant

It has two parts, the shaft and head. The lower part of shaft fits over the stapes foot plate while over the head rests the tympanic membrane, with an interposed sliced cartilage to avoid direct contact with temporalis fascia graft (Fig.iv).

After placing the implant, a thin strip of conchal cartilage is freshened with the use of cartilage slicer (From Kalelker Surgicals, model no. 27.Q01.3S) (Fig.v) of varying thickness ranging from 0.1 to 0.3 mm and is placed over the implant to lower the extrusion rate.

All cases were performed using a post aural approach and standard technique of ossiculoplasty. After the surgery, every patient was followed for next 24 months.

Pre-operatively all patients had a pure tone audiogram calculated for both air conduction and bone conduction. Post-operatively, pure tone audiograms were performed at 1st, 2nd, 4th, 6th, 12<sup>th</sup>, 18<sup>th</sup> and finally at 24<sup>th</sup> months follow-up.

Hearing results were assessed by comparing pre-operative and post-operative pure tone averages as well as closure of the air-bone gap. Extrusion rates and complications were also assessed till 24 months of follow up.

### V. Inclusion Criteria

1. Cases of chronic otitis media Inactive mucosal disease with pure conductive hearing loss.
2. Both males and females in the age group of 10-55 years were included in the study.

### VI. Exclusion Criteria

1. Patient with sensorineural hearing loss.
2. Chronic suppurative otitis media squamosal disease with or without complications.
3. Patients below 10 years and above 55 years were excluded from the study.
4. Discharging ear, previous history of ear surgery, otitis externa.
5. Comorbid systemic diseases like hypertension, diabetes, or any chronic infection were excluded from study.

### VII. Statistical Tools Employed

The following Statistical formulas were used to analyse the data:

#### 7.1 Mean

To obtain the mean, the individual observations were first added together and then divided by the number of observation.

#### 7.2 Standard Deviation

It is denoted by the Greek letter  $\sigma$ . If a sample is more than 30 then:

$$\sigma = \sqrt{\frac{\Sigma(X - \bar{X})^2}{n}}$$

#### 7.3 Chi square test:

$$\chi^2 = \frac{\Sigma(O - E)^2}{E}$$

Where O = Observed frequency, E = Expected frequency

#### 7.4 Student 't' test

To test the significance of two means the student 't' test was used.

### VIII. Results

#### 8.1 Mean hearing gain (closure in A-B gap)

It was calculated to be 19.50±7.98 dB after 24 months followup in 80 silicon middle ear implants. (Table I)

Table I: Post-Operative Closure in Air-Bone (A-B) Gap

SN	Change in A-B Gap	(n=80) Silicon	
		No.	%
1.	≤ 10 dB	8	10
2.	11-20 dB	40	50
3.	21-30 dB	32	40
4.	>30 dB	0	0
Mean Change in Gap±SD		19.50±7.98	

According to Table I, majority of subjects had a A-B gap reduction within 11-20 dB dB

### 8.2 Hearing Success Rate

It indicates, total no. of patients, whose postoperative AB Gap calculated by an audiogram at 24 months of follow-up, is equal to or less than 20 dB.

In the present study the overall hearing success rate at follow up period of 24 months is 80%.

### 8.3 Extrusion Rate (Table II)

The implant was extruded in 3 cases postoperatively with in 24 months of follow up. (3.75%)

Table II: Acceptability of Implant

SN	Status	(n=80) Silicon	
		No.	%
1.	Accepted	77	96.25
2.	Extruded	3	3.75

## IX. Discussion

Chronic suppurative otitis media often ends up in the breach in conductive chain of the middle ear leading to conductive deafness. The breach in ossicles calls for rehabilitation of patient through ossicular prosthesis. Thus ossiculoplasty is the surgical treatment. It has been over 50 years since the use of implants have been started in the ossiculoplasty[6].

A middle ear implant must be biocompatible, readily available, technically easy to use and it should give the best possible hearing results[7]. Two general classes of prosthesis are in use today: autologous implants and biomaterials[8]. Autologous implant includes ossicles (incus, malleus), cartilages (septal, tragal) and cortical-bone. Advantages of autograft prostheses includes very low extrusion rate, no risk of transmitting disease and biocompatibility. Displacement, size, and possibility of harboring microbes have been cited as potential disadvantages to their use[9]. Thus, biomaterials may be considered as an option. Biomaterial prostheses have some advantages over autologous implants. They are commercially supplied in a well-trimmed and sterilized condition and there is no possibility of transferring a retro-virus infection inherent in an autograft. Disadvantages are the possible incidence of inflammation and extrusion due to a foreign-body reaction[10].

A number of biomaterials are in use for ossiculoplasty like vinyl-acryl, polyethylene[11], PTFE/Teflon[12] Stainless steel[13], Proplast[14], Plastipore, Aluminium oxide ceramic, Ceravital[15], Hydroxyapatite, Bioglass[16], Carbon[17], Silicon and have shown comparable results with autografts. The extrusion rate in these materials is as low as 1.3% to 6%[18].

In the present study, silicon was used as middle ear implant and its efficacy was evaluated in terms of increase in hearing sensitivity, extrusion rate and cost effectiveness.

The results obtained from silicon prosthesis were comparable not only to other biomaterials but they were also as good as autologous implants. The success rate for silicon prosthesis was 80%. The overall extrusion rate was 3.75%. This depicts that silicon can be used as substitutes and are equally bioacceptable and provide similar functional results compared to other commonly used implant materials.

As far as cost factor is considered, the autologous implants cost nothing, while the cost of biomaterials like Teflon, gold, titanium etc are much higher as compared to silicon, which is almost negligible. Considering the relatively comparable success rates of silicon it may be an option to be tried in order to provide an affordable implant to the patients.

## X. Conclusion

The status of the tympanic membrane and middle ear has a significant influence on the prognosis of hearing outcomes in ossiculoplasty. The rate of extrusion depends on several factors, the most important of which is the status of the middle ear, eustachian tube and the implant material.

Various materials have been developed in an attempt to maximize prosthetic biocompatibility and ease of use, while minimizing the chance of extrusion. In addition to biocompatibility, cost containment issues have influenced the development of affordable ossicular prostheses.


In the present study, a cost effective biomaterial, silicon have been used which is not a new implant material but yet not tried much in the middle ear. It showed promising results in terms of acceptability, hearing improvement, patient satisfaction and the results were comparable to other autologous materials. It is a very promising material which can be reshaped exactly like a cartilage with almost equally good results.

A long-term follow up and a large series of patients in this study, with convincing results, strongly recommends clinical use of silicon in middle ear reconstruction.

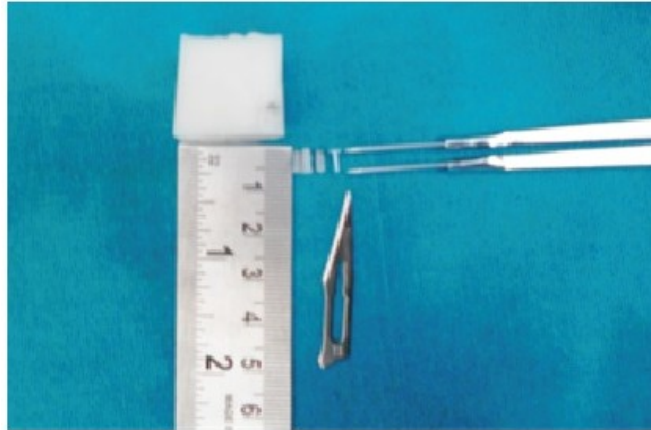
## References

- [1] Ahn J, Honrado C and Hom C, Combined Silicone and Cartilage Implants: Augmentation Rhinoplasty in Asian Patients, Arch Facial Plast Surg, 6(2), 2004, 120-123.
- [2] Lam SM and Kim Y-K, Augmentation rhinoplasty of the Asian nose with the "bird" silicone implant, Ann Plast Surg, 51, 2003, 249-256.
- [3] Brown JB, Fryer MP, Kollias P, Ohlwiler DA and Templeton JB, Silicone and Teflon Prostheses, Including Full Jaw Substitution, Laboratory and Clinical Studies of Ethern. Annals of Surgery, 157(6), 1963, 932-943.
- [4] Gerlinger MD et al. Effect of KTP laser on implants used in middle-ear surgery, The Journal of Laryngology & Otology, 116(7), (2002), 502-506.
- [5] Sismairs A. Tympanoplasty (Glasscock Shambaugh. Surgery of ear. 5th edition; 451).
- [6] Slater PW, Rizer FM, Schuring AG and Lippy WH, Practical use of total and partial ossicular replacement prostheses in ossiculoplasty, Laryngoscope, 107, 1997, 1193-8. 104.
- [7] Menendez-Colino LM, Bernal-Sprekelsen M, Albid I and Traserra-Coderch J, Preliminary functional results of tympanoplasty with titanium prostheses, Otolaryngol Head Neck Surg, 131, 2004, 747-9.
- [8] O'Reilly RC, Cass SP, Hirsch BE, Kamerer DB, Bernat RA and Poznanovic SP, Ossiculoplasty using incus interposition, Hearing results and analysis of the middle ear risk index, Otol Neurotol, 26, 2005, 853-8.
- [9] Kartush JM, Ossicular chain reconstruction. Capitulum to malleus, Otolaryngol Clin North Am 1994, 27, 689-715.
- [10] Shinohara T, Gyo K, Saiki T and Yanagihara N, Ossiculoplasty using hydroxyapatite prostheses, long-term results, Clin. Otolaryngol, 25, 2000, 287±292.
- [11] Shea JJ, Vein graft closure of eardrum perforations, J Otolaryngol, 74, 1960, 358.
- [12] Austin D.F. and Shea J.T, A new system of tympanoplasty using vein grafts, Laryngoscope, 71, 1961, 596-611.
- [13] Palva T, Palva A and Karja J, Ossicular reconstruction in chronic ear surgery, Arch Otolaryngol, 81, 1965, 115-22.
- [14] Shea JJ and Homsy CA, The use of proplast in otologic surgery, Laryngoscope, 84, 1974, 84, 1835.
- [15] Reck R, Bioactive glass ceramic, a new material in tympanoplasty, Laryngoscope, 93, 1983, 196-9.
- [16] Merwin GE, Bioglass middle ear prosthesis, preliminary report, Ann. Otol. Rhinol. Laryngol, 95, 1986, 78-82.
- [17] Podoshin L, Fradis M and Gertner R, Carbon-carbon middle ear prosthesis, A preliminary clinical human trial report, Otolaryngol Head Neck Surg, 99, 1988, 278-81.
- [18] Yung MW, Literature review of alloplastic materials in ossiculoplasty, The Journal of Laryngology & Otology, 117(6), 2003, 431-436.

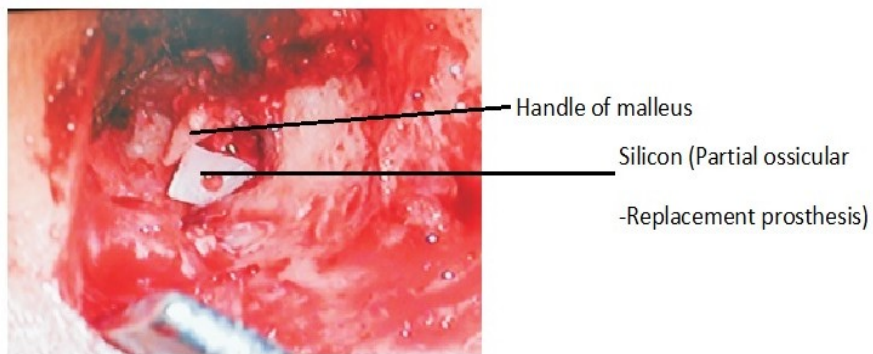
## Figures



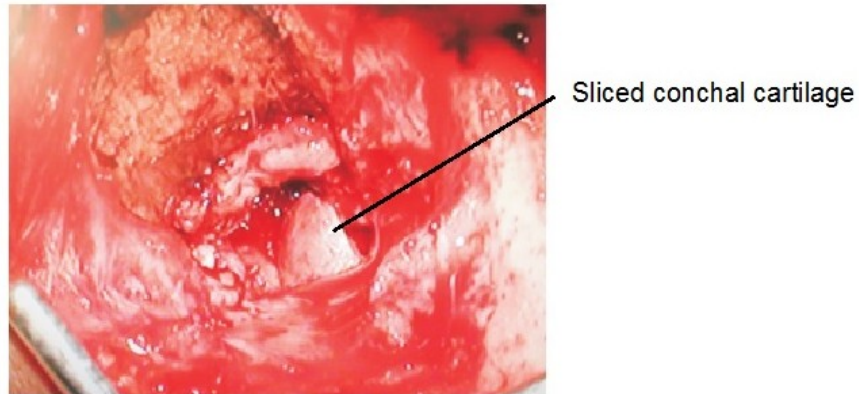
**Fig.i Cartilage Slicer(used for reshaping cartilage and silicon)**



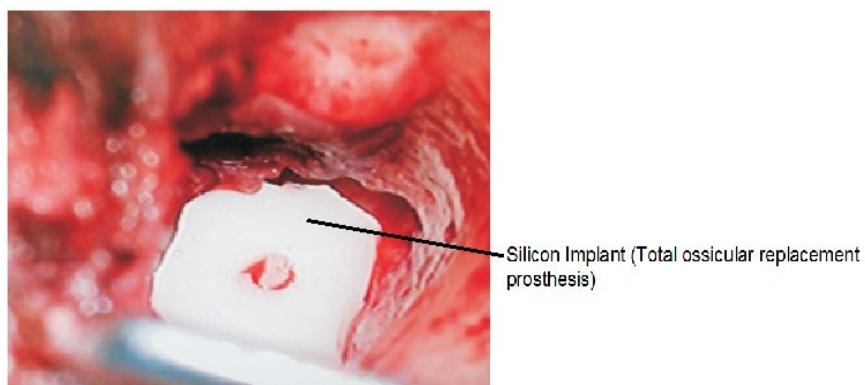
**Fig.ii Silicon Implant being Harvested**



**Fig.iii Silicon partial ossicular replacement prosthesis 6X**



**Fig.iv Cartilage covering the Silicon partial ossicular replacement prosthesis 6X**



**Fig.v Silicon total ossicular replacement prosthesis 10X**