

Diode Lasers for Oral Submucous Fibrosis – An Experimental Study

Dr. Harsha V. Babaji¹, Dr. Anuradha², Dr. Abhishek Nagaraj³,
Dr. Veena G.C⁴

All the authors are affiliated to Rajiv Gandhi University of Health Sciences, Bangalore, Karnataka, INDIA

I. Introduction

Oral submucous fibrosis {OSMF} has been well established in Indian medical literature since the time of Sushruta, a renowned Indian physician who lived in the era 600 B.C and was termed as “Vidari”.¹ This condition was first described in the modern literature by Schwartz in 1953, who coined the term “Atrophica idiopathica mucosa oris”. Joshi subsequently coined the term oral submucous fibrosis for the condition in 1953.² However there are various synonyms proposed by different authors such as “Diffuse oral submucous fibrosis”, “Idiopathic scleroderma of the mouth”, “Idiopathic palatal fibrosis”, “Sclerosing stomatitis” and “Juxta-epithelial fibrosis”.³ Pindborg (1966) defined oral submucous fibrosis as, “An insidious, chronic disease affecting any part of the oral cavity and sometimes the pharynx. Although occasionally preceded by and/or associated with vesicle formation, it is always associated with juxta-epithelial inflammatory reaction followed by fibroelastic change of the lamina propria, with epithelial atrophy leading to stiffness of the oral mucosa and causing trismus and inability to eat”.³

Geographically, OSMF has a specific distribution and affects predominantly Asians (and particularly Indians) from the southern states, and Taiwanese.^{4,5} Global estimation indicates 2.5 million to 5 million people in India are affected by OSMF from 1996 to 2002 respectively,⁶ with male to female ratio being 2.36:1.⁷ Epidemiological data and intervention studies suggest that areca nut is the main aetiological factor for OSMF. Other etiological factors are chillies, lime, tobacco, nutritional deficiencies such as iron and zinc, immunological disorders, and collagen disorders.⁸

The possible precancerous nature of OSMF was first described by Paymaster,⁹ who observed the onset of slow-growing squamous cell carcinoma in one third of such patients. Studies showed malignant transformation rate of 2.3% in 10 years,⁸ 4.5% in 15 years¹⁰ and 7.6% in 17 years¹¹ during follow up period.

Various treatment modalities are followed in treating this condition which includes medical and surgical. Medical management is indicated in the initial stages of OSMF, with mouth opening more than 25 mm. Intralesional injections of steroids, gamma interferon, hyaluronidase, placental extracts, triamcinolone and chymotrypsin are tried with varying results.

In the modern era, the use of laser to release fibrotic bands leads to healing with minimal scarring, thereby decreasing the probability of procedure induced trismus. Laser is also associated with early wound healing. The other advantages of using laser include spontaneous occlusion of small, transected vessels, providing good haemostasis. The laser also assists the surgeon in making precise incisions with minimal collateral damage.

Diode laser is a portable device which delivers rays through a fiber-optic cable and hence can be delivered to relatively “difficult-to-access” areas. Its cutting depth is less than 0.01 mm, and thus preserves tissues beyond this depth. It gives a precise line of controlled cutting without damaging the muscles and deeper structures. Hence, laser therapy eliminates the use of grafts, to close the defect in spite of extensive resection. It yields excellent functional results.¹⁵

In this study we would like to evaluate 50 cases of OSMF where diode laser will be used to release fibrotic bands and its influence on maintaining adequate mouth opening which is evaluated pre operatively, immediate post operatively, at 10th day, 3 months and 6 months.

II. Method

A total of 50 cases with OSMF were undertaken for the study. All the procedures were carried out under local anesthesia.

III. Procedure

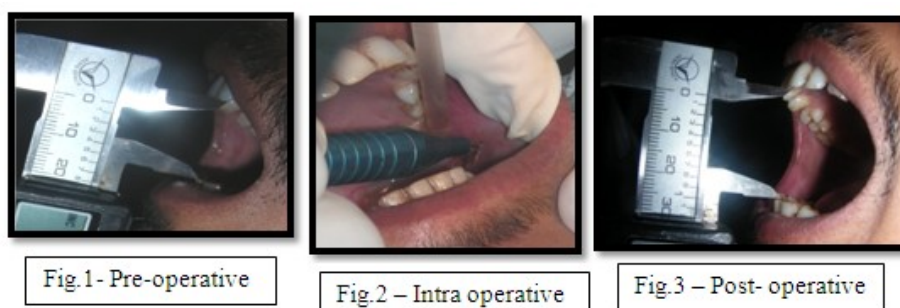Under strict aseptic precaution, operation was carried out in dark room. Protective eyewear was worn by the entire operating team and the patient. A 600 micrometer diameter fibre optic cable was used for delivery

of the beam. Straight handpiece was used to place the incision at the desired site. Only plastic and wooden instruments were used in the surgery.

2% local anesthesia with adrenaline 1: 80,000 dilution, infiltrated bilaterally all over buccal mucosa. 'Y' shaped incision with 2 limbs facing anteriorly were made from the retromolar area extending up to the premolar region or angle of mouth. The incision was made approximately 2 mm deep until the muscle layer was reached, incising only the fibrous mucosa and submucosal layer using Diode Laser at 6watts in continuous mode along the buccal mucosa at the level of occlusal plane away from Stenson's duct orifice. After resection of fibrous bands, the mucosa was further freed by finger dissection and undermining was done by blunt dissection until no resistance was felt. The procedure was repeated on the other side, and the mouth was then forced open (intraoperatively) with Hister's mouthgag. Mouth opening was measured immediately post operatively from the incisal edges of the maxillary and mandibular central incisors and recorded. Hemostasis achieved. Patients were discharged.

All patients received antibiotics for 5 days, and multivitamin and antioxidants for 6 months post operatively.

Patients were started on mouth opening exercises (using wooden sticks) from the 1st postoperative day, with a frequency of four times a day with duration of half an hour, and later the frequency and duration was increased to facilitate improvement in the mouth opening until adequate values were achieved. Patients were evaluated for mouth opening at 10th day, 3 months and 6 months respectively.

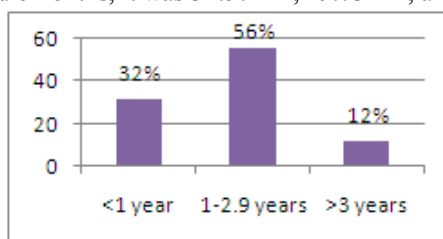


IV. Results

A prospective clinical study was conducted on 50 patients who were diagnosed with oral submucous fibrosis based on clinical and histopathological reports. Out of 50 patients, 49 were male and 1 female who enrolled, aged from 15-40 year. The disease was more common in 2nd decade of life. Out of 50 patients, 88 % (n=44) were addicted to gutka, 10% (n=5) consumed betel nut and 2% (n=1) had a habit of sweet supari chewing. In our study we observed mean number of times/day tobacco chewing habit was 18. The frequency of tobacco chewing habit ranged from 1-15 years, mean was 8 year . Patients gave history of burning sensation of mouth ranging from 1- 8.9 years with mean of 5 year . Majority of patients, 56 % (n=28) experienced trismus from 1-2.9 years. All 50 patients under went resection of fibrous bands using diode laser under local anesthesia and forceful mouth opening was achieved using Histers mouth gag. Mouth opening was documented immediately postoperatively, at 10th day, 3 months and 6 months.

To know the effect of laser treatment on mouth opening in OSMF patients at different time intervals Repeated measures ANOVA was used. Mauchly's test indicated that the assumption of sphericity was violated ($p < 0.05$). Therefore degrees of freedom were corrected using Greenhouse – Geisser estimates of Sphericity ($\epsilon = 0.382$). The results show that there is statistically significant effect of laser treatment on mouth opening in OSMF patients at different time intervals .

Pairwise Comparisons of effect of laser treatment on mouth opening at all time intervals was statistically significant ($p < 0.05$). Mean pre-operative mouth opening was 23.04 mm. After resection of fibrous bands using diode laser, mean immediate post-operative mouth opening was improved to 32.74 mm, which on follow up on 10th day, 3 months and 6months, it was 31.57mm, 29.73mm, and 27.97mm respectively.



Graph 1: Distribution of subjects according to trismus.

Table 1: Test of within subjects effects/ Repeated measures ANOVA.

Time period	N	Mean	Std. Deviation	Estimate of Sphericity test Greenhouse – Geisser
Pre-operative	50	23.04	1.56	
Immediate post-operative	50	32.74	2.64	df – 2.328 F value – 619.750 P value – 0.00
Tenth day	49	31.57	2.56	
Three months	49	29.73	2.68	
Six months	49	27.97	2.80	

Graph 2: Test of within subjects effects/ Repeated measures ANOVA.

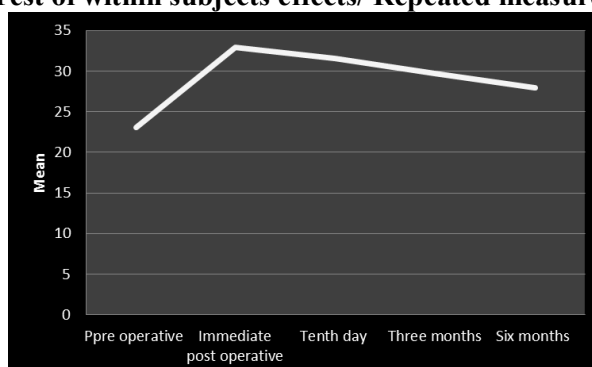


Table 2: Pairwise comparison of mouth opening at different time intervals

Visits	Follow up	Mean Difference	Std. Error	Sig. ^a	95% Confidence Interval for Difference ^a	
					Lower Bound	Upper Bound
Pre op	Post op immediate	-9.796*	.275	.000	-10.605	-8.986
	Tenth day	-8.469*	.284	.000	-9.306	-7.633
	Three months	-6.633*	.276	.000	-7.445	-5.820
	Six months	-4.878*	.278	.000	-5.694	-4.061
Post immediate op	Baseline	9.796*	.275	.000	8.986	10.605
	Tenth day	1.327*	.135	.000	.930	1.723
	Three months	3.163*	.161	.000	2.691	3.636
	Six months	4.918*	.208	.000	4.307	5.530
Tenth day	Baseline	8.469*	.284	.000	7.633	9.306
	Post op immediate	-1.327*	.135	.000	-1.723	-.930
	Three months	1.837*	.121	.000	1.479	2.194
	Six months	3.592*	.206	.000	2.986	4.198
Three months	Baseline	6.633*	.276	.000	5.820	7.445
	Post op immediate	-3.163*	.161	.000	-3.636	-2.691
	Tenth day	-1.837*	.121	.000	-2.194	-1.479
	Six months	1.755*	.122	.000	1.396	2.114
Six months	Baseline	4.878*	.278	.000	4.061	5.694
	Post op immediate	-4.918*	.208	.000	-5.530	-4.307
	Tenth day	-3.592*	.206	.000	-4.198	-2.986
	Three months	-1.755*	.122	.000	-2.114	-1.396

V. Discussion

Oral submucous fibrosis is a chronic, progressive, debilitating disease that was first reported in India in the year 1953.^{2,16} Initially the disease was found only amongst people living in the Indian subcontinent or in Indian migrants. Later, cases were reported from many South-east Asian, and other western countries.¹⁷

Literature survey of gender distribution has shown wide variations in the occurrence of OSMF. Some epidemiological surveys in India have shown a female predominance.^{18,19} In our study, out of 50 OSMF patients, we observed 98% (n=49) were males and 2% (n=1) was female, which was similar to the study conducted by Chaturvedi VN et al²⁰ and Reddy V et al⁷ in India. Male predominance in our study can be due to

easy accessibility for use areca nut and its products more frequently than females in our society and changing lifestyles of the youngsters.

In our study, disease was more common in 2nd decade of life, which was substantiated by the study conducted by Pindborg et al.⁵ The pathogenesis of the disease is thought to be multifactorial. Habitual chewing of gutkha and other areca nut products plays a major role in etiology of this condition.^{2,17}

Areca-nut contains alkaloids, flavonoids, and copper, which all interfere with homeostasis of the extracellular matrix. Four alkaloids – arecoline (most potent), arecaidine, guvacine, and guvacoline – are known to stimulate fibroblasts to produce collagen. Flavonoids (tannins and catechins) inhibit collagenase, stabilise the collagen fibrils, and render them resistant to degradation by collagenase. The localised mucosal inflammation caused by areca-nut or gutkha results in the recruitment of activated T-cells and macrophages that lead to an increase in cytokines and tumour growth factor beta (TGF- B). The latter considerably increases the production of collagen by activating procollagen genes, and upregulating procollagen proteinase enzymes and lysyl oxidase activity. Simultaneously, TGF- B inhibits collagen degradation by activating the tissue inhibitor of matrix metalloproteinase (TIMP) genes and plasminogen activator inhibitor (PAI). The high concentration of copper in areca-nut has been found to stimulate lysyl oxidase activity, an enzyme essential to the final cross-linking of collagen fibres. Increased copper has been seen in mucosa affected by OSMF, which supports its role in fibrogenesis by enhancing lysyl oxidase activity.

Continually chewing areca-nut leads to increased activity of the masticatory muscles, depletion of glycogen, and muscle fatigue. The reduced blood supply following fibrosis further promotes muscle fatigue and causes extensive degeneration and fibrosis in the muscles.²¹

In our series, all the patients gave a positive history of chewing some form of betel nut or tobacco or a combination. 88% (n=44) of patients had habit of chewing gutkha, 10% (n=5) with betel nut and 2% with sweet supari chewing habit. When compared to gutkha with betel nut and sweet supari users, gutkha users showed a significantly increased severity of OSMF. The reason attributes to the fact that the commercially available products are concentrated, freeze dried and have higher dry weight concentration of tobacco, areca nut, and slaked lime to the traditionally prepared home made products like panmasala.^{19,22,23} Another factor supporting this could be the antioxidant capabilities of pan leaf which is known to be rich in beta-carotene, which has the capacity to quench free radicals that are mutagenic which counteracts the different pathology causing irritants.²⁴ In our study, as the duration of consuming habits increased above 3 years and frequency of habit of consuming for more than 5 times per day resulted in increased burning sensation of mouth and restricted mouth opening. A similar results were found by Tilakaratne et al(2004).²⁵

Diagnostic criteria of OSMF are burning sensation of mouth, formation of vesicles/ulcers, dryness of mouth, alteration in taste, blanching, and stiffness of oral mucosa. Palpable fibrotic bands running vertically in the cheek and circumferentially in the lips, limited function of the soft palate, shrunken and bud like uvula, restricted tongue movements are all seen in advanced cases.²² Majority of these diagnostic features were observed in all our patients with varying severity.

In the modern era, the use of laser to release fibrotic bands leads to healing with minimal scarring, thereby decreasing the probability of procedure induced trismus. The word “**Laser**” is an acronym for **L**ight **A**mplification by **S**timulated **E**mission of **R**adiation. Laser is a device that produces an intense beam by amplifying light.

Unlike other light sources, lasers emit coherent, monochromatic, and collimated electromagnetic radiation, with high intensity, displaying a high optical power per unit area for a given amount of energy as compared to broadband light sources. These characteristics endow the laser with unique applications.

The most common surgical lasers emit wavelengths in the infrared (IR) part of the spectrum: the Nd:YAG ($\lambda=1,064\text{nm}$), the Er:YAG ($\lambda=2.94\mu\text{m}$), and the CO₂ laser ($\lambda=10.6$ and $9.6\mu\text{m}$). Within the visible portion of the electromagnetic spectrum, argon lasers emit light between 458 and 515nm, and excimer lasers are located in the ultraviolet part of the spectrum (100 to 400nm). Diode lasers emit wavelengths of 670 to 1551nm. Infrared light is absorbed primarily by water, while visible and ultraviolet light are primarily absorbed by hemoglobin and melanin, respectively.

Lasers within the ultraviolet region (100 to 380nm) are able to ionize tissues, a process known as photochemical desorption. Lasers of longer wavelengths, especially those within the infrared part of the spectrum (700 to 10,000nm), cause significant tissue heating. Most of the surgical lasers are embedded in this group and comprise thermal lasers. The light of these lasers is rapidly converted to thermal energy causing denaturation of proteins, decomposition of tissue, microexplosion of cell water and charring.

Diode lasers have a diversity of applications in the medical field. These devices are compact and portable in design. The active material used is a semi-conducting crystal, usually gallium arsenide (GaAs) or similar compounds. Blood vessels smaller than 0.5mm in diameter are sealed spontaneously, allowing excellent visibility and precision when dissecting through the tissue planes. There is minimal cellular damage adjacent to the plane of excision. This facilitates good wound healing, even large laser wounds heal with good functional

results and minimal scar. The laser energy is transmitted through an optical fibre delivery system to access the difficult areas in case of OSMF. Its cutting depth is less than 0.01 mm, and thus preserves tissues beyond this depth. It gives a precise line of controlled cutting without damaging the muscles and deeper structures. There is minimal damage to adjacent tissue and a coagulum of denatured protein forms on the surface, hence no dressing is required, and the lasered area can be left exposed in the mouth. Skin grafting is not necessary, even for large areas. Denatured protein acts as a dressing layer for the treatment site that may decrease pain and enhances less risk of secondary infection.

Our study included patients with mean pre operative mouth opening of 23.04 mm.

Resection of fibrous bands using diode laser under local anesthesia was carried out in all 50 patients. Intra-operatively very minimal bleeding was seen. Surgical procedure was well tolerated by the patients. Complications like damage to facial vessels, and parotid duct were not encountered in any of the 50 patients. Out of 50 patients, 1 patient lost the follow up.

Post operatively patients were evaluated for mouth opening at different intervals i.e, immediate post operative, after 10 days, 3 months, and 6 months respectively. Intra-oral defect healed uneventfully in all 49 patients.

Mean mouth opening achieved immediate post operatively was 32.74 mm, and on 10th day, it was 31.57mm. On 3 months follow up, mouth opening was reduced to 29.73mm, on 6 months follow up, it was further reduced to 27.97 mm. This gradual decrease in mouth opening can be attributed to fibrosis of the tissue while healing and irregular physiotherapy post operatively. The mean increase in mouth opening achieved at the end of 6 months was 4.77mm.

These data shows, even though there is acceptable increase in mouth opening through conservative approach using diode laser in OSMF patients, patient's compliance plays an important role in its maintenance. For this reason, psychological preparation for the patient before surgery plays a significant role in the success of surgery.

“Although laser excision is not a panacea for oral submucous fibrosis, it is a simple surgical procedure with effective results in the management of this disease. A more extensive study involving a greater number of cases and including more parameters is necessary to come to final conclusion about this surgical technique and to evaluate the efficacy of lasers in the surgical management of oral submucous fibrosis”.

References

- [1]. Schwartz J. Atrophia idiopathica (tropical) mucosa oris. Demonstrated at the 11th International Dental Congress, London 1953.
- [2]. Joshi SG. Submucous fibrosis of the palate and pillars. *Indian J Otolaryngol* 1953; 4:1-4.
- [3]. Pindborg JJ, Sirsat SM. Oral submucous fibrosis. *Oral surg Oral med Oral pathol* 1966 Dec; 22(6):764-779.
- [4]. Rajendran R. Oral submucous fibrosis: etiology, pathogenesis, and future research. *Bulletin of the World Health Organization* 1994; 72(6):985-96.
- [5]. Pindborg JJ, Chawla TN, Srivastava AN, Gupta D, Mehrotra ML. Clinical aspects of oral submucous fibrosis. *Acta Odontologica Scandinavica* 1964 Dec; 22:679-91.
- [6]. Chiu CJ, Chang ML, Chiang CP, Hahn LJ, Hsieh LL, Chen CJ. Interaction of collagen-related genes and susceptibility to betel quid-induced oral submucous fibrosis. *Cancer Epidemiol Biomarkers Prev*. 2002 Jul; 11(7): 646-53.
- [7]. Reddy V, Wanjar PV, Banda NR, Reddy P. Oral Submucous Fibrosis: Correlation of Clinical Grading to various habit factors. *International Journal of Dental Clinics* 2011; 3(1): 21-24.
- [8]. Gupta MK, Mhaske S, Ragavendra R, Imtiyaz. Oral submucous fibrosis - Current Concepts in Etiopathogenesis. *People's Journal of Scientific Research* 2008;1:39-44.
- [9]. Paymaster JC. Cancer of the buccal mucosa; a clinical study of 650 cases in Indian patients. *Cancer* 1965 May-Jun;9(3):431-5.
- [10]. Pindborg JJ, Murti PR, Bhonsle RB, Gupta PC, Daftary DK, Mehta FS. Oral submucous fibrosis as a precancerous condition. *Scand J Dent Res*. 1984 Jun; 92(3):224-9.
- [11]. Murti PR, Bhonsle RB, Pindborg JJ, Daftary DK, Gupta PC, Mehta FS. Malignant transformation rate in oral submucous fibrosis over a 17-year period. *Community Dent Oral Epidemiol*. 1985 Dec; 13(6):340-1.
- [12]. Nayak DR, Mahesh SG, Aggarwal D, Pavithran P, Pujary K, Pillai S. Role of KTP-532 laser in management of oral submucous fibrosis. *The Journal of Laryngology & Otology* 2009 Apr; 123(4):418-421.
- [13]. Wei FC, Chang YM, Kildal M, Tsang WS, Chen HC. Bilateral small radial forearm flaps for reconstruction of buccal mucosa after surgical release of submucosal fibrosis: a new reliable approach. *Plast Reconstr Surg*. 2001 Jun; 107(7):1679-83.
- [14]. Kameshwaran M, Raghavan D, Anand Kumar RS, Murali S. Surgical management of trismus due to oral Submucous fibrosis - Lysis of fibrotic bands with the KTP-532 laser. *Indian Journal of Otolaryngology and Head and Neck Surgery* 2006 Jul; 58(3): 229-31.
- [15]. Ossoff RH, Coleman JA, Courey MS, Duncavage JA, Werkhaven JA, Reinisch L. Clinical application of laser in otolaryngology – head and neck surg. *Laser in Surgery and Medicine* 1994; 15(3):217-48.
- [16]. Lal D. Diffuse oral submucous fibrosis. *J All India Dent Assoc*. 1953;26:1-3.
- [17]. Gupta PC, Sinor PN, Bhonsle RB, Pawar VS, Mehta HC. Oral submucous fibrosis in India: A new epidemic? *The National Medical Journal of India* 1998;11(3):113-116.
- [18]. Sinor P, Gupta P, Murti P, Bhonsle R, Daftary D, Mehta F, Pindborg J. A case control study of oral submucous fibrosis with special reference to the etiologic role of areca nut. *Journal of Oral Pathology & Medicine* 1990;19(2):94-8.
- [19]. Murti P, Gupta P, Bhonsle R, Daftary D, Mehta F, Pindborg J. Effect on the incidence of oral submucous fibrosis of intervention in the areca nut chewing habit. *Journal of Oral Pathology & Medicine* 1990;19(2):99-100.
- [20]. Chatuvedi V, Sharma A, Chakrabarati S. Salivary coagulopathy and humoral response in oral submucous fibrosis (OSMF). *Journal of the Indian Dental Association* 1991;62(3):51-9.

- [21]. Arakeri G, Brennan PA. Oral submucous fibrosis: an overview of the aetiology, pathogenesis, classification, and principles of management. *Br J Oral Maxillofac Surg.* 2013 Oct;51(7):587-93.
- [22]. Canniff JP, Harris M. Oral submucous fibrosis: Its pathogenesis and management. *Br Dent J.* 1986; 160:429–34.
- [23]. Babu S, Bhat RV, Kumar PU, Sesikaran B, Rao KV, Aruna P, Reddy PR. A comparative clinico-pathological study of oral submucous fibrosis in habitual chewers of pan masala and betelquid. *J Toxicol Clin Toxicol.* 1996;34:317-22.
- [24]. Stich H, Mathew B, Sankaranarayanan R, Nair MK. Remission of oral precancerous lesions of tobacco/areca nut chewers following administration of beta-carotene or vitamin A, and maintenance of the protective effect. *Cancer Detection and Prevention* 1991;15(2):93-8.
- [25]. Tilakaratne W, Klinikowski M, Saku T, Peters T, Warnakulasuriya S. Oral submucous fibrosis: review on aetiology and pathogenesis. *Oral Oncology* 2006;42(6):561-8.