

Osteoma: A Rare Case Report

Dr. Deepak R. Kolte¹, Dr. Vipin Thakkar², Dr. Nitin S. Solanki³

^{1,2,3}(Dept of Oral & Maxillofacial Surgery, Bharati Vidyapeeth Deemed University Dental College and Hospital, Navi Mumbai, India)

Abstract: Osteomas are benign, osteogenic lesions that may arise from proliferation of cancellous (trabeculae), compact bone (dense lamellae) or can be composed by a combination of both¹. There are three different types of osteomas: central, peripheral and extra-skeletal. The central osteoma arises from the endosteum, the peripheral osteoma from the periosteum and the extra-skeletal soft tissue osteoma usually develops within the muscle¹. In the facial bones, both central and peripheral osteomas have been described. Peripheral type of osteoma is most common in the lower jaws, which occurs at the surface of the cortical bone and is sessile or pedicled¹. Most of the osteomas occurring in the mandible are dense osteomas, and the cancellous osteoma is comparatively rare. The most interesting clinical feature of osteoid osteoma is an exquisite dull pain produce of a very small lesion never greater than 1cm in diameter severe enough to interfere with patients sleep. It accounts 3% of primary bone tumor, and about 10% of benign tumor. About 80% of osteoid osteoma occurs in long bones, while less than 1% occur in jaw. That makes our case very rare^{2,4}

We report the case of 72 year old women patient with osteoma of right side mandible in relation with mental foramen and nerve

(**Keywords:** Benign lesion, Osteoma, Pain, Radiopacity)

I. Introduction:

Osteoma was described as a distant clinical entity by Jaffe in 1935. Jaffe define osteoid osteoma as 'sui generis' denoting the lesions small, self-limiting in nature. Lichtenstein define osteoid osteoma as a small, oval or roundish tumor like nidus which is composed of osteoid & trabeculae of newly formed bone deposited within a substratum of highly vascularised osteogenic connective tissue^{1,2}

The pathogenesis of peripheral osteoma is unclear. Some investigators consider it as a true neoplasm, while others classify it as a developmental anomaly. Possibility of a reactive mechanism, caused by trauma or infection has also been suggested. Maxillofacial osteoma associated with cutaneous sebaceous cysts, multiple supernumerary teeth and colorectal polyposis is known as Gardner's syndrome^{1,3}

There were characteristic X-ray changes, such as focal rarefaction and reactive bone, which appeared some distance from the lesion. Green et al reviewed the literature and reported the total number of cases of osteoid osteoma of the jaw to be seven, of these four have occurred in the mandible & three in maxilla, we report a rare case of osteoma in the mandible of an old lady.¹

Since osteoma is often detected incidentally on routine radiographic examination, the dentist should be aware of the features of this lesion. It is distinguished from common palatal and mandibular tori and buccal exostosis which are thought to be developmental or reactive

Origin in spite of being similar to osteomas histopathologically hence not believed to be true neoplasm. Osteomas can cause facial deformity, limitation or deviation of the mandible on opening, headache, bone pain, dysphasia or exophthalmos.⁹

II. Case Report:

A 72 year-old lady, reported to the Department of Oral & Maxillofacial Surgery, at Bharati Vidyapeeth Deemed University Dental College, Navi Mumbai with a chief complaint of severe irritating and paroxysmal, neuralgiform pain on the right side of the lower jaw in relation with premolar area. History of premolar extraction 1 year back (Fig 1& 2). On intraoral examination palpably there were no signs of osseous deformity of the mandibular corpus and the mouth mucous membrane was intact. X-ray results (through orthopantomograph) confirmed radiopaque mass measuring 1x1cm located below the mandibular first premolar in relation with mental orifice which correspond to reinforced, sclerotic bone (calcification) (Fig.3&4). It was of diffuse type, with no sharp restriction toward the surrounding bone. From the case history it was established that the first neuralgiform pain had occurred few years earlier, and had intensified over the past 1 year. Pain starts in the area of the mental orifice in the lower jaw and spreads behind towards the auricular region, up to the temporal and frontal region and down towards the neck and mediastinum.

He was also examined by a dentist who recommended tooth extraction. The patient was then examined by us. As all the biochemical and hematological investigations were within normal limits, a provisional diagnosis of osteoma, osteochondroma, and Osteoma of Mandible.

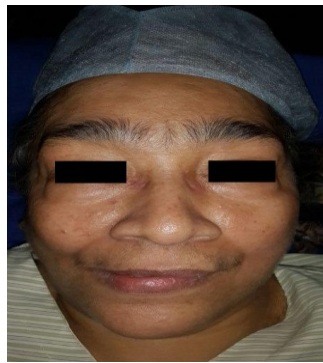

Fig.1 Preoperative photo

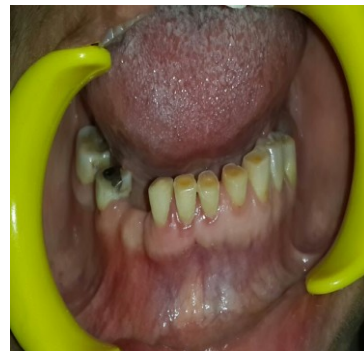

Fig.2. Preoperative intraoral photo

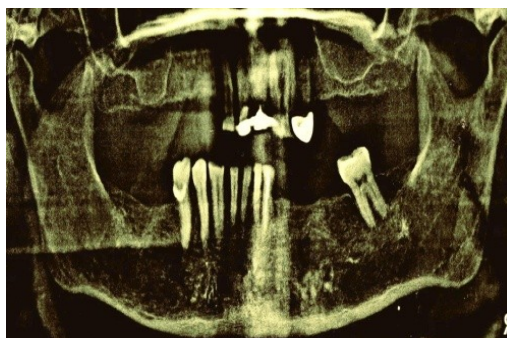


Fig.3 Preoperative OPG

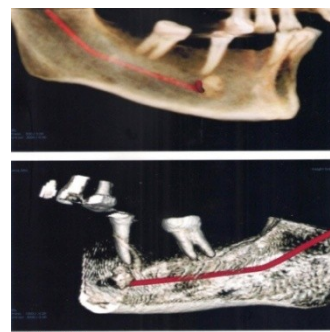


Fig. 4 3D CBCT View

Under General Anesthesia the body mass was approached by making a Crevicular incision, mucoperiosteal flap was reflected the mass was found to be attached to the bone. The mass was separated from bone using bone cutting burs preserving the mental nerve as the lesion is in close proximity with mental nerve. The cortical plate of the body of the mandible was smoothed with a vulcanite bur under copious saline irrigation and the specimen sent for microscopic examination. Post operative recovery was uneventful (Fig.5).

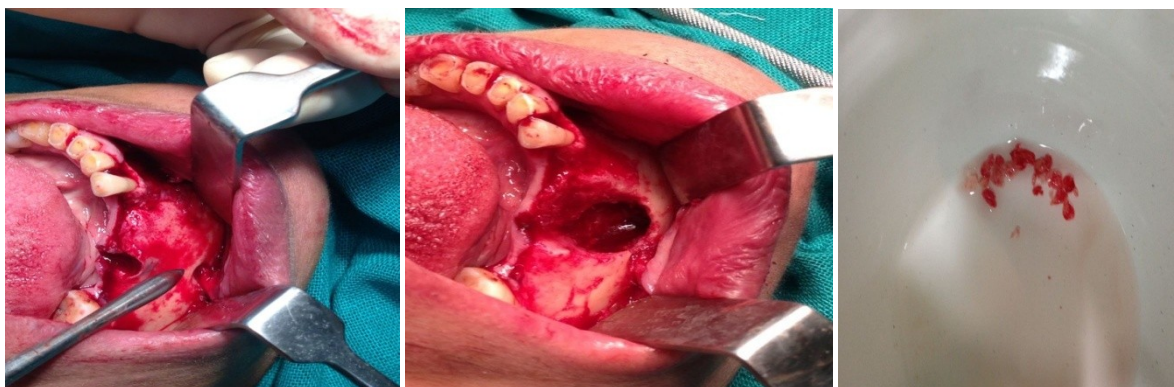


Fig5. Intraoperative

Histopathological reports shows dense compact bone composed of numerous lacunae containing osteocytes resting and reversal lines are seen. Haversian canals and some marrow spaces containing blood elements are also seen. Overall picture suggestive of osteoma (Fig.6). After the procedure, the pain disappeared after a month, but Parasthesia of the lower alveolar nerve lasted for two months, after which sensation returned. A year ago pain intensified to the point intolerability.

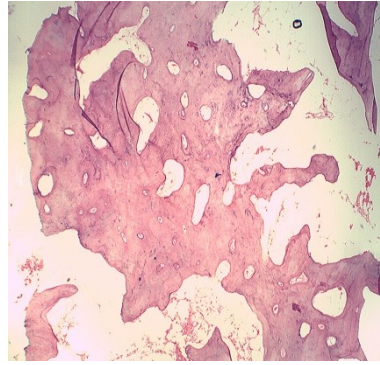


Fig.6. Histopathological picture

On the basis of a clinical examination and X-ray report the diagnosis was: recurrence of osteoma of the lower jaw, central type, which was confirmed by a histopathological report. The surgical procedure was performed in which the tumor tissue was removed with the external decompression of the mental nerve, this resulted in a temporary relief to the patient for a month, but still the pain persisted reducing the pain in localized area of mental foramen after a month inspite of removal of osteoma and decompression of the mental nerve. Then the patient was referred for MRI BRAIN SCAN with the neurophysician consultation. The MRI report shown a well marginated nodular lesion is observed in right cerebellopontial angle. Its shows intermediate signal intensity on T1 weighted images and hypointense signal on T2 weight images subtle to hyperintense foci along dural surface show blooming on gradient echo images and may represent calcification. The lesion displaces adjoining brainstem and abuts cranial nerves. The lesion measures 2.2x 2.2cm. There are few hypertense foci in bilateral coronal radiate on T2 weighted and flair images suggestive of small lacunar infarcts. There is mild prominence on cerebral cortical sulci with ventricular dilation suggestive of diffuse cerebral atrophy.

III. Discussion:

Osteoma is described as a benign neoplasm of bone composed of mature compact or cancellous bone in an endosteal or periosteal location The central osteoma arises from the endosteum, the peripheral osteoma from the periosteum and the extraskeletal soft tissue osteoma usually develops within the muscle. In the maxillofacial area both central and peripheral osteomas have been described. Peripheral osteoma is most common in the lower jaws. The most common site is the frontal sinus, followed by the ethmoidal and maxillary sinus. Peripheral osteomas are more frequent in the mandible than in the maxilla. They most commonly develop in young adults and are benign tumors of bone. Osteomas are usually slow growing, painless solitary mass that is palpable unless it develops within the medullary space Periosteal osteomas clinically appears on the surface of bone as a polypoid or sessile mass, with freely mobile underlying mucosa .Endosteal osteoma are usually asymptomatic and noted on routine radiographs. Males seems to be affected more frequently than females, and children are almost never affected unless they have Gardners syndrome., which is an autosomal dominant triad that features osteomas, fibromatosis of the skin and fascia, and polyposis of large intestine with a high degree of malignant transformation. As reported in our case patient was a young adult with a sessile mass attached to lingual cortical plate of mandible with firmly adherent mucosa.^{1,3}

Osteomas should be distinguished from tori and exostosis which are thought to be developmental or reactive in origin, histopathologically they are found to be similar, hence not believed to be true neoplasm. Tori is also known to develop in the bicuspid area in response to the torsional stress created by heavy mastication. The exact etiology and pathogenesis of peripheral osteoma is unknown. Both hamartomatous and neoplastic factors have been advocated, but no definite conclusion has been reported. Infiltration of interdental bone and abnormal histological bone structure might support the neoplastic nature of this lesion. Developmental, neoplastic and reactive causes have been attributed as possible etiologic factors. It is unlikely that peripheral osteomas are a developmental anomaly, as most cases occur in adults. Some investigators have classified them as a reactive condition triggered by trauma, because peripheral osteomas are generally located on the lower border or buccal aspect of the mandible which are areas susceptible to trauma. But most of the times they are considered as neoplasm. Histologically osteomas consists of mature, lamellar bone or cancellous bone with abundant fibrofatty marrow between bony trabeculae, as reported in our case. Histologically there is no evidence of differentiation between osteoma, osteochondroma, and tori, it can only be differentiated clinically and Radiographically osteoma show as well circumscribed, densely sclerotic and radiopaque mass. Endosteal osteomas are generally identified on routine radiographic examination .Osteomas are diagnosed and treated by local excision. Recurrence of peripheral osteoma after surgical excision is extremely rare. In conclusion, osteomas are slow growing benign tumors with a very rare recurrence rate.^{1,3}

The true nature of the lesion is unknown but some investigators think it is variant of osteoblastoma. Various theories have been given related to nature and genesis of osteoid osteoma. Jaffe had already mentioned considered it is benign tumour. He observed that particularly in the latest stages of development, osteoid osteoma manifests histological pattern of the pronounced neoplastic lesion. Bregstad (1930) thought that the lesion was an embryonal nature and considered it is a hemangioma. Pines et al in 1950 and Lofgren in 1953 described it is an inflammatory lesion as pain which its most common feature is more usual in inflammation than on neoplasm^{1,2,3}

The clinical hallmark of this lesion is local pain which is dull, throbbing and intermittent, but subsequently it usually increases in severity. Nocturnal pains are common. Point tenderness over the lesion is present along with the slight local swelling. Dramatic relief of pain is obtained in most of the cases with aspirin. Golding reported that osteoid osteoma exerts pressure on surrounding bone, presumably because of its vascular in nature. Sherman et al demonstrated nerve fibers in the fibrous zone around the nidus and implicated them as mediators of pain. Schulman and Dorfman demonstrated nerve fibers within the matrix of lesion in sixteen of eighteen lesions studied. These fibers were associated with blood vessels and were found in greatest abundance in adjacent to arterioles. They postulated that neural elements demonstrated are sensitive to change in vascular pressure.^{2,3,4,5} Kolodny (1929) and Rowbotham (1939) believe that the vascular lesion put the bone into the state of metabolic activity, particular around the venous sinuses draining the tumor and committed on extremely slow growth of the lesion. Prichard and McKay reported that the central opaque body which varied in density as the calcification progress was seen Foss et al also reported that there may be calcification and ossification of the portion and all of the radiolucent nidus^{6,7,8,9,10}

IV. Conclusion:

In conclusion, osteomas are slow growing painful benign tumors usually occurring in long bones but can also occur in jaw bones. This pain can be as severe as a neuralgic pain which demands a local as well as a central cause to be ruled out with advanced radiographic techniques like MRI, as in our case

Reference

- [1]. Osteoma of The Mandible Journal of Dental Sciences and Research, Vol 2, Issue 1, Feb 2011 Dr.Gayathri Goudar, Dr.RaviKumar.R, Dr.Manjunath.G.A, Dr.Jyothi Mahadesh
- [2]. Osteoid osteoma of mandible: a rare entity Journal of Indian Academy of Oral Medicine and Radiology .Cherry walia, parvati devi, thimmarasa VB, jayadev S.July-Sept 2010;22(3):162-164.
- [3]. ID Roy :Peripheral Osteoma ofMandible :MJAFI;2008;64:385-386. Masuki Y. Peripheral osteoma at the mentum of mandible. RinshoDerma 2002; 44: 735-7.
- [4]. Ida M, Kurabayashi T, Takahashi Y, Takagi M, Sasaki T. Osteoid osteoma in the mandible. Dentomaxillofac Radiol. 2002;31:385-7.
- [5]. Osteoma of the zygomatic arch and mandible: report of two cases. Durão, Ana Reis; Chilvarquer, Israel; Hayek, Jorge Elie; Provenzano, Márcia; Kendall, Márcia Reis; Rev Port Estomatol Med Dent Cir Maxilofac.. 2012;53:103-7
- [6]. Kashima K, Rahman OI, Sakoda S, Shiba R. Unusual peripheral osteoma of the mandible: report of 2 cases. J Oral Maxillofac Surg. 2000;58:911-3.
- [7]. Mittal A, Nageshwar I. Large peripheral osteoma of the mandible. Oral Radiol. 2008;24:39-41.
- [8]. Chaudhary M, Kulkarni M. Osteoid osteoma of mandible. J Oral Maxillofac Pathol. 2007;11:52-5.
- [9]. Longo F, Califano L, Maria , Ciccarelli R. Solitary osteoma of the mandibular ramus: report of a case. J Oral Maxillofac Surg. 2001;59:698-700.
- [10]. Kerckhaert A, Wolvius E, van der Wal K, Oosterhuis JW. A giant osteoma of the mandible: case report. J Craniomaxillofac Surg. 2005;33:282.