

Absence of Isthmus of Thyroid Gland - A Case Report

¹Shambhu Prasad, ²Ramanuj Singh, ³Neeraj kumar, ⁴Sujeet Kumar

^{1,2}Assistant Professor, Department of Anatomy, NMCH, Sasaram, India

³Professor, Department of Anatomy, NMCH, Sasaram, India

⁴Assistant Professor, Department of Otorhinolaryngology, NMCH, Sasaram, India

Abstract: Thyroid gland develops from a median endodermal thickening in floor of primitive pharynx and descends through the neck anterior to developing hyoid bone and laryngeal cartilages to its final position in neck. Aberration in development may lead to absence of a part or whole of gland, gland in ectopic site or fistulas, sinuses and cysts related with thyroglossal duct. These anomalies can have serious surgical and clinical implications. Through this case report we would like to bring attention of clinicians and anatomists to the incidence of absence or agenesis of the isthmus and its developmental, surgical and clinical importance.

Keywords: thyroid gland, isthmus, absence/agenesis

I. Introduction

Thyroid gland is first endocrine gland to develop in embryo.¹ It begins to form about 24 days after fertilization from a median endodermal thickening in the floor of the primitive pharynx near junction of first & second pharyngeal arches between tuberculum impar and copula respectively.^{1,2} This thickening soon forms a small outpouching – the thyroid primordium. As the tongue grows the developing thyroid gland descends through the neck, passing ventral to the developing hyoid bone and laryngeal cartilages. At first the thyroid primordium is hollow but it soon becomes solid & divides into right and left lobes connected by the isthmus.¹ Initially thyroid gland is connected to the tongue by a narrow tube (thyroglossal duct) but this tube degenerates or disappears by the end of 5th week and the isolated thyroid now consisting of lateral lobes connected by a well defined isthmus, continues to descend.² By seven weeks the thyroid gland reaches its final site in neck and also assumes its definitive shape.^{1,2} Proximal opening of the thyroglossal duct persists as a small pit in midline of the tongue – the foramen caecum, near the junction of anterior 2/3 and posterior 1/3 of tongue.

Aberration in development can lead to various anomalies like persistence of thyroglossal duct, thyroglossal cysts, fistula, sinuses, ectopic thyroid tissue, absence of a part or whole of the gland. These anomalies may be asymptomatic or may cause functional disorders and may be cause of surgical failures and complications.

Definitive thyroid gland is brownish red in color and highly vascular. It is placed anteriorly in lower neck level with the 5th cervical to 1st thoracic vertebrae, covered by the pretracheal layer of deep cervical fascia and consists of right and left lobes connected by a narrow, central isthmus. Weight of the gland is usually about 25 grams but this varies. The lobes are conical, apices lying level with oblique line of thyroid cartilage and bases level with 4th or 5th tracheal rings. Each lobe measures about 5cm vertically, 3cm transversely and 2cm anteroposteriorly.³

The isthmus connects the lower parts of the two lobes though occasionally it may be absent. Isthmus usually lies level with 2nd and 3rd tracheal rings, though often higher and sometimes lower because its size varies greatly it measures about 1.25cm both vertically and transversely.³ Pyramidal lobe – is a small conical mass of thyroid tissue extending upwards from the isthmus or either of the lobes (more often the left), occasionally detached or in two or more parts and represents a development of glandular tissue from caudal end of thyroglossal duct.^{3,4} It is present so often that it is regarded as a normal structure.⁵

Levator of thyroid gland – a fibrous or fibromuscular band attached to the inferior border of hyoid bone and running down to isthmus or pyramidal lobe.³ When muscle fibers are present it is named musculus levator glandulae thyroideae.⁴

Here we report a case with absence of isthmus and presence of pyramidal lobe with levator glandulae thyroideae attached to left lobe. Though thyroglossal duct cysts, fistulas and sinuses are more commonly encountered, absence/agenesis of isthmus/lobes are rarely/very infrequently reported.

II. Case Report

While performing dissection of anterior triangle in a male cadver we reflected the infrahyoid strap muscles to visualize the trachea and thyroid gland . We found the two lobes of the thyroid gland in their normal expected position with normal shape and size but the isthmus was surprisingly not present , we could easily identify and count the upper tracheal rings in the space between the lower part of the lobes which should have come to view only after cutting and reflecting the isthmus . There was no scar mark in neck thus excluding surgical removal.

Apices of the lobes extended to the sides of thyroid cartilage deep to the attachment of sternothyroid muscles while base extended up to level of 4th tracheal rings . Upper 4 tracheal rings could be easily identified between the two lobes , We also identified pyramidal lobe extending upwards from left lobe and band of fibrous tissue (levator glandulae thyroideae)extending between hyoid bone and pyramidal lobe . The neurovascular structures (superior and inferior thyroid vessels , superior and recurrent laryngeal nerves) had normal course and relation with the gland . Other structures in the triangle were also normal.

III. Discussion

Thyroid gland is made of the 2 lateral masses (lobes) and central narrow connecting portion (isthmus) . Isthmus lies anterior to the upper part of trachea (over 2nd and 3rd tracheal rings usually) . Incidence of agenesis of the thyroid isthmus has been reported to vary from 5% to 10% by Pastor et al and from 8% to 10% by Marshall , 33% by Ranade et al and 14.6% by Dixit et al .⁶⁻⁹ Dixit et al report male –female ratio of 5:1.⁹ The incidence in north-west Indians is reported to be 7.9% in gross specimens .¹⁰ However no data is available regarding its frequency in people of eastern part of India . Some literatures suggest role of chromosome 22 in development of thyroid gland .¹¹

We know thyroid gland develops from median endodermal thickening in the floor of primitive pharynx . The endodermal thickening gives rise to thyroid primordium which is hollow initially but solidifies subsequently and then from a single mass two lateral lobes and the intervening isthmus is formed . Now since whole of the gland is developing from a single mass of tissue any developmental disarray can possibly result in complete division of the primordial tissue into 2 masses with no interconnection and thus absence of isthmus in final anatomy of the gland . Sgalitzer says rarely a high separation of thyroglossal duct can engender two independent thyroid lobes and pyramidal lobes with the absence of isthmus .¹²

Aberration in development may lead to absence of a part or whole of gland , gland in ectopic site or fistulas , sinuses and cysts related with thyroglossal duct . These anomalies can have serious surgical and clinical implications .

Not much studies have been done regarding the effect of absence of isthmus but it is possible that the anastomotic network of vessels that run on the edges and surface of isthmus which connect the vessels of two sides may be compromised or absent – we did not find any vessels connecting the right and left thyroid vessels also the pretracheal venous plexus that gives rise to inferior thyroid veins was also missing . Thus it is possible that the absence of the isthmus can affect the blood supply and hence functioning of the thyroid gland as well .

Absence of the isthmus may be associated with absence of whole or part of the lobes and hence surgeons doing partial thyroidectomy for thyroid ailment should assess whether the remaining portion of thyroid gland is present and functioning otherwise patient may be inadvertently rendered hypothyroid .If surgery is necessary enough , patient could be made euthyroid with use of oral thyroxine supplements .

On the positive side absence of thyroid isthmus may become a God's gift for a patient needing emergency tracheostomy as absence of the isthmus will save critical time of cutting and tying or hooking away the isthmus for visualizing the tracheal rings while performing tracheostomy .

Thus we can say that proper knowledge of normal anatomy as well as possible variations is of use for both physicians and surgeons for making correct diagnosis , also efficient management of thyroid related diseases and airway management in cases with respiratory obstruction .

References

- [1]. Moore KL, Persaud TVN. The Developing Human Clinically Oriented Embryology. 7th ed. Saunders; 2003. Chapter 10, The pharyngeal apparatus; p.215-17.
- [2]. Larsen WJ. Human Embryology. 2nd ed. Hong Kong : Churchill Livingstone Inc; 1997. Chapter 12, Development of Head , the Neck and the Eyes and Ears; p.371.
- [3]. Standring S. Gray's Anatomy The Anatomical Basis of Clinical Practice. 40th ed. Spain: Elsevier; 2008. Chapter 28, Neck ; p.462
- [4]. McMinn RMH. Last's Anatomy Regional and Applied. 9th ed. Singapore: Churchill Livingstone; 1994.Chapter 6, Head and Neck and Spine ; p.430-31.
- [5]. Singh I, Pal GP. Human Embryology. 8th ed. India: Macmillan India Limited; 2007. Chapter9, pharyngeal arches; p.112-15.
- [6]. Pastor VJF, Gil VJA, De Paz Fernández FJ, Cachorro MB. Agenesis of the thyroid isthmus. Eur J Anat. 2006; 10: 83-84.
- [7]. Marshall CF. Variations in the form of the thyroid gland in man. J Anat Physiol. 1895; 29: 234-239.
- [8]. Ranade AV, Rai R, Pai MM, Nayak SR, Prakash, Krishnamurthy A, Narayana S. Anatomical variation of the thyroid gland: possible surgical implications. Singapore Med J. 2008; 49(10): 831-834.

- [9]. Dixit D , Shilpa MB , Harsh MP , Ravishankar MV . Agnesis of isthmus of thyroid gland in adult human cadavers : a case series . Cases Journal. 2009 ; 2:6640.
- [10]. Harjeet A, Sahni D, Jit I, Aggarwal AK. Shape, measurements and weight of the thyroid gland in northwest Indians. Surg Radiol Anat. 2004; 26: 91-5.
- [11]. Gangbo E, Lacombe D, Alberti EM, Taine L, Saura R, Carles D. Trisomy 22 with thyroid isthmus agnesis and absent gall bladder. Genet Couns. 2004;15:311-5.
- [12]. Sgalitzer KE. Contribution to the study of the morphogenesis of the thyroid gland. J Anat 1941; 75: 389-405.

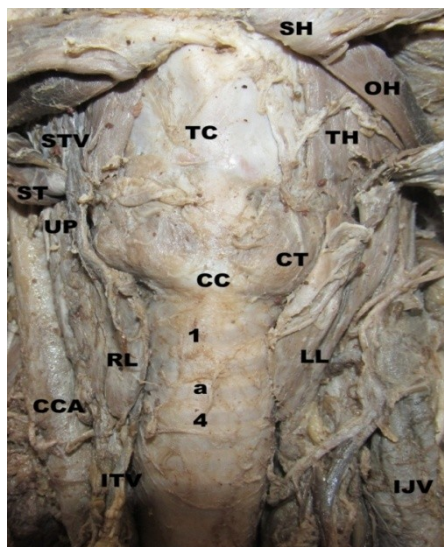


Figure 1. – showing the thyroid gland with absent isthmus . 1 – 1st tracheal cartilage , 4 – 4th tracheal cartilage , a – usual site of thyroid isthmus (we can see the 2nd and 3rd tracheal cartilages also because isthmus is not present) , CC – anterior arch of cricoid cartilage , CCA – common carotid artery , CT - cricothyroid muscle , IJV – internal jugular vein , ITV – inferior thyroid vessels , LL – left lobe of thyroid gland , RL - right lobe of thyroid gland , OH – omohyoid muscle(superior belly) , SH – sternohyoid muscle , ST – sternothyroid muscle(reflected upwards) , STV – superior thyroid vessels , TC – thyroid cartilage , TH – thyrohyoid muscle , UP – upper pole of thyroid gland lies deep to sternothyroid muscle (muscle restricts upward enlargement of the gland) .

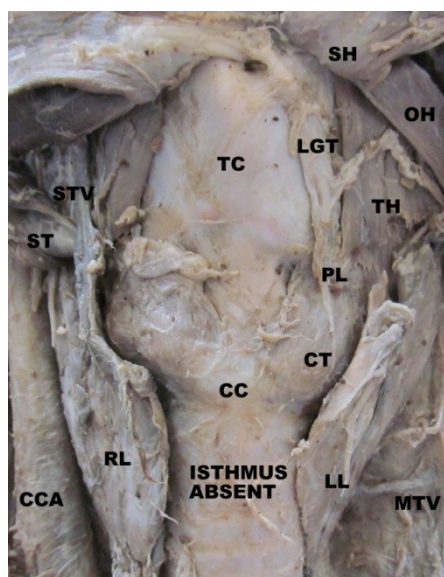


Figure 2 – Neck dissection of same cadaver showing thyroid gland with LGT and pyramidal lobe . CC – anterior arch of cricoids cartilage , CCA – common carotid artery , CT – cricothyroid muscle , LGT – levator glandulae thyroideae , LL – left lobe of thyroid gland , RL – right lobe of thyroid gland , OH – superior belly of omohyoid muscle , MTV – middle thyroid vein (running horizontally outwards from left lobe towards IJV) , PL – pyramidal lobe of thyroid gland ,connection with the left lobe has been cut , SH – sternohyoid muscle , ST – sternothyroid muscle , STV – superior thyroid vessels , TC – thyroid cartilage , TH – thyrohyoid muscle .