

Trichofolliculoma of Nasal vestibule: A rare case report.

Pradip M¹, Santosh D², Gautamjit RK³, Niteshore M⁴, Nicola CL⁵,
Priyoshakhi H⁶.

^{1,2,3,5,6}(Department of Otorhinolaryngology, Regional Institute of Medical Sciences, India)

⁴(Medical Officer, Govt of Manipur, India)

Abstract : Trichofolliculoma is a rare benign neoplasm which originates from hair follicles. Though it is present on face and head and neck region presentation in the vestibule of nose is relatively rare. Here a case of trichofolliculoma of nasal vestibule is presented because of its rarity in vestibule of nose. The clinical picture and histopathological presentation is described in this case report. To the best of our knowledge trichofolliculoma has not been described in northeast India previously.

Keywords: acantholyticdyskeratosis, hamartoma, multilocularcrateriform, umbilication, vestibule.

I. Introduction

Trichofolliculoma is a benign neoplasm arising from skin. It is a rare hamartomatous condition which is predominantly seen in adults and involves usually the skin of face and occasionally scalp and neck. It is first described by Miescher in 1944 as a rare adnexal cell tumour [1]. Kligman et al in 1960 classified the nevi tumour of skin and mentioned trichofolliculoma as one of them [2]. The etiology of trichofolliculoma is not known. It doesn't show any racial or gender predilection. It is associated with one or more fistulous openings from which terminal hairs, vellus hairs and trichoids protrude. It presents as a single firm papule on the face, whitish or flesh in colour and usually white hair emerging from a central dell. Congenital or childhood presentation of these tumours is very rare [3].

II. Case Report

A 52 years old man presented with pedunculated mass inside the left nostril at the lateral wall of vestibule for 4 years and nasal obstruction on the left side for last one year. The mass has increased gradually and obstructed the left nostril over the years. On anterior rhinoscopy a pedunculated mass of 1.5 x 1.5 cm² with smooth surface and of greyish white in colour is seen in the anterior part arising from the left lateral wall of nasal vestibule (Fig.1). Posterior rhinoscopy did not show any abnormality. Family history did not reveal any similar condition in his family. No other similar lesion is seen in any other part of body. Direct rigid nasal endoscopy was done and found the mass is blocking the external nasal valve. Other nostril shows no abnormality. Patient was treated with surgical excision of the tumor under local anesthesia. Tumour of 1.5 x 1.5cm² sized excised from left nostril and the stump was cauterized with bipolar electrocautery. Patient was discharged with topical antibiotic ointment and oral analgesics. Histopathological examination showed a polypoidal tissue mass lined by skin. The dermis shows a benign adnexal tumour composed of large keratin filled cyst lined by stratified squamous epithelium. Emanating from the cyst are numerous hair follicles. The intervening stroma is mildly fibrotic. Also seen are many cysts containing hair shafts. There is no evidence of nuclear atypia, abnormal mitoses or areas of necrosis in any of the sections studied. All the features are suggestive of Trichofolliculoma (Fig. 2). There were no immediate complications of surgery.

III. Discussion

Trichofolliculoma, is an asymptomatic, rare, benign tumor of the hair follicle, which is a hamartoma. It consists of a multilocularcrateriform cavity lined by epidermoid stratified squamous epithelium. Small laterally orientated sinuses may drain into the central cavity, which contains hairs of varying size as well as keratinous debris. Sebaceous trichofolliculoma is till now an unrecognized variety of trichofolliculoma and histologically recognizable more than usual differentiation [1]. It is not associated with any disease though rarely, this condition has been associated with focal acantholyticdyskeratosis [4]. Found mainly in face and head and neck region but unusual finding in vulva is also reported [5]. Morphological study shows trichofolliculoma are variable, reminiscent of the anagen, catagen, and telogen phases of a normal hair follicle in its cycle and demonstrate hyperplasia of Merkel cells in all three stages [6]. The diagnosis can be suspected clinically if the tumour occurs as a small dome shaped nodule with a central umbilication showing small immature hair. On microscopy the tumour shows on or several keratin filled sinuses with from which epithelial columns or buds radiates. Malignant transformation of trichofolliculoma is rare but reported so full thickness of complete primary excision is needed.

IV. Figures and Tables

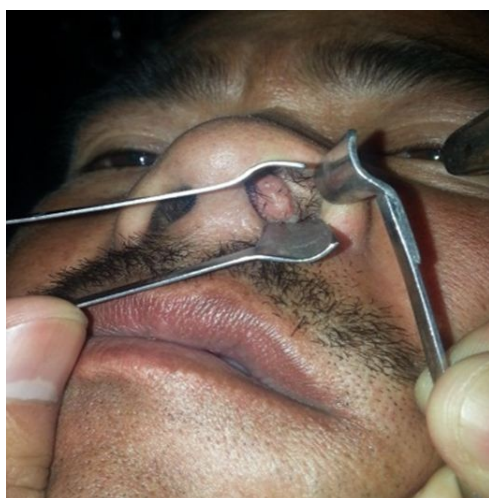

Fig 1: Mass in lateral wall of nasal vestibule

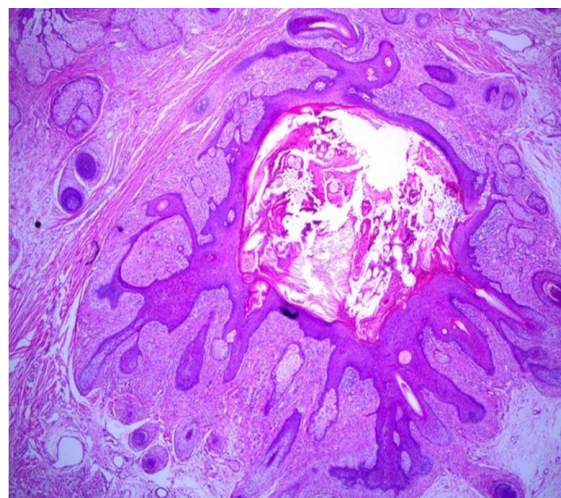


Fig 2: Microscopic appearance

V. Conclusion

Trichofolliculoma, is an asymptomatic, rare, benign tumor of the hair follicle, which is a hamartomatous lesion. Although common in head and neck region, there is no reported case of trifolliculoma in the nasal vestibule in the North-eastern part of India. Even though it is a benign condition, malignant transformation has been reported and complete full thickness excision is the treatment of choice.

Acknowledgements

We are highly indebt to the pathologist and staff of Department of Pathology for their support and dedication. We also would like to thank the staff of the Department of Otorhinolaryngology.

References

- [1] Miescher. Trichofolliculoma. *Dermatologica*. 1944; 89:193-4.
- [2] Kligman AM, Pinkus H. The histogenesis of nevoid tumours of the skin. *Arch Dermatol* 1960; 81:922-30.
- [3] Ishii N, Kawaguchi H, Takahashi K, Nakajima H. A case of congenital trichofolliculoma. *J Dermatol*. 1992 Mar;19(3):195-6.
- [4] Bogle MA, Cohen PR, Tschen JA. Trichofolliculoma with incidental focal acantholytic dyskeratosis. *South Med J*. Aug 2004;97(8):773-5.
- [5] Peterdy GA, Huettner PC, Rajaram V, Lind AC. Trichofolliculoma of the vulva associated with vulvar intraepithelial neoplasia: report of three cases and review of the literature. *Int J GynecolPathol*. Jul 2002;21(3):224-30.
- [6] Hartschuh W, Schulz T. Immunohistochemical investigation of the different developmental stages of trichofolliculoma with special reference to the Merkel cell. *Am J Dermatopathol*. Feb 1999; 21(1):8-15