

## **Fish hook and line impaction in the Esophagus: An unusual and interesting foreign body.**

Ogah Stephen Agbomhekhe<sup>1</sup>, Olatoke Fatai<sup>1</sup>, Okomanyi Abraham<sup>2</sup>,  
Igbobu Blessing<sup>2</sup>.

<sup>1</sup>Consultant Otolaryngologist, Head and Neck Surgeon. Otolaryngology Division, Department of Surgery,  
Federal Medical Centre, Lokoja, Nigeria.

<sup>2</sup> Medical Officer, Otolaryngology Division, Department of Surgery, Federal Medical Centre, Lokoja, Nigeria.

---

**Abstract:** We report the case of a 28-year-old male Nigerian student, who presented in the Accident and Emergency Department of our Hospital with a five-hour history of fish hook and line impaction in the oesophagus. Patient noticed the line dangling from his mouth after swallowing a bolus of food. His initial attempts to remove it by pulling the string failed and he then resolved to swallow some more boluses in an attempt to dislodge the hook which also failed. There was an associated history of dysphagia, odynophagia and drooling of saliva. There was no difficulty in breathing, chest pain or fever.

X-ray soft tissue neck done showed a radio-opaque foreign body in the oesophagus at the level of the 6th cervical vertebra. A rigid oesophagoscopy was done to retrieve the foreign body and a size 18FR naso-gastric tube was passed to rest the oesophagus. Third day post surgery, patient was started on tubal liquid diet and the tube removed on day six and was discharged.

**Key words:** Fishhook, line, impaction, oesophagus

---

### **I. Introduction**

Throat foreign body impaction is a common surgical emergency in the practice of Otolaryngology the world over. All age groups are involved but the incidence is higher in children below the age of five years, the edentulous and Psychiatric patients (1). They varied in types, shapes and sizes. May be sharp or blunt, pointing or curved. Whatever their shapes, the sharp ones are more dangerous irrespective of their sizes due to their ability to perforate and migrate to other parts of the body. In doing this, they can cause injuries to vital organs along their pathway of migration. Fish bones are said to be the most common throat foreign bodies followed by chicken bones (2).

The fish hook device has been in existence since 7000 BC and Archaeologist had it that the world's oldest fish hook was discovered at a site in East Timor, about 42,000 years ago. There has been evidence that modern humans were catching fish from the open ocean from a limestone cave site known as the Jerimalai shelter on the north of the island (3). Being this as it may, injuries from fish hook were largely restricted to the skin and body surfaces(4). These injuries were also restricted to those who were fisher men and those who fish as a hobby. Impaction of a fish hook in the oesophagus is quite uncommon, let alone when the line is attached to it.

### **II. Case Report**

A 28-year-old male Nigerian presented in the Accident and Emergency Department with a five-hour history of fish hook and line impaction in the throat. Patient was eating when he noticed the line dangling from his mouth after swallowing a bolus of food. Several unsuccessful attempts were made to remove the line by pulling on it, this rather caused the patient throat pains. He also swallowed some more boluses to dislodge the hook but to no avail. There was associated history of dysphagia, odynophagia and drooling of saliva.

There was no difficulty in breathing, chest pain or fever. There were no nasal and otological symptoms. Past medical history not contributory and there were no inter current medical illnesses.

Examination revealed a young apprehensive man who was not pale, afebrile, anicteric and not in obvious respiratory distress with a line dangling from his mouth (fig.1). Throat examination confirmed the line to have descended into the pharynx with minimal saliva collection in the oral cavity. There was no other significant throat findings, the nose, ears and neck were essentially normal.

X-ray soft tissue neck done showed a radio-opaque object vertically placed at the level of the 6th cervical vertebra (fig.2)

A rigid oesophagoscopy was done to identify the foreign body at about 17cm from the incisors. The hook and line were removed (fig.3)




Figure 1

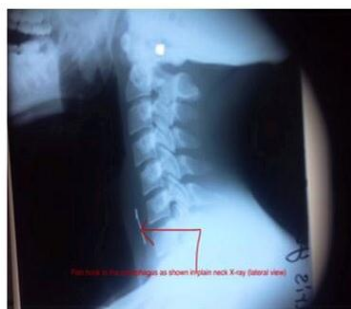

Figure 2

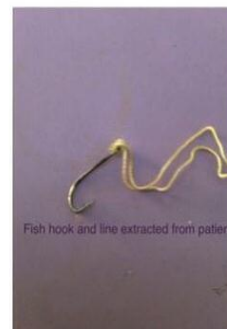


Figure 3

And a nasogastric tube size 18FR was passed to rest the oesophagus.

Patient was started on tubal feeding 72 hours later, then peri-tubal and the tube was removed sixth day post operatively. Patient was discharged with no complication.

### III. Discussion

Foreign bodies in the orifices are common emergencies in Otolaryngology. Oesophageal foreign bodies usually become impacted in areas where the oesophagus is constricted. It is said that objects greater than 2 cm in diameter has difficulty traversing the normal adult oesophagus [1].

The Otolaryngologist needs to deal with sharp aero-digestive foreign bodies fast so as to avoid deeper tissue penetration and subsequent abscess formation as reported by Afolabi et al [2] and D'Costa et al [5].

The types of foreign body impaction in the oesophagus of a patient will depend on age, sex, occupation and geographical location of the patient. Coins, plastics, parts of toys, play items, and sometimes corrosives are common in children of playing age, while meat, kola nuts and dentures are more common in adults as reported by Okeowo [6]. Fish hook injuries can occur to different parts of the body such as skin, eyelids, hands and trunk in fisher men and those who take fishing as a recreational activity [7-12]. In which case, it's removal is quite simple but fish hook impaction in the oesophagus is unusual and more so that the line is attached.

Fish hook impaction in the hypopharynx has been reported by Boko et al [13], while Okhakhu and Ogisi [14] also reported one in the oesophagus. However, none of these reports mentioned that the lines were attached to these hooks at the time of impaction.

### IV. Conclusion

People should observe what they intend to swallow and should never be in a hurry when taking their meals. In case of accidental ingestion of foreign bodies, they should be referred on time to the appropriate specialist for management.

### References

- [1]. Akenroye M I, Osukoya A T. Uncommon, undeclared oesophageal foreign bodies. *Niger J Clin Pract* 2012;15:244-6
- [2]. Afolabi OA, Bolaji BO, Adebola SO, Ogah SA, Ologe FE. Penetrating aero-digestive fish bone injury. *J Med Trop* 2013;15:162-4
- [3]. O'Connor S, Ono R, Clarkson C. Pelagic fishing at 42,000 years before the present and the maritime skills of modern humans. *Science*. 2011; 334: 1117-1121.
- [4]. Thommasen HV, Thommasen A. The occasional removal of an embedded fish hook. *Can J Rural Med* 2005;10(4):254-9.
- [5]. D'Costa H, Bailey F, McGavigan B, George G, Todd B. Perforation of the oesophagus and after eating fish: An unusual cause of chest pain. *Emerg Med J* 2003;20:385-6
- [6]. Okeowo PA. Foreign Bodies in the Pharynx and Oesophagus: A Ten Year Review of Patients seen in Lagos. *Nigerian Quart J Hosp Med* 1985;3:46-50
- [7]. Halaas GW. Management of foreign bodies in the skin. *Am Fam Physician* 2007;76(5): 683-8.
- [8]. Ainsworth-Smith M. Practice makes perfect: Fishing hook removal. *Emerg Nurse* 2005;13(6):12.
- [9]. Kreis AJ. Fishing Down Under: Case report and review of management of a fishhook injury of the eyelid. *Clin Exp Optom* 2008;91(5):473-5
- [10]. Eldad S, Amiram S. Embedded fishhook removal. *Am J Emerg Med* 2000;18(6):736-7.
- [11]. Dixon GD. Removal of fishhooks. *N Engl J Med* 1965;272:1068-9
- [12]. Jones PA. Removal of fish-hooks. *Br Med J* 1974;3(5922):41.
- [13]. Boko E, Songne B, James K. Fish hooks: an unusual and sharp foreign body in the hypopharynx. *Med Trop (Mars)*.2000;60(4):361-2
- [14]. Okhakhu AL, Ogisi FO. An unusual foreign body in human oesophagus-Case report. *Benin Journal of Postgraduate Medicine*. 2007; 9(1):41-3