

Tubercular Esophagocutaneous Fistula in a child: Case report with review of literature

Preeti Tiwari^{1*}, AN Gangopadhyay², Vijayendar Kumar³, Vaibhav Pandey⁴

¹B.D.S, M.D.S., Oral and Maxillofacial surgeon, Samayan hospital Varanasi, U.P.

²M.B.B.S, M.S, M.Ch., Professor, Department of Paediatric Surgery, Institute of Medical Sciences, Banaras Hindu University, Varanasi, U.P.

³M.B.B.S, M.S, M.Ch., Associate Professor Department of Paediatric surgery, Institute of Medical Sciences, Banaras Hindu University, Varanasi, U.P.

⁴M.B.B.S, M.S, M.Ch., Senior Resident, Department of Paediatric surgery, Institute of Medical Sciences, Banaras Hindu University, Varanasi, U.P.

Abstract: Tubercular esophagocutaneous fistula is a rare entity with only about five cases reported so far. To our best knowledge we herein report first case of tubercular esophagocutaneous fistula in neck of a child with a long tract which responded well to antitubercular treatment.

Keywords: Tuberculosis, Fistula, Esophagocutaneous, Intestinal tuberculosis

I. Introduction

Gastrointestinal tuberculosis continues to be a significant cause of morbidity and mortality in children of developing countries. Primary tuberculous involvement of the esophagus is very rare, accounting for less than 0.2% of all tuberculosis patients [1]. It usually results from a spread of an adjacent focus, such as the lung or mediastinal nodes [2]. Esophagocutaneous fistula is a very rare complication of tuberculosis [3].

II. Case Report

A 3 year old female of presented with a complaint of multiple bilateral swellings in cervical region for 4 months. She was on multiple antibiotics prescribed at some other hospital empirically and had undergone incision and drainage of right sided cervical swelling following which she had developed complaints of food particles coming out occasionally from the wound. Examination of neck revealed a fistulous opening on the lateral part of mid cervical region on the right side, draining saliva. Rest of systemic and local examination was normal. Fistulous tract was cannulated and fistulogram was obtained which showed cutaneous fistula communicating with upper part of esophagus [Fig. 1]. Biopsy showed caseating epitheloid granulomas with AFB positivity. Investigations for pulmonary and extrapulmonary tuberculosis were negative. Anti tubercular treatment (ATT) was started. On 1 year follow up patient was asymptomatic with healed fistula with a normal barium swallow study [Fig 2, 3].

III. Discussion

Gastrointestinal tuberculosis is a major cause of morbidity and mortality in children. Ileocaecal region is most common site with involvement in about 40% of cases [4]. Esophageal tuberculosis can be primary or secondary. Usually it is secondary to tuberculous caseation involving the neighboring structures [2, 3]. In the setting of an esophageal stricture or ulceration, swallowed infected sputum can give rise to primary mucosal involvement of the esophagus [2, 3]. In our case the caseating nodes of the neck had eroded the esophagus and led to the fistula formation following drainage procedure. Esophagocutaneous fistula is an extremely rare entity. All previously reported cases are from adults and the fistula presented at various places on chest wall [5-7]. Our case was unique as it posed the diagnostic dilemma by virtue of the patient's age and also due to the site of external opening on the neck. Also in all the previously reported cases the mediastinal lymph nodes or lungs were involved. In our case the child was asymptomatic except the presence of fistula and cervical lymphadenopathy. The differential diagnosis of the fistulous tracts of the esophagus in paediatric age is extremely rare and may be caused by Crohn's disease and trauma. The exact site of fistula and its length can be confirmed by demonstration of the fistulous tract with radiocontrast studies [6]. Computed tomographic scanning of thorax with oral and intravenous contrast can also show associated mediastinal lymphadenopathy associated with esophagocutaneous fistula [8]. Pathologic and micro- biologic confirmation can be obtained by biopsy and culture of sinus tract endoscopically or percutaneously. Esophageal tuberculosis is reported to respond well to medical treatment in 4–8weeks [8]. Exploration of the fistula and its excision may be required if it fails to respond to ATT.

IV. Conclusion:

The presence of esophagocutaneous fistula in neck of a child is a sign of underlying tuberculosis. High suspicion is required for early diagnosis & prompt treatment as the condition is rare in paediatric age group with potential complications.

Legends

Figure 1: Fistulogram showing fistulous communication with upper esophagus

Figure 2: Healed fistula in neck at 1 year follow up.

Figure 3: Normal barium swallow at 1 year follow up.

References

- [1]. Sathiyasekaran M, Shivbalan S (2004) Esophageal tuberculosis. *Indian J Pediatr* 71:457–458
- [2]. Shah S (2002) Esophageal tuberculosis: is it so rare? Report of 12 cases and review of the literature. *Indian J Gastroenterol* 21:170
- [3]. Devarbhavi HC, Alvares JF, Radhikadevi M (2003) Esophageal tuberculosis associated with esophagotracheal or esophagomediastinal fistula: report of 10 cases. *Indian J Surg* 57:588–592
- [4]. Chou Rasheed, S., Zinicola, R., Watson, D., Bajwa, A. and McDonald, P.J. (2007) Intra-abdominal and gastroin-testinal tuberculosis. *Colorectal Disease*, 9, 773-783.
- [5]. Vinodh BN, Sharma SK, Smith-Rohrberg D, Seith A (2006) Tubercular esophagocutaneous fistula. *Indian J Chest Dis Allied Sci* 48:209–211
- [6]. Xavier S, Kochhar R, Nagi B, Singh K (1996) Tuberculous esophagocutaneous fistula. *J Clin Gastroenterol* 23:118–120
- [7]. Gordon AH, Marshal JB (1990) Esophageal tuberculosis— definite diagnosis by endoscopy. *Am J Gastroenterol* 85:174–177
- [8]. Im JG, Kim JH, Han MC et al (1990) Computerised tomography of esophagomediastinal fistula in tuberculous mediastinal lymphadenitis. *J Comput Assist Tomogr* 14:89–92

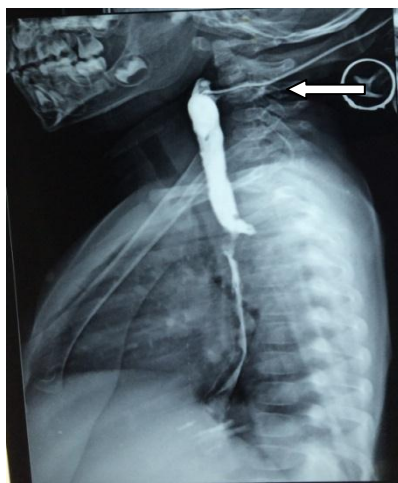


Figure 1

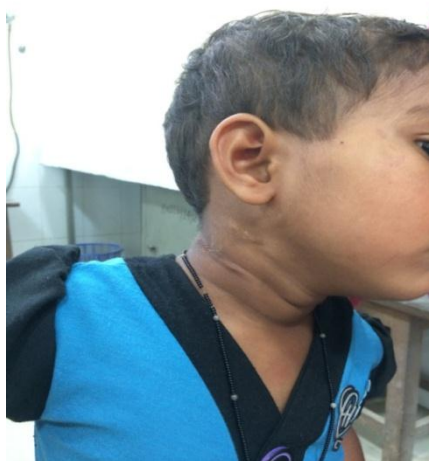

Figure 2

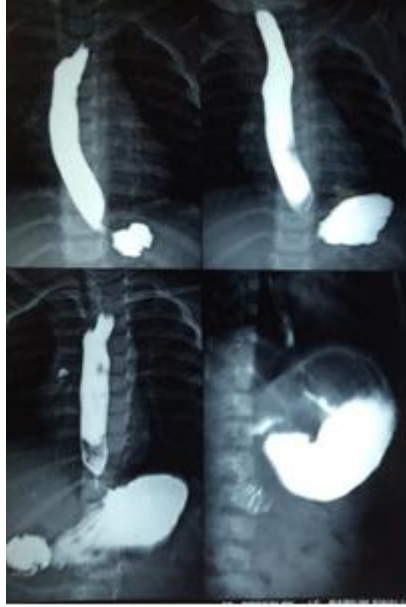


Figure 3