

## Hartmann's Pouch – A study in North Coastal Andhra Pradesh, India

<sup>1</sup>Dr.K .Lakshmi Kumari.M.D, <sup>2</sup>Dr.P.V.S.S.Vijaya Babu M.D.

*1 Assistant Professor , Department of Anatomy, Andhra Medical College, Visakhapatnam. Andhra Pradesh, India.*

*2 Assistant Professor, Department of Biochemistry, Andhra Medical College, Visakhapatnam. Andhra Pradesh, India.*

**Abstract:** This study discusses the percentage of Hartmann's pouch of gall bladder and whether the Hartmann's Pouch is an anatomical variation or pathological presentation in North Coastal Andhra Pradesh. India. Knowledge of relevant anatomy is important for the safe execution of any operative procedure, specifically in laparoscopic cholecystectomy. It has been recognized since long that misinterpretation of normal anatomy as well as presence of anatomical variations contribute to the occurrence of major post operative complications especially biliary injuries. Apart from this, association of Hartmann's pouch with gall stones is one of the pathological conditions. 102 gall bladders of both gender were obtained from Department of Anatomy ,Andhra Medical College , Visakhapatnam, Andhra Pradesh, India .These Gall bladders were examined for the presence of Hartmann's pouch and its association with gall stones.We found 4.9% of Hartmann'spouch in total specimens and 60% of Hartmann's pouches are associated with gall stones. To conclude percentage of Hartmann's pouch is variable and it is mostly associated with pathological conditions.

**Key words:**Gall bladder,Hartmann's pouch,Percentage ,Gall stones.

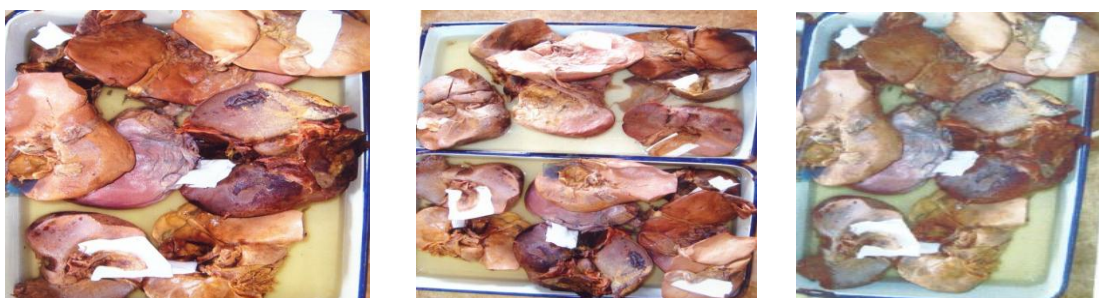### I. Introduction:

Hartmann's pouch is a diverticulum seen at the neck of the gall bladder. It is one of the rarest congenital anomalies of the gall bladder. It has gained interest in view of laparoscopic cholecystectomy. Injuries during laparoscopic cholecystectomy can cause significant morbidity and occasionally even mortality. Impaction of gall stones within the Hartmann's pouch results in mucocele where bile is absorbed and replaced by mucous secreted by gall bladder epithelium. An unusual presentation of gall stones within Hartmann'spouch causes obstruction of common hepatic duct by extrinsic compression a phenomenon known as Mirizzi syndrome. Its clinical presentation is intermittent or persistent jaundice. In many cases the presence of Hartmann's pouch is not being identified preoperatively. Identification of presence of Hartmann's pouch and cholelithiasis is important during surgery to prevent intra operative and post operative complications .However different opinions exists with regards to its incidence. Knowledge of relevant anatomy is important for the safe excision of gall bladder in cholecystectomy procedures.

**Objectives:** This study aims to know the percentage of Hartmann's pouch of gall bladder and its association with gall stones in population of North Coastal Andhra Pradesh,India.

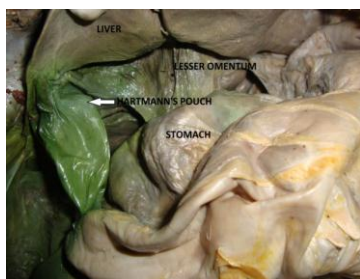
### II. Materials and Methods:

102 bladders of both genders were obtained from the Department of Anatomy , Andhra Medical College, Visakhapatnam, India, over a period of 4 years by routine procedure of standard dissection of cadavers.The cadavers being embalmed and allowed for dissection. The cadavers were embalmed with routine embalming solutions for anatomical dissection.

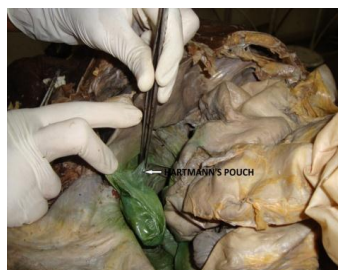

Collection of Specimens

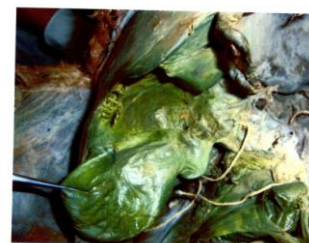By giving incision of skin and rectus sheath vertically along the middle of the rectus muscle the abdominal cavity was opened. After identifying the peritoneum, it was divided and reflected from the anterior abdominal wall. Liver was pulled superiorly and tilted its inferior margin anteriorly to expose the lesser omentum. Anterior layer of the peritoneum was removed from the omentum. Right gastric artery was traced to the proper hepatic artery and vein to portahepatis. Proper hepatic artery and its branches to the portahepatis were exposed. Cystic duct was traced from the neck of the gall bladder to its junction with common hepatic duct to form common bile duct. The anatomy of all the gall bladders were macroscopically studied for identification of Hartmann's pouches, dissection of gall bladders done to check the gall stones within the lumen of body, neck. Hartmann's pouch if present and cystic duct of gall bladder.



**Exposure of Hartmann's Pouch**



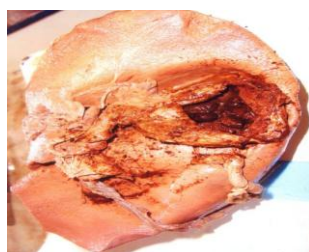
**Identification of Hartmann's Pouch**



**Hartmann's Pouch**

### **III. Results :**

In present study 102 gall bladders were carefully examined for Hartmann's Pouch. Hartmann's Pouch were detected in 5 ( 4.9%) gall bladders. 3 (60% ) Hartmann's Pouches were having gall stones.



**Gall stones in Hartmann's Pouch**

### **IV. Conclusion:**

Hartmann's Pouch is an inconstant feature. It is not a very common presentation in North Coastal Andhra Pradesh. There is a significant association between Hartmann's Pouch and gall stones in North Coastal Andhra Pradesh. Consequently Hartmann's Pouch is a pathological rather than an anatomical entity in this area.

### **References:**

- [1]. Eisendrath DN. Anomalies of the bile ducts and blood vessels as the cause of accidents in biliary surgeries. JAMA. 1918;71:864-7.
- [2]. Stransberg S M, Hertl M, Soper N J. An analysis of the problem of biliary injury during laparoscopic cholecystectomy. J Am Coll Surg. 1995;180:101-25.
- [3]. Davies and Hardins (1942) .The HP to be always associated with some pathological change, particularly dilatation is part of normal gall bladder. Lancet vol1 193:194.
- [4]. G.J Romanes (1964): Cunningham's text book of anatomy, 10<sup>th</sup>ed. The neck of G B at its junction with the body, sometimes has a small pouch (HP) projecting from its posteromedial wall towards the superior part of the duodenum. Although relatively common. Its presence is now generally accepted to be due to pathological changes.
- [5]. G.J Romanes E; (2006) Cunningham's manual of practical anatomy 15<sup>th</sup>ed Volume 2-Thorax and abdomen.
- [6]. Keith L Moore, Clinically oriented Anatomy, 2<sup>nd</sup>ed .Nillims&Nilkins Library of congress catalog in publication latarepin (1984).
- [7]. Kido Y et al . Association of incarcerated stones either in cystic duct or in Hartmann Pouch is 16%; Hepatogastroenterology 1997 Jan-Feb;44(13):50.3.
- [8]. The incidence is between 1nd 4% [www.alsgbi.org/pdf/1Beckinham](http://www.alsgbi.org/pdf/1Beckinham).
- [9]. Vafa Shayani M D, Lisa Jacob MD, Jonathan M, Seckier MD, FRCS, FACS. [www.sls.orgwww.laparoscopy.org](http://www.sls.orgwww.laparoscopy.org) Hartmann Pouch is a normal presentation.
- [10]. Mirizzi syndrome-Impaction of gall stone in the Hartmann Pouch or Gall bladder infundibulum and cystic duct. [www.wjgnet.com/4639.htm](http://www.wjgnet.com/4639.htm)