

## Biologic Width - Critical Zone for a Healthy Restoration

Maheaswari Rajendran<sup>1</sup>, Golla Usha Rao<sup>2</sup>, Logarani. A<sup>3</sup>,  
Sudagaran M<sup>4</sup>, S Rohan Badgujar<sup>5</sup>

<sup>1</sup>(Department of Periodontics, Tamilnadu Government Dental College & Hospital, India)

<sup>2</sup>(Department of Orthodontics, Tamilnadu Government Dental College & Hospital, India)

<sup>3</sup>(Department of Periodontics, Tamilnadu Government Dental College & Hospital, India)

<sup>4</sup>(Department of Periodontics, Tamilnadu Government Dental College & Hospital, India)

<sup>5</sup>(Department of Conservative Dentistry and Endodontics, Tamilnadu Government Dental College & Hospital, India)

---

**Abstract:** Restorative procedures today are based mainly on esthetically driven treatment planning that relies on the position of the teeth and the position and architecture of the soft tissue. Esthetics must not interfere with the harmony of the supporting tissues which is emphasised by the term biologic width. The concept of Biologic Width has been widely described by periodontists and restorative dentists. An adequate understanding of relationship between periodontal tissues and restorative dentistry is vital to ensure adequate form, function and esthetics, and comfort of the dentition. While most clinicians are aware of this important relationship, uncertainty remains regarding specific concepts such as biologic width and indications and applications of surgical crown lengthening or orthodontic forced eruption. These violations lead to complications like gingival inflammation, alveolar bone loss and improper fit of the restorative component. Three cases in which crown lengthening was done by different methods have been discussed in this article. Thorough examination before any restorative procedure and proper treatment planning will preserve the biologic width and paves way for a longer life of the restoration with a healthy periodontium.

**Key Words:** Biologic width, crown lengthening, orthodontic forced eruption, periodontium, restoration.

---

### I. Introduction

Dentistry of the modern era is dominated by restorative procedures that not only retain the functions of lost structures but also needs to retain the esthetics. Functional and esthetic restorations can gain complete patients' and dentists' satisfaction only when these restorations exist in harmonious relationship with the surrounding structures.

Often general dental practitioners come across to cases with chief complaints of a problematic or faulty restorations that appear to be normal to an untrained eye. Consistent complaint of the patient towards the inconvenience, makes the dentist to examine the regions with restorations and such cases are diagnosed as the restorations violating the biologic width.

### II. Review Of Literature

#### 2.1. Biologic Width

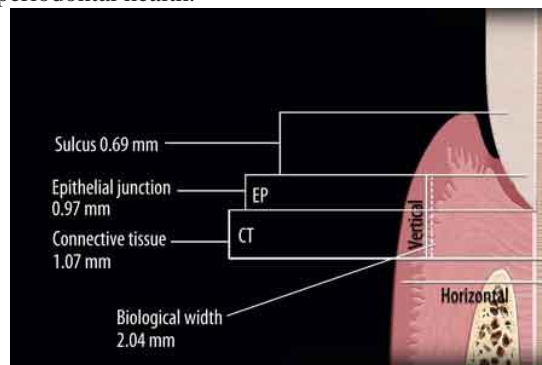
The concept of biologic width was initiated by Gargiulo et al in 1961, who reported a certain uniformity in the dimensions of some components of the periodontium which forms the biologic width.<sup>[1]</sup> It was described by Ingber, and the term biologic width was coined by D Walter Cohen.

Biologic width is defined as the dimension of the soft tissue, which is attached to the portion of the tooth coronal to the crest of alveolar bone.

With the cadaveric studies, Gargiulo et al., concluded the following mean dimensions i.e., they measured the dentogingival components of 287 teeth from 30 cadavers and found that there is a definite proportion between the sulcus depth, the epithelial attachment, the connective tissue attachment and the alveolar crest. They established the mean sulcular depth as 0.69 mm, junctional epithelium as 0.97mm (range between 0.71 to 1.35mm) and the mean of supraalveolar connective tissue attachment as 1.07mm (1.06 - 1.08mm). The total width of junctional epithelium and supraalveolar connective tissue attachment which forms the biologic width is  $0.97 + 1.07 = 2.04$  mm (Fig.1). The dimensions of periodontium are not constant and it varies from tooth to tooth and with each aspect of a tooth. It depends on the location of tooth within the alveolus.

The significance of biologic width is that, it acts as a barrier and prevents penetration of microorganisms into the periodontium.<sup>[2]</sup> Maintenance of biologic width is essential to preserve the periodontal health and to remove any irritation that may damage the periodontium. It is said that a minimum of 3mm space between the restoration margin and the alveolar bone is required to permit adequate healing and to maintain a

healthy periodontium.<sup>[3]</sup> This 3 mm consists of 1mm of supraalveolar connective tissue, 1mm of junctional epithelium and 1mm of sulcular depth. This allows for adequate biologic width (2.04mm) even when the margins are placed 0.5mm within the sulcus.<sup>[4]</sup> The location, fit and finish of restorative margins are critical factors in the maintenance of periodontal health.



**Figure 1: Dimensions of biologic width of tooth**

## **2.2. Types of restorative margins**

The restoration margins can be grouped in any of the following three categories: - supragingival, equigingival, and subgingival.

### **2.2.1. Supragingival margin**

It is the least irritating to the periodontium and is easy to prepare. The final fit and finish of the margins and removal of excess cement are also the easiest to achieve. Though this type of margin has the least impact to the periodontium, it is unaesthetic and preferred only in non-esthetic areas.

### **2.2.2. Equigingival margin**

Equigingival margin can be easily blended with the tooth and can be finished easily to provide a smooth and polished margins. But such margins are not desirable as they are thought to favor more plaque accumulation and therefore result in greater gingival inflammation.

### **2.2.3. Subgingival margin**

Though it is esthetic, it is detrimental to periodontal health as it acts as a permanent irritant to the periodontium. Many studies have demonstrated qualitative and quantitative changes in subgingival microbes, increased plaque index, gingival recession and pocket depth.<sup>[5]</sup>

Biologic width encroachment becomes more common when planning for subgingival restorations in cases that are fractured or carious, near the alveolar crest. Also esthetics demands often require hiding of restorative margins below the gingival margins i.e., pushing them down into the sulcus, which may cause biologic width violation.

## **2.3. Signs of Biologic Width Violation**

Biologic width violation can lead to chronic progressive gingival inflammation, clinical attachment loss and alveolar bone loss. This may be due to the destructive inflammatory response to plaque located at deep pockets. Gingival hyperplasia is also most frequently found in subgingivally placed restorative margins.<sup>[6]</sup>

## **2.4. Evaluation of Biologic Width Violation**

If a patient having discomfort when restorative margin levels are assessed with a probe, it is a good indication for biologic width violation. The most important diagnostic method is bone sounding, which is done by probing under local anesthesia to bone level. Biologic width is assessed by subtracting the sulcular depth from the resulting bone sounding measurement. If this distance is less than 2mm, then a violation of biologic width can be diagnosed. Radiographic evaluation can assess interproximal violation of biologic width. But it is not diagnostic because of tooth superimposition.<sup>[7]</sup>

## **2.5. Correction of biologic width violation**

Biologic width violation can be corrected surgically or orthodontically. Surgical correction is aimed at removing the bone away from the restorative margin while in orthodontic correction, the tooth is moved coronally away from the bone. Surgical correction is done by gingivectomy, apically repositioned flap with or without ostectomy. Orthodontic correction is done either by slow eruption or forced eruption with supracrestal fiberotomy.<sup>[8]</sup>

The mode of treatment is chosen based on the width of attached gingiva present, biologic width measurements as obtained from bone sounding, and esthetic requirements (Fig.2).

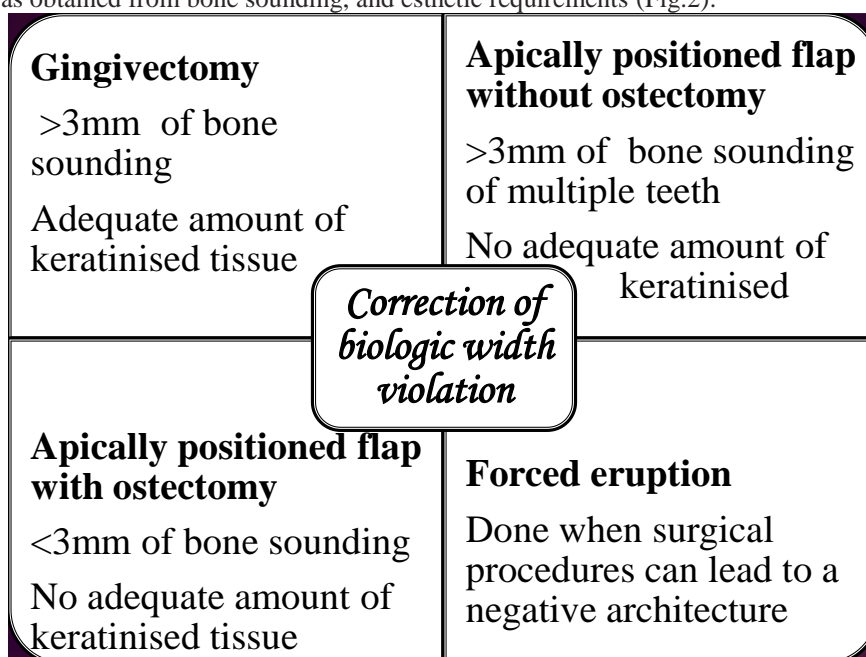


Figure 2: Methods to correct biologic width violation

### III. Case Reports

#### 3.1. Case 1

A fourteen years old male patient was referred from the Department of Conservative Dentistry and Endodontics for crown lengthening in fractured and endodontically treated 11 (maxillary right central incisor). Examination revealed Ellis' Class III fracture in 11 with fracture line in the gingival one third of the crown. There was no sign of gingival inflammation. On probing, sulcular depth was 3 mm in 11 with adequate attached gingiva. Bone sounding showed a value of 5mm from the gingival margin to the alveolar crest. Intraoral periapical radiograph (IOPA) revealed no bone loss. Surgical crown lengthening was done by gingivectomy using external bevel incision. The surgical site was protected using periodontal dressing. After an adequate healing period of two months, the tooth was restored with ceramic crown (Fig.3).

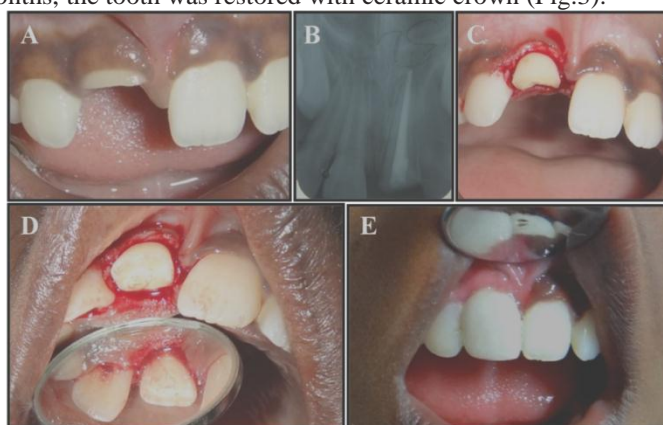
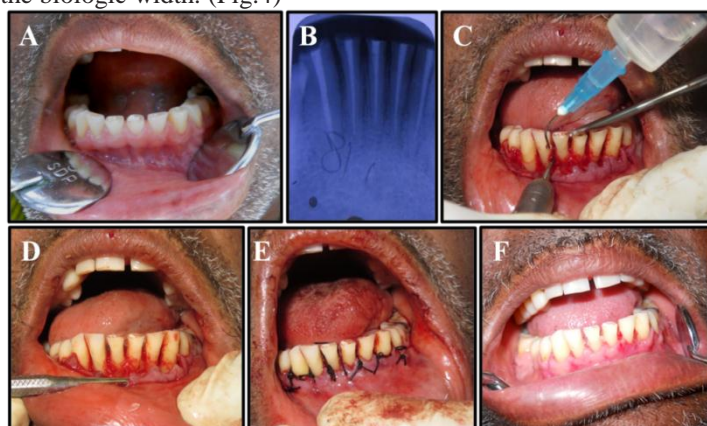


Figure 3: A - Pre-op photograph showing adequate attached gingiva. B- IOPA showing adequate bone support. C - Surgical crown lengthening done by external bevel gingivectomy (labial view). D- Palatal view of surgical crown lengthening. E- Post-op photograph showing 11 restored with ceramic crown.

#### 3.2. Case 2

Patient aged 54 years reported with a chief complaint of pain in relation to lower anterior teeth (33 to 43). On examination generalised attrition was present, with clinical crown of 2 to 3 mm and pulpal involvement in all the six teeth. Bone sounding measurement was equal to 3mm. IOPA revealed no bone loss. The treatment plan was to manage the involved teeth endodontically and increase the clinical crown length. After endodontic

treatment of lower anteriors, surgical crown lengthening was planned by apically repositioned flap with ostectomy to maintain the biologic width. (Fig.4)

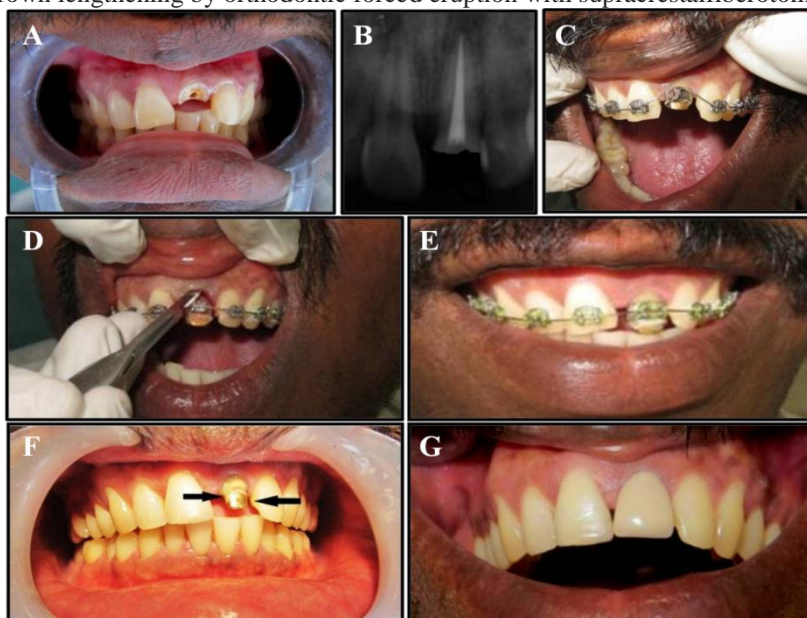


**Figure 4:**A- Pre-op photograph showing attrited lower anteriors with reduced clinical crown height. B- IOPA of the same region with adequate bone height. C- Ostectomy done to remove 3 mm of bone with round bur no.702 on slow speed micromotor under constant saline irrigation. D- Bone level after ostectomy. E- Flap apically repositioned and sutured. F- Post op photograph showing lower anterior teeth with 3 mm gain in clinical crown.

Under adequate anesthesia, mucoperiosteal flap was reflected with vertical releasing incisions distal to 33 and 43. Ostectomy was done to remove 3 mm of bone with round bur no.702 on slow speed micromotor under constant saline irrigation. The flap was then repositioned apically and secured with direct interrupted suture using 3-0 black silk and periodontal dressing was given. After three months, healing was satisfactory with a gain of 3 mm clinical crown (Fig. 4).

### 3.3. Case 3

A 19 years old young male patient was referred from the Department of Conservative Dentistry and Endodontics for crown lengthening in fractured and endodontically treated 21 (maxillary left central incisor). On examination the fracture line in 21 was coronally very close to the cervical margin with bone sounding measurement of 3mm. IOPA revealed no bone loss. Considering esthetics and the age of the patient, the case was planned for crown lengthening by orthodontic forced eruption with supracrestal fiberotomy.



**Figure 5:**A- Pre-op photograph showing fractured 11. B- IOPAC- NiTi arch wire ligated to 21 for forced eruption. D- Supracrestal fiberotomy done to facilitate orthodontic forced eruption. E- 21 extruded at the course of orthodontic forced eruption. F- Tooth preparation in extruded tooth. G- 21 restored with ceramic crown with a healthy periodontium.

Post space was prepared and prefabricated post was luted with glass ionomer cement in 21. Core build-up was done using composite, to gain optimal crown height for banding. 21 was banded with bracket welded to it and cemented subsequently. 0.016" NiTi wire was ligated to 21 for orthodontic forced eruption. Supracrestal fiberotomy was done once a week during 3 weeks eruption phase along with gingival repositioning of the band at each visit to favor the eruption process. Once sufficient clinical crown (4mm) was extruded, the tooth was stabilized for 6 weeks and restored with full crown. (Fig. 5)

#### **IV. Discussion**

Preserving the health of periodontium is vital for the success of any restoration. The main aim of any crown lengthening procedure is to increase the clinical crown length, with the primary objective to restore an adequate biologic width, create an adequate space for placement of restorative margins which can be achieved surgically or orthodontically.

Crown lengthening is indicated in cases with short clinical crowns, unequal or unaesthetic gingival margin, teeth with excessive occlusal / incisal wear, tooth fracture within the cervical third of the tooth, placement of sub-gingival restorative margins, and restorations which violate the biologic width.<sup>[8]</sup>

Cases with deep fracture requiring excessive bone removal, non-restorable teeth, teeth with inadequate crown-root ratio, increased risk of furcation involvement or unreasonable impairment of alveolar bone support, crown lengthening is contraindicated.

The most commonly employed technique for surgical crown lengthening is gingivectomy. Gingivectomy is done when there is an adequate amount of keratinised tissue and biologic width.<sup>[9]</sup> If there is no adequate attached gingiva and when crown lengthening is to be done in multiple teeth, then apically repositioned flap is preferred. Apically repositioned flap accompanied with osseous resection is done when biologic width is less than 3 mm. Apically repositioned flap should not be done if crown lengthening is to be done in a single tooth in the esthetic region.<sup>[10]</sup>

Orthodontic forced eruption is considered in cases where traditional surgical crown lengthening will lead to unaesthetic outcomes like crown lengthening of a single tooth in the esthetic region, where osteotomy could lead to a negative architecture. It is contraindicated in cases with inadequate crown-root ratio or lack of occlusal clearance for the required amount of eruption.<sup>[11]</sup>

In case 1, there was an adequate amount of attached gingiva and a healthy periodontium. As the sulcular depth was more, crown lengthening was done by gingivectomy without any impairment of biologic width.

In case 2, the clinical crown length of the six lower anterior teeth were short due to attrition with 1 mm probing depth and bone sounding measurement of 3mm. The treatment was planned to increase the length of the clinical crown without any extensive restorations, which demanded osseous resection. As crown lengthening was planned for six anterior teeth, apically repositioned flap with osteotomy was done to maintain the biologic width.

In case 3, the fracture line in 21 was very close to the cervical margin and the gingival margin level was same as the adjacent teeth. Esthetic considerations in this 19 years old patient contraindicated surgical crown lengthening, so orthodontic forced eruption was done in which the level of gingival margin remained unaltered while the clinical crown length was increased without impairing the biologic width.

#### **V. Conclusion**

Successful prosthesis is one which restores both esthetics and functions with a healthy periodontium. Periodontal health depends on appropriately designed restorations with correctly placed margins without violating the biologic width. Evidence suggests that even minimal encroachment on sub-gingival tissues leads to deleterious effects on the periodontium. As inter-individual variability exists in the dimensions of biologic width, it has to be evaluated before planning for subgingival placement of the restoration. If dimensions are found to be insufficient, the most appropriate corrective procedure - surgical or orthodontic can be undertaken for establishment of sufficient width. The factors to be considered while placing sub-gingival margins are proper contour, correct polishing and rounding of gingival margins, adequate attached gingiva, careful removal of excess cement, and finally no biologic width encroachment by the restorative margin. Periodic maintenance visits with proper home care are essential for a healthy and functional periodontium around the restored tooth.

#### **References**

- [1]. Gargiulo AW: Dimensions and relations of the dento gingival junction in humans, J Periodontol 1961;**32**:264.
- [2]. Luis Antonia Fellippe, Monteiro Jr, Luis Clovis, Cardoso Viera, Elito Araujo. Reestablishing biologic width with forced eruption. *Quintessence Int* 2003;**34**:733-8
- [3]. Ingber JS, Rose LF, Coslet JG. The "biologic width"—a concept in periodontics and restorative dentistry. *Alpha Omega* 1977; **70**(3):62-5.
- [4]. Nevins M, Skurow HM. The intracrevicular restorative margin, the biologic width, and the maintenance of gingival margin. *INT J Periodont Restor Dent* 1984;**4**:30-49.

- [5]. Valderhaug J, Birkeland JM. Periodontal conditions in patients 5 years following insertion of fixed prostheses. Pocket depth and loss of attachment. *J Oral Rehabil* 1976;3:237-43.
- [6]. Jorgic-Srdjak K, Plancak D, Maricevic T, Drago MR, Bosnjak A. Periodontal and prosthetic aspect of biologic width part I: Violation of biologic width. *ActaStomatol Croat* 2000;34:195-7.
- [7]. Galgali SR, Gontiya G. Evaluation of an innovative radiographic technique - parallel profile radiography to determine the dimensions of the dentogingival unit. *Indian J Dent Res* 2011;22:237-41.
- [8]. Nugala B, Kumar S, Sahitya S, Krishna P M. Biologic width and its importance in periodontal and restorative dentistry. *Journal of Conservative Dentistry*. 2012;15:12-17.
- [9]. Smukler H, Chaibi M. Periodontal and dental considerations in clinical crown extension: A rationale basis for treatment. *Int J PeriodontRestor Dent*.1997;17:464-77
- [10]. Pontoriero R, Carnevale G. Surgical crown lengthening: A 12-month clinical wound healing study. *J Periodontol*.200;72:841-8
- [11]. Potashnick SR, Rosenberg ES. Forced eruption: principles inperiodontics and restorative dentistry. *J Prosthet Dent* 1982;48(2):141-8.