

Immediate implants and immediate loading in full arch maxilla and mandible of a bruxer - A case report

¹Dr Arun Vidyadharan,²Dr Yasufumi Hanawa,³Dr Shibu Godfrey,
⁴Dr Resmi.P.G

¹Head of Dept of Endodontics and Implant dentistry.S.U.T.A.M.S Medical College.Trivandrum.Kerala.India

²Daikanyama Dental Implant Centre.Tokyo.Japan

³Asst Prof at Periodontics.Government Dental College. Calicut.Kerala.India

⁴General Dentist.Ilili Dental Spa.TrivandrumKerala..India

Abstract: *Bruxism is a parafunctional habit which can be severe, moderate or mild. Treating bruxers with dental implants has been challenging by many investigators due to untoward forces imparted on the implants which can cause either failure of implants or complication like fracture of ceramic component of final restoration. This article shows how such patients can be treated by proper planning and good team work between the Surgeon and the Restorative Dentist. Patient compliance, Antero-Posterior (A-P) spread, Cross arch stabilization, Metal Reinforced Provisional and Balanced Occlusion are critical factors to be considered while treating full arch cases in bruxers.*

Keywords: *Immediate loading, Immediate placement, Bruxers, Full arch, Cross arch stabilization*

I. Aim

The aim of this case report was to evaluate the possibility of immediate placement and immediate loading of implants using a cement retained lab processed provisional restoration in full-arch maxilla and mandible of a bruxer.

II. Introduction

Immediate loading (IL) of implants in selected cases has been documented to be a successful procedure in the maxilla and mandible with the literature reporting 85.7-100% survival rates.¹⁻¹¹ The patient and operators desire for a shorter treatment period combined with the documented success of immediately loaded implants encouraged the introduction of immediate loading protocol in fully edentulous patients. Immediate loading is defined as the prosthesis being attached to the implants within one week subsequent to implant placement¹² or on day of surgery with occlusal contact.¹³ Immediate loading of implants on edentulous jaws provides function, esthetics, phonation and psychological satisfaction to the patient on the day of within one week of surgery. The IL protocol can reduce number of surgical interventions and overall treatment time required.^{14, 15, 16}

The critical clinical factors reported for immediate loading in totally edentulous jaws are, undersizing the osteotomy, achieving an insertion torque of at least 35N/cm², implant distribution with the maximum AP (Anteroposterior) spread and cross arch stabilization using a rigid or metal reinforced provisional.^{17,18,19} Splinting has been shown to limit the micro movement of the implant within acceptable limits (<150 micron) leading to an osseointegrated bone healing rather than formation of a fibrous tissue around the implants.²⁰

Operators prefer rough surface, threaded implants²¹ with a minimum 10mm length²² implants for immediate loading cases. The rough surface implants produce more bone-implant contact²³ and friction during implant installation which aid in achieving good primary stability.

Animal²⁴ and human²⁵ biopsy of immediately loaded implants have shown to yield more bone-implant contact around the immediately loaded implants when compared to implants which were not immediately loaded. In the edentulous patient, the literature supports immediate placement and immediate load in the mandible using cross-arch stabilization of the implants and a fixed passive-fitting prosthesis on multiple implants having verifiable primary stabilization upon placement.²⁶

Only few studies show immediate loading of immediate implants in the fully edentulous maxilla and mandible of bruxers. Excess load on a final restoration after successful implant integration can result in implant failure. In addition, fracture of the implant body is a long-term complication often associated with cantilever

restorations or other offset forces on the restoration.²⁷ However, with better patient selection, meticulous treatment planning, atraumatic extraction and operator skill this procedure can be done successfully.

III. Case report

A 72 year old Caucasian male presented to the clinic. His chief complaint was that he was unable to eat properly due to a loose upper bridge and missing teeth in the lower jaw. He wanted fixed teeth in the upper and lower jaw for better chewing.

IV. Medical and dental history

Patient has Type I diabetes. He smokes 5 cigarettes per day for the past 20 years. He has been taking Novolin R since last 10 years for diabetes condition. His last visit to a dentist was 5 months back for teeth extractions in the lower jaw. Patient has nocturnal bruxism habit.

V. Clinical examination

Clinical examination revealed bleeding on probing, generalized deep probing depths, generalized attrition and generalized grade II mobility on tooth number 37,33,32,31,41,42,43 and 44. He was having a long span bridge on the upper jaw from tooth number 17 to 27. The upper bridge was removed. 12,11,21,22 and 23 had grade II mobility and deep probing depths on 22 and 23. The patient was apprised of the poor status of the existing teeth, explained to about extracting teeth and having dental implants. Oral prophylaxis was done.

The patient was sent for CBCT scan to determine the quality and quantity of bone. Digital photographs and a panoramic radiograph (FIG.1) were done to assess the vertical height of the bone and vital structures in the upper and lower jaw. With CBCT scan and Simplant (Columbia Scientific, Inc., Columbia, Maryland, USA) software, the site, length and width of the future implants were planned virtually (FIG.2). The patient was explained about the treatment planning. Placement of eight implants in the mandible and eight to ten implants in the maxilla immediately after teeth extraction and a provisional bridge on the same day was proposed. The decision for placement of eight implants in the mandible instead of the normal 4-6 implants protocol was done as the patient has a history of bruxism and will prosthetically enable second molar occlusion without the need for cantilevers. The anticipated osteoplasty of the alveolar bone height after extraction of the remaining teeth was communicated with the lab. # 37 was planned to be extracted later sometime after the surgical phase as it would serve as a guidance for vertical dimension in occlusion and also act as an anchorage for the surgical guide during surgery.

The patient was informed that the surgical procedure is technique sensitive and an immediate provisionalization is not always possible. In such a scenario the patient might have to wear a denture till the final prosthesis is delivered. The patient was also informed of the importance of diabetic control and the proper maintenance of the upper bridge to avoid periodontal infections during the healing phase.

VI. Laboratory Procedure

A facebow transfer and centric occlusion record were utilized to mount diagnostic casts on a semi adjustable articulator. Diagnostic teeth wax-up was done for a fixed prosthesis. This wax-up was duplicated twice, first to fabricate a custom made surgical guide stent from autopolymerizing resin and second to fabricate the fixed interim prosthesis.

VII. Surgical procedure

The vital signs were recorded. (BP 142/78 mm of Hg, Pulse 72/ min, Respiratory rate 12/ min). The patient was premedicated with 2g Amoxicillin and 2% Chlorhexidine gluconate rinses one hour before surgery. Patient received both intravenous IV sedation and local anesthesia 2% Lidocaine 1: 100000 Adrenaline. Atraumatic extraction of the teeth was done to preserve the buccal bone. A full thickness mucoperiosteal flap was raised (FIG.3). A periodontal probe was used to verify the integrity of the bony walls of the fresh sockets. A thorough socket debridement was done. Ridge preparation guidelines were followed such as (a) reduce knife-edge crest so that ridge is at least 6mm wide (b) reduce depth of sockets so that if the socket is used as an implant site, the implant placement will obliterate the socket or the implant placement will leave a space of 1.5mm or less between the implant and the socket wall and three quarters of the implant surface is in direct contact with host bone (c) the head of the implant is contained within the socket.

Even though with prior CBCT scanning and virtual planning, changes in the final implant position needs to be decided only upon reflection of the flap and checking the osseous contour. At the time of implant placement, surgical flexibility is often necessary to ensure that the treatment goal is ultimately achieved.

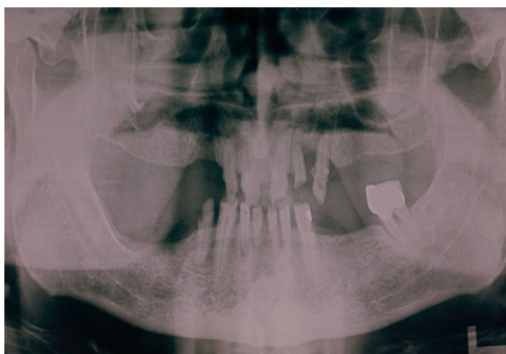In the maxilla nine (Table.1) and mandible eight (Table.2) Biomet 3i (Palm Beach Gardens, FL, U.S.A) Nanotite Certain Parallel implants were placed surgically as virtually planned (FIG.4). Site 11, 21 and 25 did not attain

the required insertion torque. Healing abutments 5×6mm were placed on 11 and 22 sites. Cover screw was placed on 25, buried and let to heal. Site 34 was originally planned as an implant site, but was found to be lacking in the required primary stability due to osseous defect and hence deemed not suitable for loading. A healing abutment 4.1×6 mm was placed. Site 33 had a jumping distance of around 4mm hence bone grafting was done between the implant and socket space (Bioss, Geistlich Pharma, Wolhusen, Switzerland) and a cover screw was placed on the implant. Tension free interrupted vicryl sutures were placed to close the soft tissue flaps. Implant mounts were removed from the remaining implants and conical shaped abutment (FIG.5) with screw of collar height 3 to 5 mm were selected and was tightened at 20 N/cm² onto the implants. Then Titanium alloy Conical shaped temporary cylinder (Quickbridge® titanium cylinder, Biomet 3i) is mounted (FIG.6) over the conical shaped abutment and hand tightened. A plastic cap (Quickbridge® snap cap) made of PEEK (polyether ether ketone) is snapped onto the titanium cylinder. The inner aspect of the lab processed provisional restoration was trimmed or hollowed out (FIG.7).

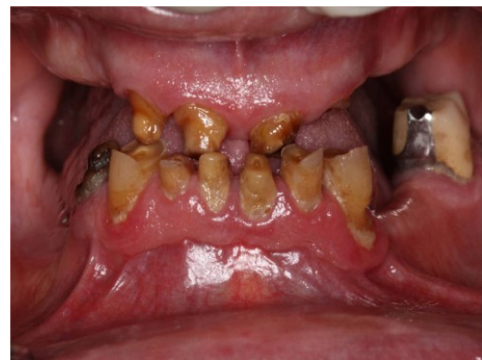Rubber dam was placed over the alveolar ridge below the conical shaped abutments and healing abutment to prevent acrylic from flowing into the soft tissue area. The hollowed out lab processed acrylic provisional was filled with Bis-acrylic Luxatemp (n=9, DGM, Hamburg, Germany) and seated onto the Quickbridge® caps. The material was allowed to set as per the manufacturer's instruction. The provisional bridge with the incorporated Quickbridge caps was removed, trimmed and polished outside the patient's mouth (FIG.8). Acrylic in the provisional over the healing abutment was relieved to avoid loading. Rubber dam was removed. The Snap-on Caps were filled with Durelon (3M ESPE, Pennsylvania, USA) and luted onto the Titanium cylinders (FIG.9). After setting, excess cement was removed carefully to avoid any irritation to the wound which might lead to implant failure.

Post operative instruction

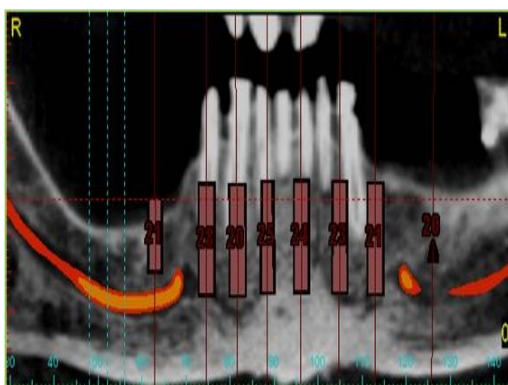
Patient was advised soft diet for 12-16 weeks. Avoid brushing the area for the first 1-2 weeks. 7 days with amoxicillin (500 mg *q.i.d.*) was prescribed. Hydrocodone with acetaminophen was given for management of pain. Was advised to use 2% Chlorhexidine gluconate mouthwash for 1 week. Contact if any crackling, breakage or loosening of the prosthesis is noted. Routine follow up 1- 2 weeks the first month, then monthly thereafter for 6 months. Yearly follow ups were advised after the final restoration.



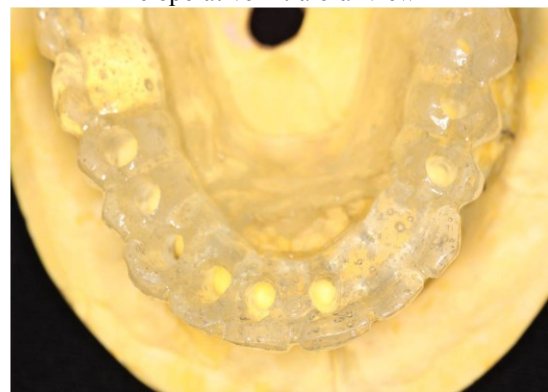Fig(1):-
Pre operative O.P.G



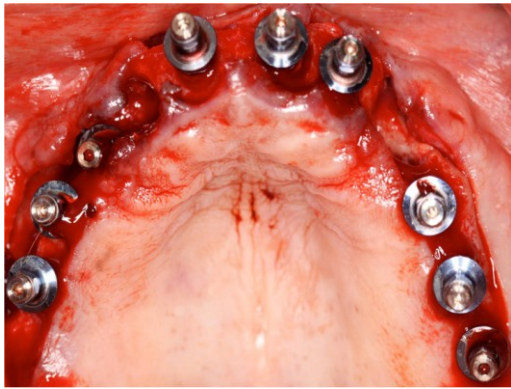
Fig(2):-
Pre operative intra oral view



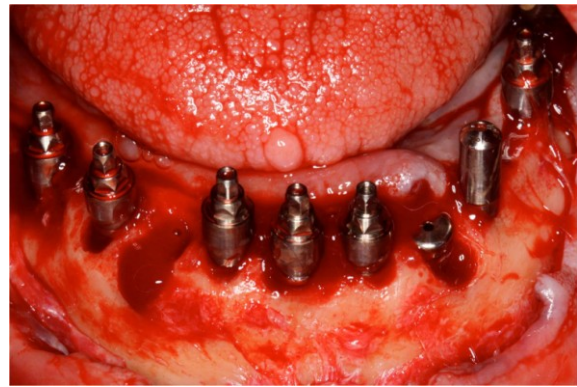
Fig(3):-
Simplant Software Virtual Planning



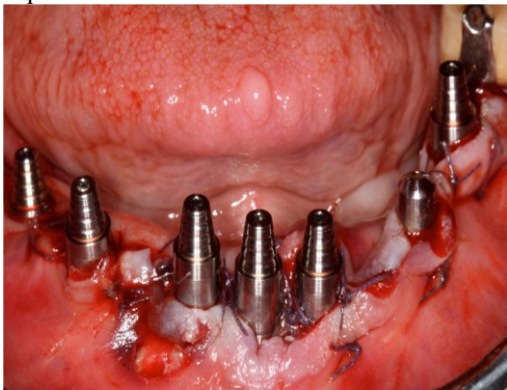Fig(4):-
Surgical Stent



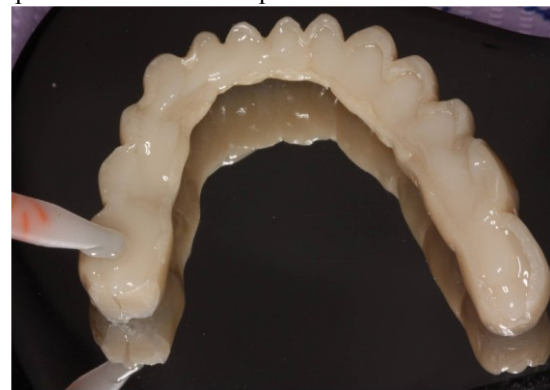Fig(5):-
Implants with mounts in the maxilla



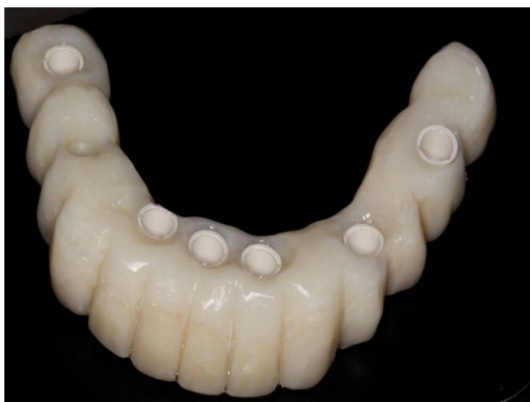Fig(6):-
Implants with conical shaped abutments in mandible



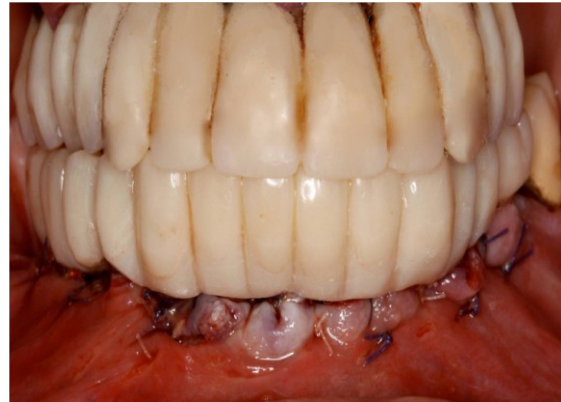
Fig(7):-
Implants with conical shaped temporary cylinder
In the mandible



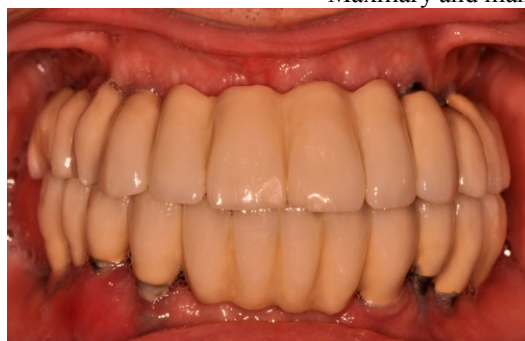Fig(8):-Hollowed provisional filled with Bis-
Acrylic-Luxatemp



Fig(9):-
Provisional with Snap Cap



Fig(10):-
Maxillary and mandibular Provisionals delivered



Fig(11):-
3 year follow-up after final restorations

Table 1.

No.of implants	Site	Implant dimension	Insertion torque
1.	11	4 x 15mm	30N/cm ²
2.	12	4 x 13mm	35N/cm ²
3.	14	4 x 15mm	40N/cm ²
4.	15	4 x 10mm	40N/cm ²
5.	16	4 x 10mm	35N/cm ²
6.	21	4 x 15mm	30N/cm ²
7.	23	4 x 15mm	40N/cm ²
8.	24	4 x 10mm	40N/cm ²
9.	25	4 x 10mm	30N/cm ²

Table 2.

No.of implants	Site	Implant dimension	Insertion torque
1.	31	4 x 15	40N/cm ²
2.	33	4 x 15	40N/cm ²
3.	34	3.25 x 13	30N/cm ²
4.	36	4 x 10	40N/cm ²
5.	41	4 x 15	40N/cm ²
6.	43	4 x 15	40N/cm ²
7.	45	4 x 15	40N/cm ²
8.	46	4 x 10	40N/cm ²

VIII. Discussion

Parafunction may be categorized as absent, mild, moderate, or severe. Bruxism is defined as nonfunctional grinding of teeth in a horizontal direction, which is the most significant biomechanical stress factor. The forces involved are in excess of normal physiologic masticatory loads. Bruxism and clenching are the most critical factors to evaluate prior to implant reconstruction. Long-term success is not predictable in the presence of severe Bruxism or clenching. This does not mean that patients who brux or clench cannot be successfully treated. In this patient, the maxillary and mandibular bone quality and quantity which is a deciding factor in achieving good primary stability for immediate loading was favourable. However, a careful pretreatment evaluation of these conditions, patient education as to the possible resulting complications and treatment, need to be established before treatment is initiated.

A bruxing patient is at greater risk for implant fracture over time because the magnitude of the force will increase as the muscles become stronger and the number of cycles accumulates. Therefore grade 5 titanium alloy implant which is twice as strong as grade 3 CP titanium is recommended for bruxers. The prosthesis should be designed to improve the distribution of stress on the implants. The surgeon should insert the implants perpendicular to the curves of Wilson and Spee, and the restoring dentist should, when possible, place centric vertical contacts aligned with the long axis of the implant body.²⁸

The occlusal scheme of the provisional followed was a balanced occlusion with minimal load on lateral excursions to prevent untoward forces during mastication. A shallow anterior overbite, reduced incisal guide angle, reduced posterior cusp height, reduced posterior occlusal table width and anterior guidance to prevent nonfunctional or balancing occlusal contacts in lateral jaw movements was incorporated in the provisional.

In an immediate implant placement procedure the extraction sockets itself act as a guide for osteotomy. Hence the site for drilling is much more simplified during the surgery. In this case report sufficient number of implants were placed and widely distributed to allow construction of a fixed prosthesis in case some of the prematurely loaded implants fail during the healing phase. The use of fixed implant supported prosthesis during the healing phase may provide an additional benefit to the unloaded implants in that the prosthesis forms a protective shield over the soft tissue area and direct implant contact is avoided.²⁹ A recent review concluded that bruxism would not create any biological complications around implants while it is more likely to be a risk factor for mechanical complications.³⁰ Long-term success is not predictable in the presence of severe bruxism or clenching. This does not mean that patients who brux or clench cannot be successfully treated. However, a careful pretreatment evaluation of these conditions, patient education as to the possible resulting complications and treatment, need to be established before treatment is initiated. Strict periodontal maintenance phase was undergone post operatively. Diabetes, poor compliance to prevention, smoking, bruxing and a history of advanced periodontitis are significant risk factors for implant loss. At each visit periodontal indexes such as bleeding on probing and probing depth measurements were checked as well as mucogingival and prosthetic changes, and the patient's plaque control performance. A night guard to control parafunction, occlusal wear, and excessive loading of the implants was planned after the provisional's are replaced with a fixed-hybrid restoration.

IX. Conclusion

The caution that is urged when using implants to support dental prosthesis in bruxers is due to the common fear that bruxism can cause overloading and may lead to implant failure. Patient compliance, lab and operator skill and good team work during the treatment is the key to successful management of such a case. Meticulous treatment planning with diagnostic tools like CBCT and 3-dimensional implant virtual planning software help the surgeon, restorative dentist, and technician to visually plan prior to the surgical and restorative treatment and overcome the complications which may be encountered with bruxism habit.

References

- [1]. Schnitman PA, Wöhrle PS, Rubenstein JE, DaSilva JD, Wang NH. Ten-year results for Brånemark implants immediately loaded with fixed prostheses at implant placement. *Int J Oral Maxillofac Implants* 1997; 12:495-503.
- [2]. Tarnow DP, Emtiaz S, Classi A. Immediate loading of threaded implants at stage 1 surgery in edentulous arches: ten consecutive case reports with 1-to 5-year data. *Int J Oral Maxillofac Implants* 1997;12:319-324.
- [3]. Ganeles J, Rosenberg MM, Holt RL, Reichman LH. Immediate loading of implants with fixed restorations in the completely edentulous mandible: Report of 27 patients from a private practice. *Int J Oral Maxillofac Implants* 2001; 16:418-426.
- [4]. Gallucci GO, Bernard JP, Bertosa M, Belser UC. Immediate loading with fixed screw-retained provisional restorations in edentulous jaws: The pickup technique. *Int J Oral Maxillofac Implants* 2004;19:524-533.
- [5]. Jaffin RA, Kumar A, Berman cl. Immediate loading of dental implants in the completely edentulous maxilla: a clinical report. *Int J Oral Maxillofac Implants*.2004; 19:721-730
- [6]. Degidi M, Perrotti V, Piattelli A. Immediately loaded titanium implants with a porous anodized surface with at least 36 months of follow-up. *Clin Implant Dent Relat Res* 2006;8:169-177.
- [8]. Drago CJ, Lazzara RJ. Immediate occlusal loading of Osseotite implants in mandibular edentulous patients: A prospective observational report with 18-month data. *J Prosthodont* 2006;15:187-194.
- [9]. Capelli M, Zuffetti F, Del Fabbro M, Testori T. Immediate rehabilitation of the completely edentulous jaw with fixed prostheses supported by either upright or tilted implants: A multicenter clinical study. *Int J Oral Maxillofac Implants* 2007;22:639-644.
- [10]. Ostman PO. Immediate/early loading of dental implants. Clinical documentation and presentation of a treatment concept. *Periodontol* 2000 2008;47:90-112.
- [11]. De Bruyn H, Van de Velde T, Collaert B. Immediate functional loading of TiOblast dental implants in full-arch edentulous mandibles: A 3-year prospective study. *Clin Oral Implants Res* 2008;19:717-723.
- [12]. Gallucci GO, Morton D, Weber HP. Loading protocols for dental implants in edentulous patients. *Int J Oral Maxillofac Implants* 2009;24:132-146.
- [13]. Weber HP, Morton D, Gallucci GO, Rocuzzo M, Cordaro L, Grutter L. Consensus Statements and Recommended Clinical Procedures Regarding Loading Protocols. *The International Journal of Oral & Maxillofacial Implants*. 2009;24:180-183.
- [14]. Bocklage R. Rehabilitation of the Edentulous Maxilla and Mandible with Fixed Implant-Supported Restorations Applying Immediate Functional Loading: A Treatment Concept. *Implant dentistry*. 2002;11:154-158.
- [15]. Schnitman PA, Wöhrle PS, Rubenstein JE, DaSilva JD, Wang NH. Ten-year results for Brånemark implants immediately loaded with fixed prostheses at implant placement. *Int J Oral Maxillofac Impl*. 1997;2:495-503.
- [16]. Ostman PO. Immediate/early loading of dental implants. Clinical documentation and Presentation of a treatment concept. *Periodontol* 2000 2008;47:90-112.
- [17]. Misch CM. Immediate loading of definitive implants in the edentulous mandible using a fixed provisional prosthesis: The denture conversion technique. *J Oral Maxillofac Surg* 2004;62:106-115.
- [18]. Bocklage R. Rehabilitation of the edentulous maxilla and mandible with fixed implant-supported restorations applying immediate functional loading: a treatment concept. *Implant Dentistry* 2002;11:154-158.
- [19]. Salama H, Rose LF, Salama M, Betts NJ. Immediate loading of bilaterally splinted titanium root-form implants in fixed prosthodontics. A technique reexamined: two case reports. *Int J Periodontics Restorative Dent*. 1995;15:344-361.
- [20]. Tarnow DP, Emtiaz S, Classi A. Immediate loading of threaded implants at stage 1 surgery in edentulous follow up data. *Int J Oral Maxillofac Implants*. 1997;12:319-324.
- [21]. Romanos GE. Present status of immediate loading of oral implants. *Journal of oral implantology*. 2004; 30:189-197.
- [22]. Hom-Lay Wang, Zeev Ormianer, Ady Palti, Morton L. Perel, Paolo Trisi, Gilberto Sammartino. Consensus Conference on Immediate Loading: The Single Tooth and Partial Edentulous Areas *Implant dentistry*, 2006, v. 15, No.4.
- [23]. Goiato MC, Pellizzer EP, dos Santos DM, Barão VA, de Carvalho BM, Magro-Filho O, Garcia IR Jr. Clinical Viability of Immediate Loading of Dental Implants: Part I-Factors for Success. *Journal of Craniofacial Surgery*. 2009; 20:2139-2142.
- [24]. Piattelli A, Paolantonio M, Corigliano M, Scarano A. Immediate loading of titanium plasma-sprayed screw-shaped implants in man: A clinical and histological report of two cases. *J Periodontol* 1997;68:591-7.
- [25]. Romanos GE, Toh CG, Siar CH, Swaminathan D. Histologic and histomorphometric evaluation of peri-implant bone subjected to immediate loading: an experimental study with Macaca fascicularis. *The International Journal of Oral & Maxillofacial Implants* [2002, 17(1):44-51]
- [26]. Degidi M, Scarano A, Petrone G, Piattelli A. Histologic analysis of clinically retrieved immediately loaded titanium implants: a report of 11 cases. *Clin Implant Dent Relat Res*. 2003; 5(2):89-93.
- [27]. Chiapasco M. Early and immediate restoration and loading of implants in completely edentulous patients. *Int J Oral Maxillofac Implants* 2004; 19 (suppl):76-91.
- [28]. Bidez MW, Misch CE. Force transfer in implant dentistry: basic concepts and principles. *Oral Implantol*. 1992; 18:264-274.
- [29]. Misch CE. Dental evaluation factors of stress. In: CE Misch, ed. *Contemporary Implant Dentistry*. 2nd ed. St Louis, Mo: CV Mosby; 1999.
- [30]. Balshi T, Wolfinger J, Immediate loading of Branemark implants in the edentulous mandible: a preliminary report. *Implant Dent*. 1997 Summer; 6(2):83-8.
- [31]. Yoon J, Mehta N, Rosen A et al, Effect of bruxism on success rate of dental implants, *Journal of dental research*, 74, 1995, pp. 478-478.
- [32]. Manfredini D, Poggio CE, Lobbezoo F. Is Bruxism a Risk Factor for Dental Implants? A Systematic Review of the Literature. *Clinical Implant Dentistry and Related Research*. 2014;16(3):460-9.