

Implants separated by less than 2mm in the posterior mandible

Basel Azar DDS, MSc, Fadi Makhoul DDS, Shadi yazigi DDS, MSc,

MU Dr Radek Mounajjed, PHD

¹*Department of Oral and Maxillofacial surgery, Damascus University-Syria. Department of prosthetic dentistry, Palacky university-Czech republic*

²*Department of Oral and Maxillofacial surgery, Damascus University-Syria.*

³*Department of Oral and Maxillofacial surgery, Damascus University-Syria.*

⁴*Department of prosthetic dentistry, Palacky university-Czech republic*

Abstract: *Interimplant distance is one of the factors influencing crestal bone resorption. In addition , Several studies have shown the ability of microthreads and platform switching to minimize crestal bone resorption around implants. This report shows microthreaded and platform switched implants separated by less than 2mm in the posterior mandible.*

Keywords: *Microthreads , Platform switching*

I. Introduction:

Interimplant distance is one of the factors influencing crestal bone resorption. A decrease in interimplant distance could result in overlap of resorptions on adjacent implants which in turn could result in vertical resorption of interimplant bone peak and increase in the distance between the bone crest and the contact point of adjacent crowns . Consequently, the interimplant papilla will have less chance to fill the space(Tarnow et al., 2000).

The design of the implant neck plays a major role in crestal bone resorption around implants . One example is the addition of microthreads to the implant neck could lead to more stable bone levels(Nickenig et al., 2009), and this phenomenon is explained by the conversion of shear forces into compressive forces which is favorable to cortical bone(Hudieb et al., 2011).

The Inward shifting of the implant-abutment junction (Platform switching) leads to less resorption around dental implants , and this could be explained by the fact that this technique results in a distance between the implant-abutment junction (microgap) and its associated inflamed connective tissue and the crestal bone(Jung et al., 2008).

In this case report , we report microthreaded and platform –switched implants separated by less than 2mm in the posterior mandible.

II. Report of a case:

A generally healthy 40 year old patient was referred to the Department of Oral&Maxillofacial Surgery at Damascus University for implant insertion. The patient had an edentulous area in the right posterior mandible with a history of first molar extraction 3 months ago. A panoramic x-ray was taken to check the quantity of bone in the candidate areas for implantation which showed good height of bone above the inferior dental canal.

A crestal incision was made and a mucoperiosteal flap was raised to expose the underlying bone. Three implant osteotomies were prepared and three implants inserted. The mesial and middle implants were inserted in the mesial and distal sockets of the first molar , whereas the distal implant was inserted further distally. The implants were exposed 3 months later and 3 splinted porcelain-metal crowns were delivered 1 month later.

The values of clinical indices { Modified Plaque Index(Mombelli and Lang, 1994), Modified Bleeding Index (Mombelli and Lang, 1994), and Attachment Level} were recorded every 3 months in the first functional year . A digital periapical radiograph was taken immediately after implant insertion and another radiograph was taken 2 years after loading.

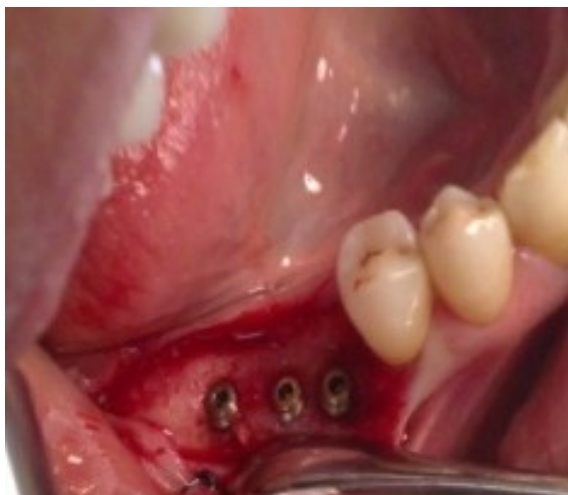

Fig 1: implants inserted in their osteotomies

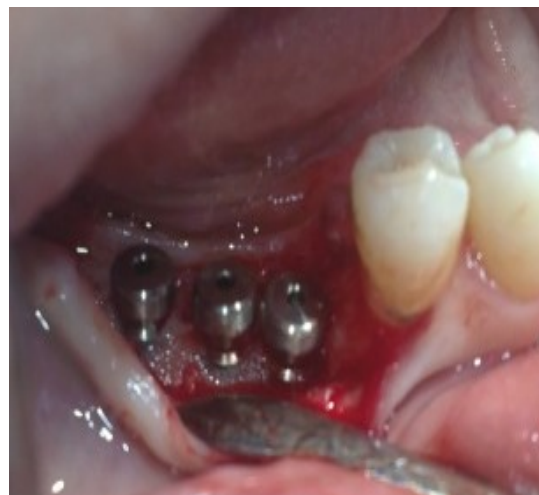

Fig 2: implants exposure and connection of healing abutments

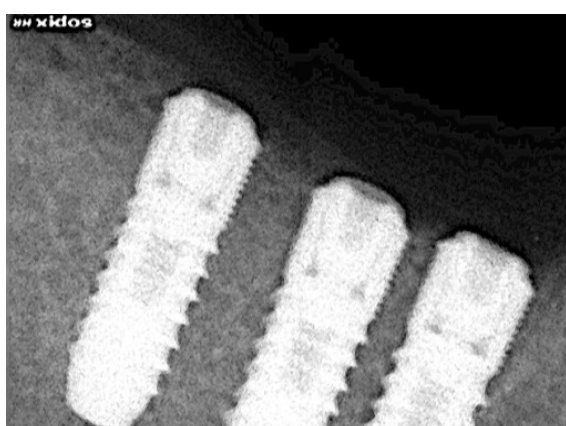


Fig 3: Radiograph after implant insertion




Fig 4: Radiograph 2 years after loading

III. Discussion:

The values of clinical parameters were normal around the three implants as there were no value of plaque or bleeding ≥ 2 , and the attachment level remained stable between prosthesis delivery and 2 years after loading. This could be explained by the careful monitoring of the patient and the oral hygiene instructions that were followed by the patient.

A decrease in interimplant distance to less than 3mm could result in overlap of resorptions on adjacent implants which in turn could result in vertical resorption of interimplant bone peak (Tarnow et al., 2000). The interimplant distance in our case was less than 2mm and the bone levels were stable which could be related to the design of implants that had microthreaded necks and were restored by platform switching technique which contributed to the reduced bone reorption around the implants.

Our result is in accordance with the studies of Elian et al, Novaes et al, Oliviera et al, who did their researches on animals. Their implants were placed adjacent to each other with less than 3 mm in between. The implants had platform-switched abutments which the authors claim to save the crestal bone surrounding the implants from resorption after loading. (de Oliveira et al., 2006)(Elian et al., 2011)(Novaes et al., 2006).

IV. Recommendations:

This case report is consistent with the idea that the incorporation of microthreads on the implant neck, as well as platform switching on the prosthetic abutment can help reduce or even stop the bone resorption process around the dental implants after loading. We suggest a controlled clinical study with a large sample size to support our findings.

References:

- [1]. DE OLIVEIRA, R. R., NOVAES, A. B., JR., PAPALEXIOU, V., MUGLIA, V. A. & TABA, M., JR. 2006. Influence of interimplant distance on papilla formation and bone resorption: a clinical-radiographic study in dogs. *J Oral Implantol*, 32, 218-27.
- [2]. ELIAN, N., BLOOM, M., DARD, M., CHO, S. C., TRUSHKOWSKY, R. D. & TARNOW, D. 2011. Effect of interimplant distance (2 and 3 mm) on the height of interimplant bone crest: a histomorphometric evaluation. *J Periodontol*, 82, 1749-56.
- [3]. HUDIEB, M. I., WAKABAYASHI, N. & KASUGAI, S. 2011. Magnitude and direction of mechanical stress at the osseointegrated interface of the microthread implant. *J Periodontol*, 82, 1061-70.
- [4]. JUNG, R. E., JONES, A. A., HIGGINBOTTOM, F. L., WILSON, T. G., SCHOOLFIELD, J., BUSER, D., HAMMERLE, C. H. & COCHRAN, D. L. 2008. The influence of non-matching implant and abutment diameters on radiographic crestal bone levels in dogs. *J Periodontol*, 79, 260-70.
- [5]. MOMBELLI, A. & LANG, N. P. 1994. Clinical parameters for the evaluation of dental implants. *Periodontol 2000*, 4, 81-6.
- [6]. NICKENIG, H. J., WICHMANN, M., SCHLEGEL, K. A., NKENKE, E. & EITNER, S. 2009. Radiographic evaluation of marginal bone levels adjacent to parallel-screw cylinder machined-neck implants and rough-surfaced microthreaded implants using digitized panoramic radiographs. *Clin Oral Implants Res*, 20, 550-4.
- [7]. NOVAES, A. B., JR., PAPALEXIOU, V., MUGLIA, V. & TABA, M., JR. 2006. Influence of interimplant distance on gingival papilla formation and bone resorption: clinical-radiographic study in dogs. *Int J Oral Maxillofac Implants*, 21, 45-51.
- [8]. TARNOW, D. P., CHO, S. C. & WALLACE, S. S. 2000. The effect of inter-implant distance on the height of inter-implant bone crest. *J Periodontol*, 71, 546-9.