

## Two years outcome of cemented Austin Moore hemiarthroplasty for fracture neck femur

Dr. Anshu Shekhar<sup>1</sup>, Dr. Gururaj Murgod<sup>2</sup>, Dr. Suresh Korlhalli<sup>3</sup>

<sup>1</sup>(Assistant Professor, Department of Orthopaedics, Sri Dharmasthala Manjunatheshwara College of Medical Sciences and Hospital, Dharwad, Karnataka, India)

<sup>2</sup>(Assistant Professor, Department of Orthopaedics, Karnataka Institute of Medical Sciences, Hubli, Karnataka, India)

<sup>3</sup>(Professor, Department of Orthopaedics, Karnataka Institute of Medical Sciences, Hubli, Karnataka, India)

---

**Abstract :** 47 consecutive cases of fracture neck femur in patients older than 70 years were managed by cemented hemiarthroplasty with Austin Moore prosthesis at a tertiary care teaching hospital with the objectives of studying the short come outcome and to compare the results with standard studies using uncemented Austin Moore prosthesis, to determine if cementing the prosthesis improves clinical outcome. Patients who were available for follow up for a minimum of two years have been included in this study. Short term functional outcome was analyzed using the Harris hip scoring system. 44 patients were available for follow up at the end of study period. The patients were in the age group of 72 to 93 years with the mean age of 78.2 years. 59% of the patients were females with 88.6% of all cases sustaining the fracture following a trivial trauma. The functional outcome using the Harris hip score was excellent in 43.5%, good in 38.4%, fair in 11.3% and poor in 6.8% of the cases. There was no case of bone cement implantation syndrome. Hemiarthroplasty with Austin Moore prosthesis is a good option in elderly patients with limited physical demands and mobility. Cementing the prosthesis can achieve better control of thigh pain, improves mobility, allows early mobilization and lesser use of walking aids. The use of cement does not increase perioperative mortality or morbidity in patients without severe cardiopulmonary compromise.

**Keywords:** Bone cement, Femoral neck fracture, Frail elderly, Hemiarthroplasty, Prosthesis implantation

---

### I. INTRODUCTION

Femoral neck fractures, one of the most common injuries in the elderly, have always presented great challenges to orthopaedic surgeons. The incidence of these fractures has increased with improvement in life expectancy and is expected to double in the next 20 years and triple by 2050[1]. The goal of treatment of femoral neck fractures is restoration of pre-fracture function without associated morbidity [2]. Experience of the last four decades has shown that hip arthroplasty is the best treatment for intracapsular fracture neck of femur in elderly in terms of both short-term and long-term results [3]. Currently, surgeons can choose between unipolar hemiarthroplasty, bipolar hemiarthroplasty and total hip arthroplasty in the treatment [4]. Unipolar hemiarthroplasty with Austin Moore prosthesis is rarely employed in the developed countries though it is very commonly used in developing countries like India. It should ideally be reserved for very limited or non-ambulatory patients.[5] Though a Thompson's prosthesis is usually used with cement, Austin Moore's prosthesis can be used in the presence of calcar. We have taken up this study to evaluate if using bone cement with the Austin Moore's prosthesis offers any distinct advantages in reducing the complications of thigh pain, stem loosening and improving mobility.

### II. MATERIALS AND METHODS

2.1 Source of data: Patients with intra-capsular fractures of the neck of femur satisfying inclusion criteria admitted in a medical college hospital during the study period of June 2010 to October 2011. Approval from the institutional ethics committee was obtained prior to commencement of the study.

2.2 Sample size: 47 patients were included in the study. However, only 44 patients were available for follow up at two years and included in the final analysis.

2.3 Inclusion criteria: Intra-capsular fracture of the neck of femur and age above 70 years.

2.4 Exclusion criteria: Patients with arthritic changes involving the acetabulum, pathological fractures, not willing or unfit for surgery and cementing.

2.5 Collection of data: Patients satisfying the inclusion criteria were worked up and investigations performed as per protocol. Informed written consent from all patients was taken prior to any intervention.

2.6 Surgical procedure: All surgeries were done under spinal or epidural anaesthesia according to the discretion of the anaesthetist. Posterior approach to the hip was used in all cases and single dose intravenous Cefuroxime was administered pre-operatively. The prosthesis used in this study is a standard Austin Moore prosthesis. An

appropriate size bone plug from the resected head was inserted into the medullary canal after broaching. 40 gram bone cement was inserted with a cement gun without pressurization.

2.7 Post operative protocol: Most of our study patients were mobilized in bed on day one after surgery with weight bearing walking as tolerated using a walker, within the 72 hours. Intravenous Cefuroxime was used in all patients for five days.

2.8 Follow up: Regular follow up of all cases was done at 6 weeks, 3 months, 6 months, 12 months, 18 months and two years. At each follow up, patients were evaluated clinically using the Harris Hip Score [6] and radiologically to detect any loosening, heterotrophic ossification, subsidence of the prosthesis and protrusio acetabuli.

### III. RESULTS

47 patients were treated by hemiarthroplasty with Austin Moore prosthesis with bone cement for fracture neck of femur of which 44 patients were available for follow up till two years. Three patients died during the follow up period and were excluded from final analysis.

The average age of patients in this study was 78.2 years (72 -93 years). 59% of the patients were women. Left side fracture was seen in 54.5% of the cases. 39 patients sustained fracture following a slip while 5 patients met with RTA. 31 patients had at least one systemic disease, the commonest being hypertension (43.2%). 25% patients presented within 24 hours of the injury whereas 27.3% presented more than one week later (Table 1).

Four patients developed peri-operative hypotension which was managed appropriately. There was one case of peri-prosthetic fracture which was Vancouver Type A<sub>G</sub> [7] i.e. cortical perforation in the greater trochanteric area with stable prosthesis. It was managed by passing a stainless steel wire of 16 gauge, besides cementing the prosthesis to secure the fixation. There was no case of any bone cement related complication. Postoperatively, shortening was observed in three patients. Superficial infection in the form of a wound dehiscence was seen in two patients, one of who was a diabetic. Both patients were managed by debridement, secondary suturing and appropriate intravenous antibiotics. The infection resolved without any sequelae in both cases. One patient had a calf vein thrombosis post-operatively. There were no late postoperative complications like loosening, dislocation, erosion, calcar resorption, protrusio acetabuli or peri-prosthetic fracture noted at two years (Table 2).

The average Harris Hip Score at 6 weeks after surgery was 57.18 (43.83-66.65), at the 3 months was 67.66 (51.06-83.88), at 6 months 77.53 (57.45- 88.8). At one year, the average score rose to 82.64 (65.8-92.9), at 18 months it was 84.53 (65.8- 93) and at final two year follow up it as 85.14(66.2- 94.3). The final result based on the Harris Hip Score is summarized in Table 3.

Radiological assessment revealed that 12 patients had femur with Dorr type B morphology (27.3%) whereas 32 patients (72.7%) had a Dorr type C femur [8]. Post operative radiographs were studied for implantation errors [9] and metaphyseal fill [10], which is summarized in Table 4.

### IV. TABLES

**TABLE 1: PRE-OPERATIVE ASSESSMENT OF STUDY POPULATION**

Sl. No.	Characteristic		No. of patients	Percentage
1.	AGE	70- 75 years	12	27.3%
		75-80 years	18	40.9%
		>80 years	04	9%
2.	SEX	Male	18	41%
		Female	26	59%
3.	MODE OF INJURY	Slip	39	88.6%
		Road Traffic Accident	5	11.4%
4.	LATERALITY	Right	20	45.5%
		Left	24	54.5%
5.	TIME TO PRESENTATION	< 24 hours	11	25%
		24-72 hours	14	31.8%
		72 hours – 1 week	7	15.9%
		>1 week	12	27.3%
6.	SYSTEMIC CO-MORBIDITIES	Ischaemic heart disease	3	6.8%
		Hypertension	19	43.2%
		Diabetes mellitus	8	18.2%
		Chronic lung disease	3	6.8%
		Others	4	9.1%

**TABLE 2: COMPLICATIONS DURING THE STUDY**

Time	Complication	No. of patients
PERI-OPERATIVE	Hypotension	4
	Peri prosthetic fracture	1
EARLY POST-OPERATIVE	Shortening	3
	Superficial infection	2
	Deep vein thrombosis	2

**TABLE 3: FINAL HARRIS HIP SCORE AND CLINICAL RESULT**

Grade	Harris Hip Score	No. of patients	Percentage
Excellent	90-100	9	43.5%
Good	80-89	27	38.4%
Fair	70-79	5	11.3%
Poor	<70	3	6.8%

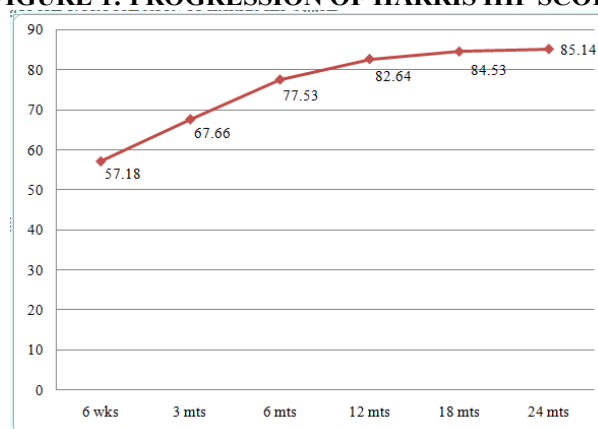
**TABLE 4: RADIOGRAPHIC ASSESSMENT**

	Parameter	No. of patients	Percentage
PROXIMAL FEMUR MORPHOLOGY (DORR)	A	0	0
	B	12	27.3%
	C	32	72.7%
IMPLANTATION ERRORS	Inadequate neck length	2	9.09%
	Inadequate calcar seating	2	9.09%
	Peri prosthetic fracture	1	4.5%
METAPHYSEAL FILL	<= 70 percent	8	18.2%
	>70 percent	36	81.8%

**TABLE 5: COMPARISON OF CLINICAL RESULT WITH STANDARD STUDIES WITH UNCEMENTED AUSTIN MOORE PROSTHESIS**

Grade	Our study	Jensen[12]	Jadhav[14]	Moore[17]	Dhar[18]	Noor[19]
Excellent	43.5%	30%	65%	31.6%	80.2%	38%
Good	38.4%	21.6%		43.3%		21%
Fair	11.3%	43.3%	35%	16.6%	19.8%	24%
Poor	6.8%	5%		8.3%		17%

**FIGURE 1: PROGRESSION OF HARRIS HIP SCORE**



## V. DISCUSSION

The aim of replacement surgery in fracture neck femur is early return to daily activities and pre fracture levels. This is particularly applicable to the elderly age group where complications related to prolonged immobilization need to be prevented.

The mean age of the patients in the present study was 78.2 years. Some authors have advocated hemireplacement in patients over 70 years of age [11-13]. This age limit is arbitrary and can be justifiably reduced when the younger patient is in poor health or has a low activity level. The average age of patients in our series is higher than other Indian series viz. 65.7 years [14], 66 years [13], and 66.3 years [15]. Unipolar hemiarthroplasty with Austin Moore prosthesis is reserved for elderly patients with minimal functional demands and is done primarily for pain relief rather than function [16].

As in other standard studies,[12-15, 17-19] the present study also had a higher number of females. This is due to the lower peak bone mass and postmenopausal bone loss in women [21]. Women have a skeleton that adapts less well to ageing by periosteal apposition [22,23]. Majority of our study patients (88.6%) sustained the

injury due to a trivial trauma like tripping or slipping. This is in accordance with the series by Evans[24] and Ingalkar [25]. Falls are a common event, particularly among the elderly. Epidemiologic studies have identified a number of risk factors for this like weakness, balance deficit, gait disorder, visual deficit, etc.[21] A little more than half of our study patients were brought to the hospital within three days of sustaining the injury whereas 27.3% presented for treatment after one week or more. This is a common scenario in our country where patients present to an orthopaedician late, after trying treatment from osteopaths. In all, 70.5% of the patients had at least one medical co-morbidity, the most common being hypertension, seen in 43.2% of patients. This is lower than the 83.3% patients in the series by Noor et al[19] but more than the 64.5% reported by Saxena et al[13] It was observed that the post-operative rehabilitation of patients was significantly affected by the presence of the above co-morbidities. This also had an effect on the final functional result of the procedure. Similar observations have been made by Koval et al[26] and Bath [27].

Though the dislocation rate is reported to be more with the posterior approach, none of our study patients had a post-operative dislocation of the prosthesis.[27,28] This was because meticulous attention was given to insertion of prosthesis in 15-20 degrees anteversion, valgus positioning, suturing the posterior capsule and the short external rotators and keeping the limb in slight abduction post-operatively. Patients were also explained in the immediate post-operative period about the risk of dislocation and were advised not to squat or sit cross leg.

Technical difficulties encountered during the procedure were miscalculation of the amount of neck to be resected resulting in the prosthesis sitting on the lesser trochanter and subsequent shortening in three cases. There was one case of peri prosthetic fracture, Vancouver Type A<sub>G</sub>[7] i.e. cortical perforation in the greater trochanteric area with stable prosthesis. This patient later went on to develop superficial wound infection. Weinrauch et al[29] and Parker et al [30], have reported a statistically significant increased incidence of peri prosthetic fractures in uncemented Austin Moore prosthesis compared to cemented Thompson prosthesis. Figved et al[31] and Fraser Taylor et al [32] in their series comparing cemented and uncemented bipolar hemiarthroplasty also found significantly higher intra operative periprosthetic fractures in the uncemented groups and both these are Level II studies.

All the surgeries were completed between 45-90 minutes of starting the procedure. Emery et al[33], Figved et al[31], Parker et al[30] and Fraser Taylor et al [32] found increased surgery duration and blood loss in the cemented groups but none of the findings were statistically significant. Neither the intra-operative blood loss nor the duration of the procedure had any effect on final function. Two of our patients (4.5%) had superficial wound infection. Infection rates reported in other series have ranged from 4.5% by D'Arcy[34], 4.7% by Jensen and Holstein[12] to 5.7% by Dhar[18] and 6.1% by Saxena and Saraf[13]. Parker et al reported no increase in infection rates in the cemented hemiarthroplasty group[30].

There was no case of any cement related complication like hypotension, pulmonary embolism or cardiac arrest. The rationale for avoiding the use of cement comes from previous studies linking cementing to perioperative death and cardiopulmonary complications [35,36]. Studies by Figved et al [31], Parker et al [30], Kankanala et al[37], Costa et al[38] and Taylor et al[32] have conclusively proven that cementing a hemiarthroplasty stem does not lead to a significant rise in cardiopulmonary complications or death in carefully selected patients. As suggested by Donaldson et al [39], the surgical risk reduction for bone cement implantation syndrome in this study by thorough wash of the medullary canal, meticulous hemostasis and no pressurization. Also, none of the patients in the study population had severe cardiopulmonary compromise.

In our study, the final Harris Hip Score as evaluated at two years follow-up averaged 85.14 with the maximum score being 94.3. Overall, about 82% of the patients achieved an excellent or good result. Our results are better compared with previous studies of uncemented hemiarthroplasty with Austin Moore prosthesis performed for fracture neck femur as seen in Table 5.

Sonne-Holm et al [20], comparing Moore arthroplasty with and without cement, found that the patients with cemented Moore arthroplasties had a superior hip function during first 6 months of follow up. In this study, the Merle d' Aubigne total hip index was significantly higher for patients with cemented hemiarthroplasty, due mainly to less pain and better gait function. Anderson et al[40] Branfoot et al[41] and Singh et al[42] performed randomized studies to compare outcome of cemented versus uncemented Thompson prosthesis and they reported significantly more pain in the uncemented group. Emery et al[33], on comparing cemented Thompson and uncemented Moore stems also found better pain scores with the cemented prosthesis. The increased use of walking aids after cement less fixation has also been reported by the authors. Lausten and Vedel [43] reported significantly lower mobility and social performance scores in their uncemented group. Parker et al [30] in the largest randomized trial to date comparing a cemented and uncemented unipolar hemiarthroplasty, also concluded that cemented hemiarthroplasty leads to less residual pain and better return of mobility. Our results seem to suggest that cementing the stem of Austin Moore prosthesis gives a better function, lesser pain and improved gait function outcome by providing better primary anchorage of the prosthesis. This is especially important in the osteoporotic femur with weak calcar and wide medullary canal[44]. A good stable fit allows

early mobilization of patients. Considering the advantages of using cement for stem fixation in unipolar hemiarthroplasty and the safety of cementing in patients without severe cardiopulmonary compromise, it would be prudent to cement all Austin Moore hemiarthroplasties. Though it is against the common practice of inserting this prosthesis without cement, this might need a change, because it is now used in the frail elderly patients with limited demands and mobility. Due to the limited life expectancy of these patients, revision is not an issue. Lesser pain, better mobility and early mobilization are what are important and these goals are better achieved when the Austin Moore stem is cemented in place.

Radiological evaluation was done using pre operative and post operative radiographs. An overwhelming majority of our patients (72.7%) had a Dorr type C femur i.e. wide metaphysis with wide medullary canal, loss of isthmus construction and loss of cortical bone stock. 12 patients had femur with Dorr type B morphology (27.3%), i.e. a wide metaphysis with large medullary canal, but relatively good cortex. This is based on the study by Dorr et al in which the authors classified three types of morphologic anatomy of the proximal femur, referencing the selection of cemented versus non-cemented femoral arthroplasty components [8]. As noted by Kankanala et al[37], achieving a press fit in Dorr C type femora may be impossible and hence, they advocated cementation without pressurization in such patients. Sah et al have also shown the relation between Dorr femur morphology and osteoporosis[44]. This again justifies the need to cement the Moore's prosthesis to achieve a good primary anchorage in wide medullary canals.

The types of implantation errors in this study, as assessed by the methods described by Sharif and Parker[9] which included inadequate length of neck remnant (<12mm), inadequate calcar seating (>1 mm), difference in prosthetic head size compared to contra lateral head (up to 2 mm), intra operative periprosthetic fracture are summarized in Table 4. Our results compare favourably with those of Weinrauch P. where the author had studied intra-operative errors during Austin Moore hemiarthroplasty (uncemented) in 147 patients. In that study, there was inadequate length of neck remnant in 27% cases, inadequate calcar seating in 22% cases and intra operative periprosthetic fracture in 14% cases [45].

The relative fill of the stem of prosthesis in the medullary canal of femur at the level of tip of lesser trochanter on anteroposterior pelvis radiograph was <70% in 36 patients (81.8%) whereas only eight patients (18.2%) had more than 70% metaphyseal fit. At least 70% canal fill by the stem of the prosthesis at the level of lesser trochanter is necessary to avoid excessive subsidence of the prosthesis and pain according to Yau et al[10]. Rehmatullah et al[46] found an inverse relationship between prosthesis head size and metaphyseal fit. Austin Moore prosthesis with head size 42 mm had an average 84.5% fit whereas a 54 mm head had only 56% fit in their study. The authors advised cemented hemiarthroplasty in these cases

## VI. CONCLUSION

Hemiarthroplasty using cemented Austin Moore prosthesis for fractures of the femoral neck provides freedom from pain, better range of movement and more rapid return to unassisted activity with an acceptable complication rate. Though conventionally done in an uncemented fashion, providing a good primary anchorage, especially in the osteoporotic femur is of paramount importance. This can be done by cementing the prosthesis without any significant increase in cement related complications in properly selected patients. The end functional results also depend on the associated co-morbidity and optimum post-operative rehabilitation. The long term results using cemented Austin Moore prosthesis needs further study for a longer period in a larger sample with a direct comparison between the cemented versus uncemented groups. However, considering the good result achieved in the short term, it seems reasonable to use bone cement for all Austin Moore hemiarthroplasties.

## Acknowledgements

The management of Karnataka Institute of Medical Sciences Hospital, Hubli

## REFERENCES

- [1]. Schmidt AH, Swiontkowski MF. Femoral neck fractures. *Orthop Clin North Am* 2002; 33(1):97-111.
- [2]. Ioro R, Healy WL, Lemos DW, Appleby D, Lucchesi C, Saleh KJ, et al. Displaced femoral fractures in the elderly : outcomes and cost effectiveness. *Clin Orthop* 2001; 383: 229-242.
- [3]. Bhandari M, Devereaux PJ, Swiontkowski MF, Tornetta P, Obrebsky W, Koval KJ, et al. Internal fixation compared with arthroplasty for displaced fractures of the femoral neck. *J Bone Joint Surg Am* 2003; 85-A:1673-1681.
- [4]. Ioro R, Schwartz B, Macaulay W, Teeney SM, Healey WL, York S. Surgical treatment of displaced femoral neck fractures in the elderly: a survey of the American Association of Hip and Knee Surgeons. *J Arthroplasty* 2006; 21(8):1124-1133.
- [5]. Swiontkowski MF. Intracapsular fractures of the hip. *J Bone Joint Surg Am* 1994; 76-A:129-138
- [6]. Harris WH. Traumatic arthritis of the hip after dislocation and acetabular fractures: Treatment by mould arthroplasty. An end result study using a new method of result evaluation. *J Bone Joint Surg Am* 1969; 51-A:737-755
- [7]. Duncan CP, Masri BA. Fracture of the femur after hip replacement. *Inst Course Lect* 1995; 44: 293
- [8]. Dorr L, Faugere M, Mackel A et al. Structural and cellular assessment of bone quality of proximal femur. *Bone* 1993; 14: 231-42
- [9]. Sharif KM, Parker MJ. Austin Moore hemiarthroplasty: technical aspects and their effects on outcome in patients with fractures of the neck of femur. *Injury* 2002; 33: 419-22.

- [10]. Yau WP, Chiu KY. Critical radiological analysis after Austin Moore hemiarthroplasty. *Injury* 2004; 35: 1020-24.
- [11]. Salvati EA, Wilson PD. Long-term results of femoral-head replacements. *J Bone Joint Surg Am* 1972; 54-A:1355-1356.
- [12]. Steen Jensen J, Holstein P. A long term follow-up of Moore arthroplasty in femoral neck fractures. *Acta Orthop. Scand.* 1975; 46: 764-74
- [13]. Saxena PS, Saraf JK. Moore prosthesis in fracture neck femur. *Indian Journal of Ortho* 1978; 12(2): 138-46
- [14]. Jadhav AP, Kulkarni SS, Vaidya SV, Divekar MM, Suralkar SP. Results of Austin Moore replacement. *J Postgrad Med* 1996;42:33
- [15]. Kumar R, Singh T. Early results of prosthetic replacement in old neglected cases of fracture neck femur *Ind J Orthop* 1980; 14:1.
- [16]. Leighton RK. Fractures of the Neck of the Femur. Bucholz RW, Heckman JD, Court-Brown CM(Ed) In: *Rockwood and Green's fracture in Adults*. 6<sup>th</sup> edn. Philadelphia, Lippincott Williams & Wilkins 2006; 1753-1791
- [17]. Moore AT. The Self-Locking Metal Hip Prosthesis. *J Bone Joint Surg Am.* 1957;39-A:811-827
- [18]. Dinesh Dhar. Early Results of Austin Moore Prosthesis in Elderly Patients with fracture neck femur. *J.Orthopaedics* 2007;4(1)e3
- [19]. Noor SS, Hussain N, Javed I. Outcome of Austin Moore hemiarthroplasty in elderly patients with fracture neck of femur. *J of Pakistan Orthopaedic Association* 2012; 22(1): 14-19
- [20]. Sonne-Holm S, Walter S, Steen Johnson J. Moore hemiarthroplasty with and without bone cement in femoral neck fractures. *Acta Orthop Scand.* 1982; 53: 953-6
- [21]. Fauci, Braunwald, Kasper, Hauser, Longo, Jameson, Loscalzo (Editors) in *Harrison's Principles of Internal Medicine* 17<sup>th</sup> edition, McGraw Hill, Chapter 348; Osteoporosis.
- [22]. Seeman Ego. Pathogenesis of bone fragility in women and men. *The Lancet* 2002; 359: 1841-48.
- [23]. Seeman Ego. Periosteal bone formation- a neglected determinant of bone strength. *N Eng J Med* 2003; 349(4): 320-23.
- [24]. Evans CM. Endoprosthesis as primary treatment of femoral neck fracture. *Clin Orthop* 1973; 92: 69-76.
- [25]. Ingalhalkar VT, Shekar Kumta. Fracture neck femur anatomical and biomechanical aspects. *Clin Orthop* 1987; 98: 35-9.
- [26]. Koval KJ, Zuckerman JD. Current Concepts Review: Functional Recovery after Fracture of the Hip. *J Bone Joint Surg (Am)* 1994; 76-A: 751-766.
- [27]. Bath, R. Problems in the treatment of femoral neck fractures. *Proceedings of the Royal Society of Medicine* 1975; 63:1120-1128.
- [28]. Bush JB, Wilson MR. Dislocation after hip hemiarthroplasty: anterior posterior capsular approach. *Orthopaedics.* 2007; 30(2): 138-144
- [29]. Weinrauch P, Moore W, Shooter D, Wilkenson M, Bonarth E, et al. Early prosthetic complications after uncemented Austin Moore and cemented Thompson hemiarthroplasty. A multicenter review of 1118 patients. *ANZ J Surg.* 2006;76(6):432-
- [30]. Parker MJ, Pryor G, Gurusamy K. Cemented versus uncemented hemiarthroplasty for intracapsular hip fractures- a randomized controlled trial in 400 patients. *J Bone Joint Surg (Br)* 2010; 92-B: 116-22.
- [31]. Figved W, Opland V, Frihagen F, et al. Cemented versus uncemented hemiarthroplasty for displaced femoral neck fractures. *Clin Orthop Relat Res* 2009; 467: 2426-35.
- [32]. Fraser T, Wright M, Zhu M. Hemiarthroplasty of the hip with and without cement: a randomized controlled trial. *J Bone Joint Surg(Am)* 2012; 94-A: 577-83.
- [33]. Emery RJH, Broughton NS, Desai K, Bulstrode CJK, Thomas TL. Bipolar hemiarthroplasty for subcapital fracture of femoral neck. *J Bone Joint Surg (Br)* 1991; 73-B: 322-4
- [34]. D'Arcy J, Devas M. Treatment of fractures of the femoral neck by replacement with the Thompson prosthesis. *J Bone Joint Surg* 1976;58-B:279-286.
- [35]. Christie J, Burnett R, Potts HR, Pell HC. Echocardiography of transarterial embolism during cemented and uncemented hemiarthroplasty of the hip. *J Bone Joint Surg (Br)* 1994; 76-B: 409-12.
- [36]. Clark DI, Ahmed AB, Baxendale BR, Moran CG. Cardiac output during hemiarthroplasty of the hip. A prospective, controlled trial of cemented and uncemented prostheses. *J Bone Joint Surg(Br)* 2001; 83-B: 414-8.
- [37]. Kankanala G., Gubbi SD, Prasad Pidikiti. A comparative study of postoperative morbidity and mortality in femoral neck fractures in elderly patients treated with cemented and uncemented Thompson hemiarthroplasty. *J of Orthopaedics, Trauma and Rehabilitation* 2011; 15; 47-50.
- [38]. Costa ML, Griffin XL, Pendleton N, Pearson M, Parsons N. Does cementing the femoral component increase the risk of peri-operative mortality for patients having replacement surgery for a fracture of the neck of femur? *J Bone Joint Surg(Br)* 2011; 93-B: 1405-10.
- [39]. Donaldson AJ, Thomson HE, Harper NJ, Kenny NW. Bone cement implantation syndrome. *Br J Anaes* 2009; 102(1): 12-22.
- [40]. Anderson GH, Dias JJ, Hoskinson J, Harper WM. A randomized study of the use of bone cement with Thompson prosthesis in the treatment of intracapsular fractures of the femoral neck. *J Bone Joint Surg* 1992(Br); 74B [Suppl 2]; 132-33
- [41]. Faraj AA, Branfoot T. Cemented versus uncemented Thompson's prosthesis: a functional outcome study. *Injury* 1992; 30(10): 671-5
- [42]. Singh GK, Deshmukh RG. Uncemented Austin Moore and cemented Thompson unipolar hemiarthroplasty for displaced fracture of neck of femur- comparison of complications and patient satisfaction. *Injury* 2006; 37(2): 169-74.
- [43]. Lausten GS, Vedel P. The monk hard-top endoprosthesis for intracapsular fractures of the femoral neck. *Injury* 1982; 13: 233-38.
- [44]. Alexander P.Sah, Thomas S. Thornhill, Meryl S. LeBoff, Julie Glowackie. *Osteoporos Int.* 2007 August ; 18(8): 1119-1126
- [45]. Weinrauch P. Intra-operative error during Austin Moore hemiarthroplasty. *J of Orthop Surg* 2006; 14(3): 249-52.
- [46]. Rehmatullah NT, MacDonald A, Ingham C, Davis BJ. The relationship of head size versus metaphyseal fit with the Austin Moore hemiarthroplasty. *Eur Orthop Trauma* 2010; 1(1): 17-19.