

## Orthodontics Implants in Orthodontics- A New Paradigm

Dr. Bhumika.Ramchandra.Mute<sup>1</sup>, Dr. Kalpak. Prafulla. Peter<sup>2</sup>,  
Dr. Suchita Daokar<sup>3</sup>.

M.D.S, Assistant Professor<sup>1</sup>, R.K.D.F Dental College, Bhopal, India.

M.D.S, Assistant Professor<sup>2</sup>, R.K.D.F Dental College, Bhopal, India.

M.D.S, Professor<sup>3</sup>, C.S.M.S.S Dental College, Aurangabad, India.

---

**Abstract:** Conservation of anchorage in totality has been perennial problem to traditional orthodontist. Traditionally, orthodontists have used teeth, intraoral appliances, and extraoral appliances, to control anchorage minimizing the movement of certain teeth, while completing the desired movement of other teeth. However, according to Newton's third law of motion, for every action there is an equal and opposite reaction. Thus, there are limitations in our ability to completely control all aspects of tooth movement. For example, we often have inadequate mechanical systems to control anchorage, which leads to anchorage loss of reactive units and often incomplete correction of intra- and interarch alignment problems. For long time, orthodontist have struggled to achieve efficient control of anchorage and always dreamt of a device, which could provide absolute anchorage. This dream came true with the advent of implant. Implant has burst onto the clinical orthodontic scene in order to assist the orthodontist in controlling tooth movement. Orthodontic implants or temporary anchorage device (TAD) are temporarily fixed to bone for the purpose of enhancing orthodontic anchorage either by supporting the teeth of the reactive unit or by obviating the need for the reactive unit altogether, and which is subsequently removed after use. This article has systemized the information about types of implants and their advantages in respect of traditional treatments for all the readers.

---

### I. Introduction

"Give me a lever long enough, a place to stand & I shall lift the earth!" so said **Archimedes!** "A place to stand" is what anchorage is. Anchorage in orthodontics refers to the resistance which the Dentofacial structures offer to change in form or position under applied force- L.B.Highly<sup>1</sup>. Conservation of anchorage in totality has been perennial problem to traditional orthodontist. Traditionally, orthodontists have used intraoral appliances, and extraoral appliances, to control anchorage while completing the desired movement of other teeth with these advantages and disadvantages.

For long time, orthodontist have struggled to achieve efficient control of anchorage & always dreamt of a device which can provide absolute anchorage. This dream have come true with the advent of implant, implant has burst onto the clinical orthodontic scene in order to assist the orthodontist in controlling tooth movement. New era dawned in 'Anchorage paradigms' with wider application of implants in orthodontics. The incorporation of implants in orthodontic treatment made infinite anchorage possible, which has been defined in terms of implants as showing no movement zero anchorage loss as a consequence of reaction of forces. The primary advantage over the previously mentioned forms of anchorage is that implants provide skeletal anchorage, which is undoubtedly more predictable and stable than methods requiring patient compliance.

### II. Review of literature:-

Clinicians and researchers have tried to use implant as orthodontic anchorage units for over a half century. In 1945, Gainsforth and Higley<sup>4</sup> used implants to attain orthodontic anchorage. They placed vitallium screws and wires in the dog ramus (Fig. 1), and applied elastics that extended from the screw to the hook of the maxillary archwire for distalization. All screws failed within 16 to 31 days. In 1964, Branemark<sup>3</sup> and coworkers reported on the use of titanium optical chambers implanted into the femurs of rabbits. It was in 1969, when Branemark<sup>6,7</sup> & colleagues introduced the concept of osseointegration in dentistry, using pure titanium implants. There were no more published reports of attempts to use endosseous implants to move teeth until the clinical case reports of Linkow (1969; Fig. 2)<sup>8</sup> which were successful. He used mandibular blade-vent implants in a patient to apply Class II elastics for retraction of maxillary incisors.

Over years a variety of terms have been used to describe the orthodontic implant, such as miniscrews, mini-implant, microimplant & microscrew implant. Temporary anchorage device (TAD) is also widely used 'Miniscrew implant as TAD' seems to be the most unambiguous term. A temporary anchorage device (TAD) is a device that is temporarily fixed to bone for the purpose of enhancing orthodontic anchorage either by supporting the teeth of the reactive unit or by obviating the need for the reactive unit altogether, and which is subsequently

removed after use. Anchorage thus derived from implant, has been termed as indirect Anchorage by Roberts. Other authors have stated the anchorage potential of implants while affecting the tooth movement as an example of "true stationary anchorage", "Absolute anchorage and so on.

Implant has opened a new horizon to orthodontic treatment. They may increase the treatment possibility for patients and improve functional results of the treatment.

### IMPLANT STRUCTURE

The commonly used implant screw/plate has two parts:-

a) **Implant head**, which serves as the abutment and in the case of an Orthodontic implant, could be the source of attachment for elastics/ coil-springs

b) **Implant body**, which is the part embedded inside bone. This may be a screw type or a Plate type -which is flatter and can be used in resorbed and knife edged ridges.

### IMPLANT -CRITERIA

**Implant sizes.** Implant fixtures must achieve primary stability and withstand mechanical forces. The maximum load is proportional to the total bone-implant contact surface. Factors that determine the contact area are length, diameter, shape, and surface design (rough vs. smooth surface, thread configuration). The ideal fixture size for orthodontic anchorage remains to be determined. Various sizes of implants, from "miniimplants"(6 mm long, 1.2 mm in diameter) to standard dental implants (6-15 mm long, 3-5 mm in diameter), have proved to effectively improve anchorage. Therefore, the dimension of implants should be congruent with the bone available at the surgical site and the treatment plan.

**Implant shape.** This determines the bone-implant contact area available for stress transfer and initial stability. The design must limit surgical trauma and allow good primary stability. It is difficult to identify the "perfect" implant shape. The most commonly used is cylindrical or cylindrical-conical, with a smooth or threaded surface. Studies have shown that the degree of surface roughness is related to the degree of osseointegration. Most implants used for orthodontic anchorage are similar to conventional designs.

**Safety distance.** An excellent review and an update of the current concepts in the use of dental implants for orthodontic anchorage have been provided<sup>11</sup>. The concept of a safety distance provides a guideline for **minimum distance between the roots where implant placement is planned**

Mathematically, safety distance was given as

$$\text{Safety Distance} = \text{Diameter of the implant} + \text{PDL space} \quad (\text{normal range: } 0.25 \text{ mm} \_ 50\%) \\ + (\text{minimum distance between implant and tooth, i.e. } 1.5 \text{ mm}) \times 2 \\ \text{OR } 1.2 + (.375) + (1.5) \times 2 = 4.575 \text{ mm}$$

However, clarification was needed regarding the calculation of the safety distance.

Which was given by various authors who suggested that the PDL space should be multiplied by a factor of 2 to consider PDL space of 2 teeth<sup>12</sup>, i.e. the teeth on either side of the implant

hence: *the formula computed was*

$$\text{Safety Distance} = \text{Diameter of the implant} + 2 \times \text{PDL space} \quad (\text{normal range: } 0.25 \text{ mm} \_ 50\%) + (\text{minimum} \\ \text{distance between implant and tooth i.e. } 1.5 \text{ mm}) \times 2 \\ \text{OR } 1.2 + 2 \times (.375) + (1.5) \times 2 = 4.95 \text{ mm}$$

### CLASSIFICATION OF IMPLANTS

Implants can be classified under the following headings<sup>13</sup>:

#### Based on the location

**Subperiosteal** - Implant body lies over the bony ridge

**Transosseous**-implant body penetrates the mandible completely

**Endosseous**- partially submerged and anchored within the bone-endosseous implants are most commonly used for orthodontic purposes.

#### Based on the configuration design.

**Root form implants:** These are the screw type endosseous implants and the name has been derived due to their cylindrical structure

**Blade / Plate implants:** Flatter & can be used in resorbed & knife edged ridges.

#### According to the composition

Stainless steel

Cobalt-Chromium-Molybdenum (**Co-Cr-Mo**)

- Titanium
- Ceramic Implants
- Miscellaneous such as Vitreous carbon and composites

**According to the surface structure.**

**Threaded or Non-threaded**

The root form implants are generally threaded as this provides for a greater surface **area and** stability of the implant.

**Porous or Non Porous**

The screw type implants are usually non porous, whereas the plate or blade implants (non Threaded) have vents in the implant body to aid in growth of bone and thus a better Interlocking between the metal structure and the surrounding bone.

further implants can be classified<sup>14</sup>

I) Based on the implant morphology:

**a) Implant discs**

1. Onplant

**b) Screw designs -**

1. Mini-Implant
2. Ortho system implant system
3. Aarhus implant
4. Micro-implant
5. Newer systems such as the Spider Screw, the OMAS system, the Leone

miniimplant, the Imtec screw etc.

**c) Plate designs -**

1. Skeletal Anchorage system (SAS)
2. Graz implant supported system
3. Zygoma anchorage system

II ) They can also be classified depending on the area of placement as:

1. Subperiosteal Implants
2. Osseous implants and
3. Inter-dental implants

**INDICATIONS AND CONTRAINDICATIONS OF IMPLANTS**

Indications and advantages of using dental implants for orthodontic anchorage<sup>15</sup>.

| INDICATIONS                       | ADVANTAGES  |
|-----------------------------------|---|
| <b>INTRUDE/EXTRUDE TEETH</b>      | -Mini-implants more feasible than conventional ones   |
| <b>CLOSE EDENTULOUS SPACES</b>    | -Avoid need for prosthesis -Reduce endodontic complications   |
| <b>REPOSITION MALPOSED TOOTH</b>  | -Enhance oral hygiene<br>-Improve anchorage<br>-Reconstruct the edentulous area                     |
| <b>REINFORCE ANCHORAGE</b>        | Maximize anchorage, eg, palatal implant Improve patient compliance (no headgear, Class II elastics) |
| <b>PARTIAL EDENTULISM</b>         | Future restorative abutments<br>Reduce dental complications   |
| <b>CORRECT UNDESIRE OCCLUSION</b> | Provide solid anchorage to retract entire arch<br>Facilitate localized bonding and treatment        |
| <b>ORTHOPEDIC MOVEMENT</b>        | Accelerate sutural distraction(palatal expansion) and bone movement                                 |

**III. Contraindication for implant therapy**

**Absolute contraindication**

1. Severe systemic disorder eg osteoporosis
2. Psychiatric diseases eg psychoses dysmorphobia
3. Alcoholics drug abusers

**Relative contraindications**

1. Insufficient volume of bone
2. Poor bone quality
3. Patients undergoing radiation therapy
4. Insulin dependent diabetes

5. Heavy smokers

**TREATMENT CONSIDERATIONS**

**Age of the patient**

The age of the patients is an important consideration as implant is problematic if inserted in growing children for the following reasons

1. The use of implant in the anterior maxilla is contraindicated due to the possibility of the mid palatal suture being open
2. Resorption in the posterior part of the maxilla resulting from growth changes could lead to the exposure of the implant into the sinus
3. The posterior aspect of the mandible continues to undergo growth changes in all the plane of spaces and as such definitive implant placement in this area would be difficult to estimate

**Teeth- Number & Existing Conditions**

Proper assessment of Size, shape, root angulations & diameter of existing dentition should be taken in consideration. Proximity between implant and natural teeth should be more than 1.5 mm.

**Bone support-**

Thick compact cortical bone with core of dens trabacular cancellous bone and should have 6mm buccal & lingual width with sufficient tissue volume. Soft tissue heights of <2mm or > 4mm may present a challenge

**Oral hygiene**

Important pre and post implant placement

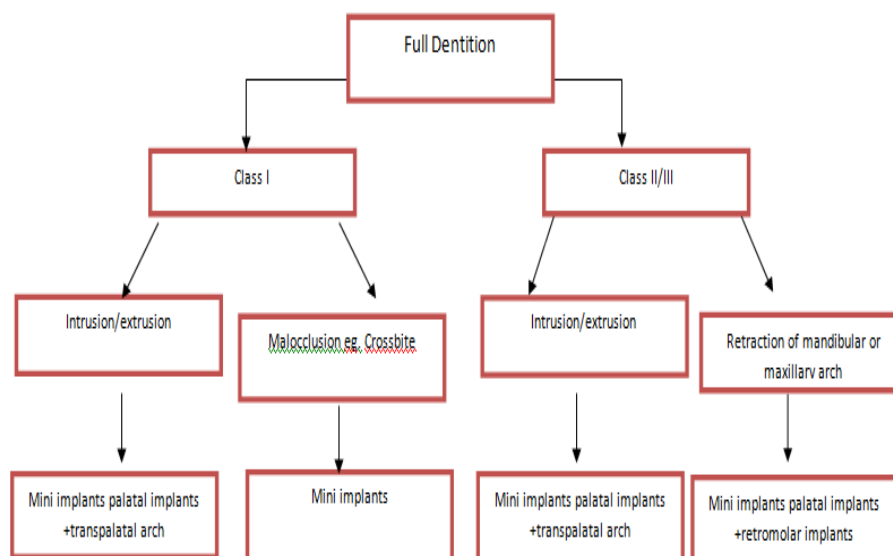
**Systemic manifestations**

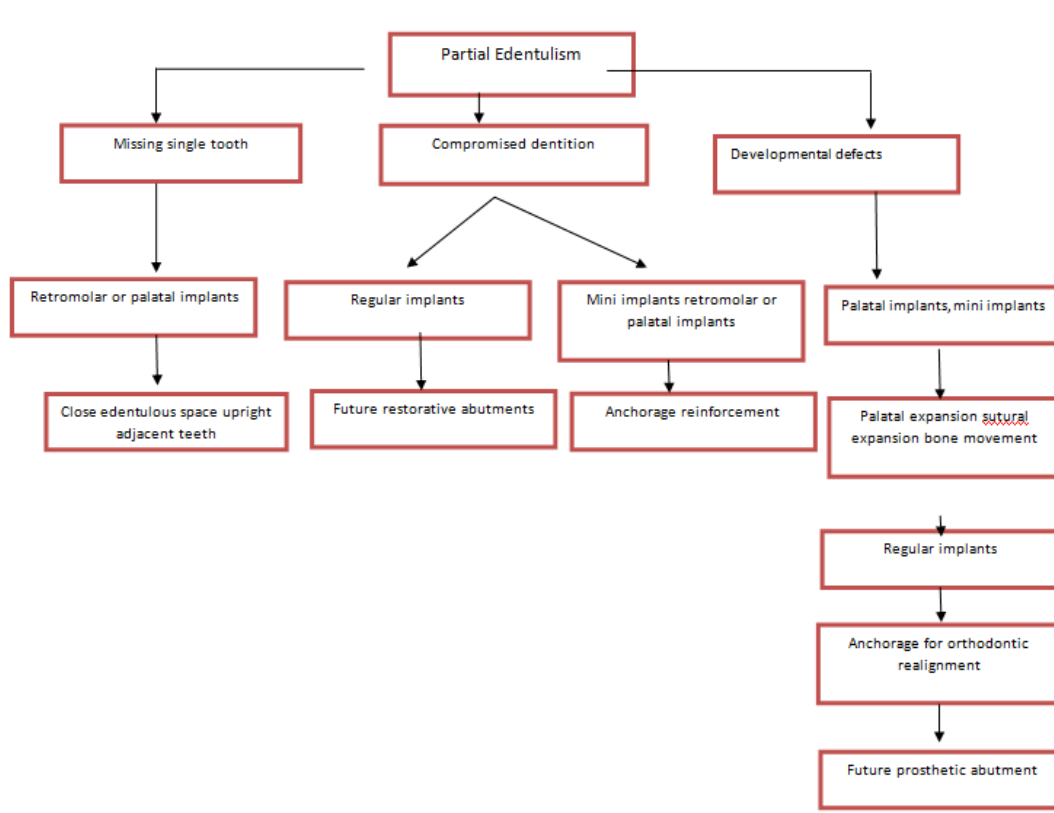
1. Diabetics are predisposed to delayed healing
2. Destructive habits - smoking is contraindicated to placement of implant as delayed or inadequate tissue healing and osseointegration is noted

**Radiographic analysis**

The region should be properly monitored for adequate interradicular area, Bone quality and quantity or any periapical pathology. Any Radioopaque/radiolucent regions above the inferior alveolar region or below the maxillary sinus should be noted. Implant should be placed at a minimum of 2mm from the inferior alveolar canal or below the maxillary sinus

**Decision making in orthodontic treatment planning. A, For patients with full dentitions; B, for partially edentulous patients.**





### IMPLANT SITE SELECTION

Selecting the proper implant site can be an important factor in the overall success of this treatment approach.

Important factors in determining an adequate site for implantation<sup>16</sup>.

1. Indication, system used, and required mechanics:- When placing an orthodontic mini-implant, the treatment objective and how long the implant will remain in situ are of paramount importance. Mechanics should be as simple and fail-safe as possible, but the future tooth movement must be anticipated to avoid any interference with the implant.
2. Placement in attached gingiva, clear of the frenum:- The implant site should ideally provide sufficient attached gingiva for placement of the implant. This prevents patient discomfort, tissue overgrowth, and micro jiggling that can lead to long-term implant failure.
3. Sufficient interradicular distance:- The implant must be placed where roots are wide enough apart so that no damage is inflicted. Periapical radiographs or 3-dimensional cone-beam computed tomography is essential tools for evaluating potential implant sites. If the preferred implant site is obstructed by root proximity, some preparatory root uprighting might be necessary.
4. Avoiding other anatomical structures:- Other anatomical structures can interfere with the placement of an orthodontic mini-implant: eg, inferior alveolar nerve, artery, vein, mental foramen, maxillary sinus, and nasal cavity. Again, 3-dimensional digital imaging can help evaluate the anatomical relationships such as adequate cortical bone thickness. Cortical bone thickness is an important factor in mini-implant stability. Placing the implant in areas of favorable bone thickness ensures better primary stability and long-term success.

### Various clinical sites for implant placement.

#### Maxilla

- Infrazygomatic crest area
- Tuberosity area
- Between 1<sup>st</sup> and 2<sup>nd</sup> molars buccally
- Between 1<sup>st</sup> molar and 2<sup>nd</sup> premolar buccally
- Between canine and premolar buccally
- Between incisors facially
- Midpalatal area

#### Mandible

- Retromolar area

- Between 1<sup>st</sup> and 2<sup>nd</sup> molars buccally
- Between 1<sup>st</sup> molar and 2<sup>nd</sup> premolar buccally
- Between canine and premolar buccally
- Symphysis facially
- Edentulous area
- Mandibular tori

### **Post-operative Patient Management**

Patients should be given standard surgical postoperative instructions emphasizing the importance of inflammation control and cautioned not to brush or touch the implant for a week. Ibuprofen or its equivalent is usually adequate for discomfort, and antibiotics are rarely necessary. A chlorhexidine rinse is usually prescribed for 7 to 14 days, but no other post-surgical care is required. Patients with miniscrew implants should return to the orthodontic office as soon as possible for loading, preferably within 1 week. In theory, the vector of force to stabilize mini-implants is critical to counter tissue, tongue, and masticatory forces. Integration is not expected; therefore, mechanical stabilization is crucial. Patients receiving palatal implants may be scheduled in the periodontal office monthly until osseointegration is complete to monitor mobility and possible inflammation. Unless periodontal therapy is part of the treatment plan, patients are then seen in the orthodontic office until the desired tooth movement is achieved and implants are ready for removal<sup>7,6</sup>.

### **THE HEALING PERIOD**

Placement must be aseptic, atraumatic, and precise to ensure success. After the implant has been inserted, a 13-week healing period is necessary. To prevent infection, antibiotic therapy and dental hygiene instruction are suggested; the construction of a protective acrylic splint is planned during the same surgical insertion, which prevents undesirable load of the tongue on implant<sup>18</sup> Postoperative patient, visits are scheduled at 7 to 10 days and 10 weeks after insertion date stable mechanical retention or partial osseointegration is required, and implants should not be overloaded during healing. The loading regimen should be evaluated individually.

### **IV. Summary & Conclusion**

The success of implants being used as anchors has widened the horizons of the orthodontists which should be explored to the best possible advantage for treating cases. This could help in providing the aesthetically conscious adult patient orthodontic care which was once compromised or denied altogether due to lack of posterior teeth which serve as anchors during orthodontic treatment. Achieving absolute anchorage has been one of the dreams of the practicing orthodontists, and microimplants have become one of the most effective and powerful tools for achieving absolute anchorage. This new treatment approach is causing a paradigm shift in orthodontic treatment planning. The ability to replace a failed implant instantaneously results in almost 99% success rate, regardless of whether or not the implant fails or remains stable.

Today we find ourselves at the clinical stage of development, which calls for further systematic and prospective research. But still today the advent and success of implants has elevated the very practice of dentistry to new levels. Our patients are better served, and we can offer treatments in situations that were largely unmanageable not very long ago.

"If one considers that this technology is still in its infancy, it becomes apparent that the future will bring many exciting and innovative developments in this area".

### **Bibliography -**

- [1]. L.B.Higley Anchorage in orthodontics. AJO-DO on CD ROM Vol 1996 June
- [2]. Samuels RH ,Willams F,Knox J, Jones ML. A national survey of orthodontic face-bow injuries in UK and Eire. Br. Dental J 1996;23:11 -20
- [3]. Booth- Mason S, Birnie D.Penetrating eye injury from orthodontic headgears- a case report Eup JOrthod 1988;10(2):111-14
- [4]. Gainsforth BL, Higley LB: A study of orthodontic anchorage possibility in basal bone, Am J Orthod 1945;31:406-417.
- [5]. Branemark P.L,Aspergren K, Breine U:Microcirculatory studies in man by high resolution vital microscopy.Angiology 1964, 15:329-332,1964.
- [6]. Adell R,Rockler B, Branemark PL A 15 year old study of osseointegrated implant in treatment of edentulous jaws.Int. J.Oral Surg; 1981;10:387-416
- [7]. Hassen HR,Albrektsson T, Branemark PL Structural aspects of interface between bone and titanium implants. J Prosthetic dentistry 1983; 50: 108-113
- [8]. Linkow L.I :The endosseous blade implant and its use in orthodontics.Int J.Orthod,1969,18:149-154 ,
- [9]. Chetan V Jayade ,V.P.Jayade implants as absolute orthodontic anchors part 1 JIOS 2003;36:214-219
- [10]. Lien-Hui Huang, a Jeffrey Lynn Shotwell, b and Horn-Lay Wang c,, Dental implants for orthodontic anchorage (Am J Orthod Dentofacial Orthod 2005;127:713-22)
- [11]. Dental Implants for Orthodontic Anchorage' (Huang L-H, Shotwell JL, and Wang H-L. Am J Orthod Dentofacial Orthop 2005; 127:713-22).

- [12]. *Dr Pawan Gautam Prof. Ashima Valiaithan Manipal Indiathey*
- [13]. Mr. Chetan.V Jayade & V.P.Jayde in 2003 in their articles implants as absolute orthodontic anchors' part1
- [14]. Chetan v. Jayade, V.P.Jayade .Implants as absolute orthodontic anchors part II —jios 2003;37: 48-53
- [15]. Lien-Hui Huang, a Jeffrey Lynn Shotwell, b and Hom-Lay Wang c, Dental implants for orthodontic anchorage (Am J Orthod Dentofacial Orthod 2005;127:713-22)
- [16]. 16.Sebastian Baumgaertel,a Mohammad R. Razavi,b and Mark G. Hansc Mini-implant anchorage for the orthodontic practitioner (Am J Orthod Dentofacial Orthop 2008; 133:621-
- [17]. Aldo giancotti, Fabiana Muzzi, Francesca Santini, Calaudio Arcuri Straumann orthosystem method for orthodontic anchorage. Step by step procedure World J Orthod 2002;3: 140-146