

## Rehabilitation of Ocular Defect with Orbital Prosthesis: A Case Report

Dr Hemchand.Surapaneni<sup>1</sup>, Dr V.H.Chalapathi Kumar<sup>2</sup>, Dr Vinamra Dhariwal<sup>3</sup>,  
Dr Ranjith Kumar<sup>4</sup>.

1. Reader, Department of Prosthodontics, Drs.Sudha &Nageswara Rao Siddhartha Institute of dental sciences,  
Dr. N.T.R University, India.

2. Reader, Department of Prosthodontics, Narayana dental college, Nellore.

3.Reader, Adarsh dental clinic, Chennai.

4.Reader, Department of Prosthodontics,S.R.M dentalcollege, Chennai.

---

**Abstract:** Eye defects constitute a major portion of maxillofacial defects. An attempt has been made to rehabilitate the lost eye with a great challenge by the skills and materials available. A custom made orbital prosthesis using silicon to replace soft tissue, acrylic for sclera and papillary part and adhesive for retention is good alternative.

**Key-words:** Eye Prosthesis, Silicon Elastomers, Moulage

**Key Messages:** Lost eyes have been replaced with prosthesis for many years in the form of stock or custom ocular prosthesis. Great evolution in field of maxillofacial material has made it possible to nearly duplicate patient's features in prosthesis.

---

### I. Introduction

Successful rehabilitation of facial defects allows to promote physical and psychological healing for the patient and to improve social acceptance. As the conversation often starts with an eye contact, the prosthesis replacing eye defects certainly deserve special importance. The lost orbital volume can be replaced by integrated or non-integrated orbital implants.[1, 2,3] Although implant supported orbital prosthesis has a superior outcome, because these prostheses are more hygienic, comfortable, and satisfactory than prosthesis retained with adhesives, conventionally retained orbital prosthesis are practical, trouble-free, cost effective and successful. A multidisciplinary management and team approach are essential in providing accurate and effective rehabilitation and follow up care for the patient. [4, 5, 6] A sincere attempt has been done in rehabilitating a patient with an orbital defect. This article describes a simplified method for the fabrication of a silicone orbital prosthesis.

### II. Case History

A 65 years old female patient with an orbital defect on left side reported to the Department of prosthodontics (Fig-1A). Detailed history revealed that patient has congenital missing of her left eye. Because of long lasting defect there was a change in socket size, the shape of conjunctival fornices were diminished and due to contracture of eyelids, a simple acrylic eyeball was not inserting under the remaining eyelids. The primary reason for a extra-orbital prosthesis in this case is the long standing history leading to the profile deficit. Patient was made aware of materials like silicon which mimic skin texture, and helps in restoring the missing eye with orbital prosthesis as it is important to enhance the quality of life in an ageing patient.

### III. Review Of Literature

Tylman introduced the use of a resilient vinyl copolymer acrylic resin for facial prosthesis. A wide variety of coloring materials were also described. The introduction of various kinds of elastomers resulted in major changes in the fabrication of facial prosthesis. Silicone elastomers have gained popularity among clinicians. [7]

Barnhart (1960-1970) was the first to use silicone rubber for constructing and coloring facial prosthesis by combining a silicone rubber base material with acrylic resin polymer stains. [8]

Tashma used dry earth pigments dispersed in colorless acrylic resin polymer powder for intrinsic coloring of silicone facial prosthesis. [8]

Advances in polymer chemistry have renewed interest in developing new materials for facial prosthesis. new generation of acrylic resin is being investigated by Antonucci and Stansbury. [9]

Mark S Chambers has described a method for indexing ocular portion of an orbital prosthesis. [10]

#### **IV. Steps In Fabrication of Prosthesis.**

Preoperative consultation is valuable for informing the patient of the nature of the defect and the choices available for the restoration. After evaluation and inspection of the anophthalmic socket and defect region, the diameter of the iris and pupil on the intact side was measured using a pair of Boley Gauge callipers.

##### **1.1 Facial moulage & Cast Preparation**

This was done to obtain a working cast to orient the prosthesis properly to the rest of the face. The patient was in between upright and supine position (prop up position), completely relaxed. The eyebrow and eyelashes were lightly lubricated. Then an impression was made with irreversible hydrocolloid (Tropicalgin, Zhermack). A direct impression was prepared according to Mathew's classification. [11] The area to be covered was boxed with a ring of boxing wax. Tubes were placed in nostrils for breathing without disturbing them.

Alginate was mixed and applied to skin surface with round end mixing spatula taking care to avoid air entrapment. Gauze squares were applied all over the alginate surface. This provided mechanical retention for rigid plaster backing. Fast setting plaster was then spread over the entire surface to a thickness of about 0.25 inch. This provided adequate strength to support alginate. After the setting of plaster, set impression was removed, grasping it on the sides and lifting it gently. The impression was inspected for any voids or distortion.

The impression was poured in dental stone, (Goldstone, India) (Fig-1B) first coating the impression with only 0.25 inch of layer then developing remaining thickness. If entire impression is poured at once, the weight of stone may distort the impression.

##### **1.2 Formation of the prosthesis pattern**

A prefabricated iris button matching the papillary and corneal portion of contra lateral eye was selected. Painting the iris disk involves both artistic skills and the science of color. The painted iris disk was checked for color accuracy against the natural eye by placing a drop of water on the painted surface during construction. This was fixed on the wax adapted to the orbital cavity and was centered for correct gaze. Midline was marked and a scale drawn at the upper border. Now the various convexities and concavities were noted down with the help of ruler in all three dimensions. The eye-shell was fabricated with heat-cured acrylic resin and again centralization for correct gaze was done (Fig.-1C). The assembly was placed in the orbital defect and manipulated into the position corresponding to the normal eye gaze. The eyelid aperture was established by softening and placing two small strips of wax over the ocular section for primary evaluation. The pattern stimulating the eyelids and adjacent tissue was carved out in the routine base plate wax. This was done in the presence of patient.

The try in of the waxed-up prosthesis was done (Fig-2A) orientation of pupil; minute tissue details and its continuation at the margins of the prosthesis were checked. After sculpturing the prosthesis pattern, the final surface contour and skin texture were established by carving in lines and wrinkles found around the normal eye. Pressing a wet piece of gauze square into softened wax will produce a texture similar to normal skin.

##### **1.3 Flasking and De-waxing & Packing**

The wax pattern was flasked; the portion of the cast covered with the waxed-up prosthesis with a margin of 2cm was duplicated and the sectional cast was used for flasking. The cold cure acrylic extension (Fig-2B) was used to stabilize the eye-shell section. Flasking and dewaxing was carried out routinely (Fig- 2C).

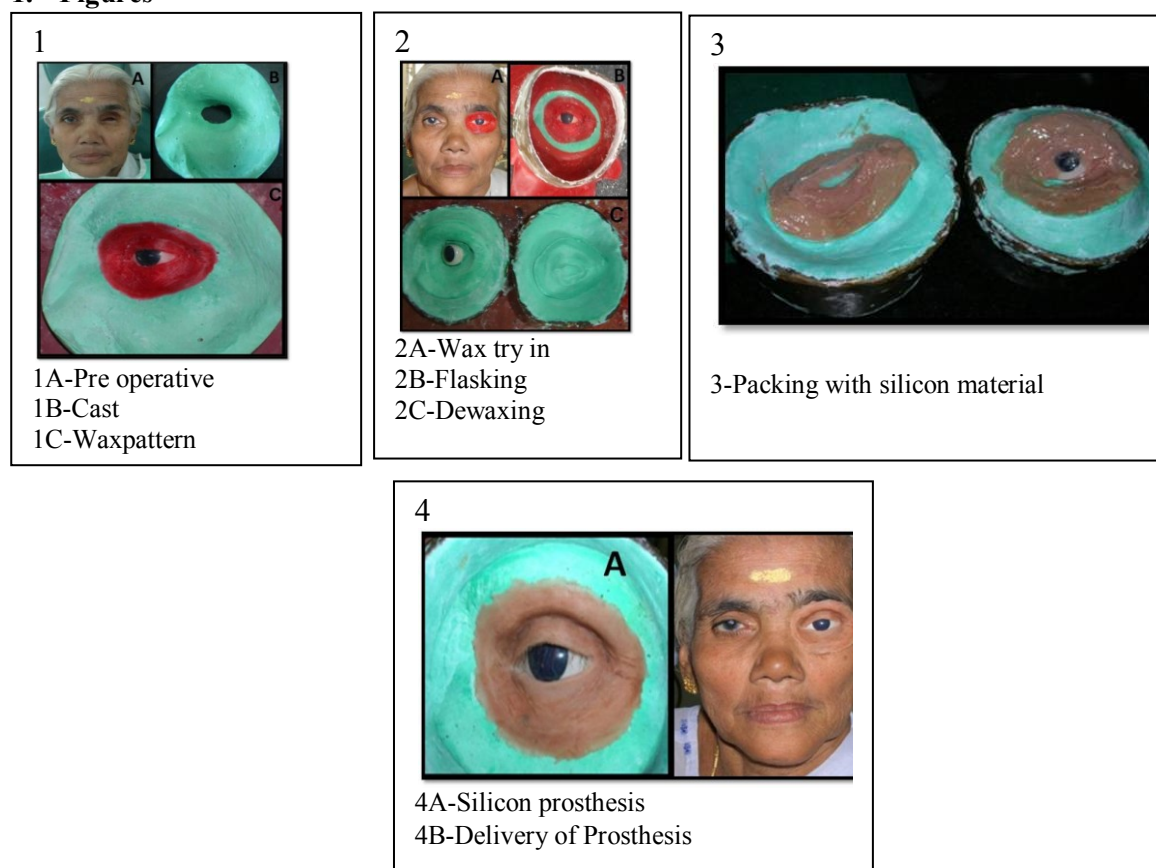
Room temperature vulcanization silicon (silastic 399) was used with a curing time of 4 hours. Stains were mixed in predetermined sequence and quantity to achieve intrinsic staining for better life of the prosthesis and to create life like appearance.

The bench press was used for 4 hours. Mould was not coated with any separating medium which enable a matte finish (Fig-3) for a more natural look. The prosthesis was carefully recovered from the mould and seated on the cast for the adaptation. When it was found satisfactory the extrinsic coloration of the prosthesis was carried out. A painting brush was used as a source of eyelashes, which were fixed with the help of an adhesive.

##### **1.4 Delivery of Orbital prosthesis :( Fig-4A)**

Skin adhesive for silicon was used as a mean of fixation (Fig-4B). Along with that a remover and skin preparation solutions were also prescribed. The patient was advised to avoid the sole eye movement and was advised to move the head as the prosthesis is centralized in the front gaze. Patient was instructed to remove the prosthesis during taking bath or face wash.

## 1. Figures



## V. Discussion

Lost eyes have been replaced with prosthesis for many years in the form of stock or custom ocular prosthesis. Great evolution in field of maxillofacial material has made it possible to nearly duplicate patient's features in prosthesis. The extent to which the patient is benefited depends upon the extent of loss and certain patients would be helped out more easily. Often however, a custom made ocular prosthesis which provides a more precise and satisfactory esthetic appearance is indicated especially for those who have lost ocular structures. Although implant-retained ocular prosthesis play an important role in the success of treatment, conventionally retained orbital prosthesis are practical, trouble-free, cost-effective and successful<sup>1</sup>. But nature is the ultimate creator and nobody can supersede him.

## References:

- [1]. Anderson RL, Thiese SM, Nerad JA, Jordan DR, Tse D, Allen L. The universal orbital implant: indications and methods. *Adv Ophthalmic Plast Reconstr Surg.* 1990; 8:88-99.
- [2]. Shome D, Honavar SG, Raizada k, Raizada D. Implant and prosthesis movement after enucleation: a randomized controlled trial. *Ophthalmology.* 2010; 117(8):1638-44.
- [3]. Branemark P.I. Osseointegration and its experimental background. *J Prosthet Dent.* 1983; 50:399-410.
- [4]. Supriya M, Ghadiali B. Prosthetic rehabilitation of a patient with an orbital defect using a simplified approach. *J Indian Prosthodont Soc.* 2008; 8:116-8.
- [5]. Patil SB, Meshramkar R, Naveen BH, Patil NP. Ocular Prosthesis: a brief review and fabrication of an ocular prosthesis for a geriatric patient. *Gerodontology.* 2008; 25(1):57-62.
- [6]. Guttal SS, Patil NP, Nadiger RK, Basutkar B. Use of acrylic resin base as an aid in retaining silicon orbital prosthesis. *J Indian Prosthodont Soc.* 2008; 8: 112-5.
- [7]. V. A. Chalian, R. W Phillips. Maxillofacial prosthetic material. *J Biomed Mat.* Sep 2004; 8(4):349-363.
- [8]. V. A. Chalian, J. B Drane. Maxillofacial Prosthetics – multidisciplinary practice. The William and Wilkins. Co 1972.
- [9]. J.W Stansbury, J.M Antonucci. *Dental Materials.* 1999; 15: 166-173.
- [10]. Mark S. Chambers, James C. Lemon, Jack W. Martin. Anterior key method for indexing orbital prosthesis. *J Prosthet Dent.* 2002; 87: 102-5.
- [11]. Hanasono MM, Lee JC, Yang JS, Skoracki RJ, Reece GP, Esmali B.. An Algorithmic Approach to Reconstructive surgery and Prosthetic Rehabilitation and Orbital Exenteration. *Plast Reconstr Surg.* 2009; 123:98-105.